

Fundus changes in pregnancy induced hypertension

Dr. Bhavya HU¹, Dr. Mahesh Babu^{2*}, Dr. Nishanth Gowda N³

¹ Department of OBG, KVG Medical College and Hospital, Sullia, Karnataka, India

² Department of Ophthalmology, KVG Medical College and Hospital, Sullia, Karnataka, India

³ KIMS, Bangalore, Karnataka, India

* Corresponding Author: Dr. Mahesh Babu

Abstract

The aim of the research is to examine fundus changes in Pregnancy Induced Hypertension and the correlation between the changes, hypertension levels, and the severity of the disease. Observation study was done on all the 120 patients selected from the antenatal wards, antenatal clinic, preeclampsia, and eclampsia rooms. The study was conducted for 14 months in the Department of Obstetrics and Gynecology and the Ophthalmic Output Department for ambulatory patients. Tests that were done and recorded include visual acuity, fundus examination using ophthalmoscope and retinopathy, and proteinuria examination. Among the 120 participants, 24% were below 20 years-old, 75% were between 21-30 years, and 1% above 30years. The age difference had little effect on fundus changes. There was gestational hypertension in 10% of the cases, 75% had preeclampsia, and 15% with eclampsia. There were fundus changes in 30 cases while 90 cases had no changes. There is a significant correlation between the levels of hypertension and disease severity. Ophthalmoscopy is a tool that is needed to determine retinal fundus changes and predict changes in the placenta so that fetal outcomes can be improved.

Keywords: pregnancy induced hypertension, ophthalmoscopy, fundus findings, and retinal detachment

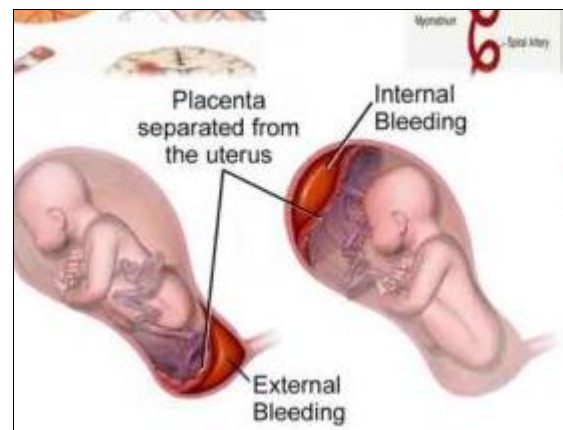
Introduction

Pregnancy Induced Hypertension (PIH) is a high blood pressure disorder in pregnant mothers that results in the absence of other elevated blood pressure causes. The blood pressures should be taken after a rest, on two occasions, and combined with generalized edema and proteinuria. PIH also includes gestational hypertension, pre-eclampsia, and eclampsia. Gestational hypertension refers to the condition where the blood pressure is 140/90 mm/Hg and above without proteinuria after 20 weeks of gestation (Madkar, Sinha, Burute, Puri, & Salvi, 2018) [4]. Pre-eclampsia involves proteinuria, and at times, it is associated with liver disease and coagulation abnormality. In cases where the disorder involves convulsions and coma, it becomes eclampsia. PIH is present in 10% of pregnant mothers with more prevalence among primiparae (Kintiraki, Papakatsika, Kotronis, Goulis, & Kotsis, 2015) [3]. Probable causes of PIG include genetic predisposition, endothelial dysfunction, dietary deficiencies, and immunological mechanisms.

In all cases, PIH begins after week 20 of gestation. The primary sign noticeable is hypertension (Karki *et al.*, 2017) [2]. Also, the initial stages are associated with edema of the lower legs, and it may progress to massive edema. This may be followed by proteinuria. Proteinuria is where a 24-hour urine sample contains 300 mg or more proteins. Also, the presence of 100mg/dl or more protein in at least two random urine samples which are collected at an interval of six hours apart (Bharathi, Raju, Prasad, Raju, & Mayee, 2015) [1].

Studies have been conducted and published about eclampsia. However, retinal changes in PIH have not been explored. Part of this research will; therefore, focus on the retinal changes and how they are associated with

proteinuria, blood pressure, and disease severity (Meher, Meher, & Jena, 2017) [7].



(Rosenthal & Johnson, 2018)

Fig 1: Eclampsia Symptoms

Aim

To determine fundus changes in Pregnancy Induced Hypertension (PIH) and to find the relationship between these changes and the hypertension levels as well as disease severity. The study will be based on data from KVG Medical College Hospital

Materials and Methods

The research was conducted on patients from KVG Medical College Hospital who have been diagnosed with Pregnancy Induced Hypertension. A total of 120 patients were used in observed in 14 months a data collected and analyzed using cross-sectional analytical study design.

Inclusion and Exclusion Criteria

All patients diagnosed with PIH in the hospital with a gestation period of 25 weeks and above were included in the study. Patients with the following conditions were excluded: coexisting diabetes mellitus, cataract, pre-existing hypertension, severe anemia, corneal opacities, and connective tissue disorders.

Methods

The first process in methodology was to take the relevant consent form from the hospital authorities, participants, and to comply with the ethical requirements. After the consent, visual acuity of the participants was taken at the bedside with the acuity of 6/9 or better being considered normal. Direct ophthalmoscope and retinopathy were used to conduct a fundus examination (Maurya, Srivastav, Chaudhary, Awasthi, & Rajan, 2018) [6]. Retinal changes among the participants were categorized into Grades I, II, III, and IV.

- **Grade I:** Cases of mild and general arterial narrowing.
- **Grade II:** Describe severe grade I and focal arterial narrowing.
- **Grade III:** Describe grade II cases coupled with hemorrhages and retinal edema.
- **Grade IV:** On top of the grade III changes, it includes retinal detachment and swelling of the optic disc. Photographs of the funds were also taken in some patients.

Cases of proteinuria were also recorded using the following reading chart:

- + = 0.3 gm/L
- ++ = 1gm/L
- +++ = 3gm/L
- ++++ = 10gm/L

Other parameters that were noted and recorded include age, gravida, BP values, and severity of the diseases.

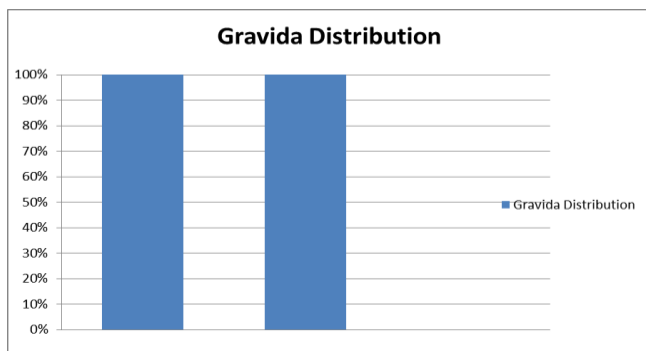
Results

Age distribution

The study was conducted on a total of 120 patients with ages ranging from 19 years to 36 years. 24% of the participants were below 20 years old, 75 percent were in the range of 21-30 years old, while only 1% was above 30 years old. Age differences had little effect on the degree of fundus changes.

Gravida Distribution

In 84 cases (70%), they were primigravidae while 36 (30%) cases were multigravidae.



(Rosenthal & Johnson, 2018)

Fig 1

Severity of Disease

PIH severity was classified into gestational hypertension, pre-eclampsia, and eclampsia. 12 cases (10%) had gestational hypertension, 60 cases (50%) had mild pre-eclampsia, 30 cases (25%) had severe pre-eclampsia, and 18 cases (15%) had eclampsia.

Table 1: Severity of Disease

Severity of Disease	With Changes	Without Changes
Gestational Hypertension	0	10
Mild Pre-eclampsia	7	53
Severe Pre-eclampsia	18	12
Eclampsia	6	12

(Shah *et al.*, 2015) [11]

Symptoms

Most cases did not present with symptoms. In 26% of the cases, patients presented with headache. 5% presented with blurred vision while only two cases had sudden loss of vision.

Visual Acuity

In 95% of the participants, visual acuity was normal (6/9 and better).

Fundus Changes

Only 30 cases (25%) had fundus findings. There was no change in 90 cases.

Table 2: Fundus Changes

Changes	Number (30)	Percentage
Grade I	20	16.67
Grade II	2	1.67
Grade III	6	5
Serious Retinal Detachment	2	1.67

(Shah *et al.*, 2015) [11]

Blood Pressure Values

Normal fundi represented the group with no BP changes. The mean systolic BP in this group was 150.46 ± 14.04 mm/Hg while the mean diastolic pressure was 98.42 ± 10.70 mm/Hg. The group with the fundus findings had a mean systolic BP of 168 ± 18.60 mm/Hg and a mean diastolic BP of 105.32 ± 15.34 mm/Hg.

Discussion and Literature Review

A previous study found out that there was a correlation between proteinuria, hypertensive retinopathy, and blood pressure. According to Tadin, Bojić, Mimica, Karelović, & Đogaš (2001) [13], there is a directly proportional relationship between the degree of retinopathy and severity of preeclampsia. Therefore, hypersensitive retinopathy can be relied on in the prognosis of preeclampsia severity (Patel *et al.*, 2018) [8]. In this study, there was less prevalence rate of fundus changes but the statistical correlation maintained. Another study by Reddy (2012) [9] that involved 78 patients with PIH gave a prevalence rate of 59%. According to the study, a positive association of fundus changes with blood pressure and disease severity was established. This study did

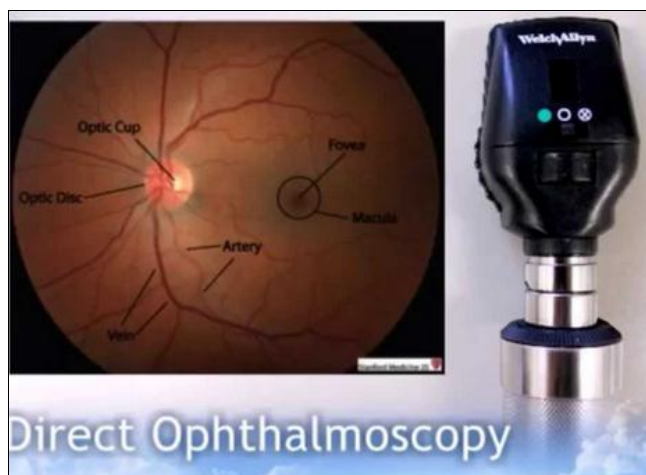
not record any cases of hemorrhage, cotton wool spots, or retinal detachment.

Retinal changes are common among patients with severe proteinuria, hypertension, and severe diseases (Marcos, Menéres, & Braga, 2018) [5]. The results of this study showed that the factors were present in cases with most changes. This study plus others on ocular fundus changes also confirm that there is an association between the three parameters and hypersensitive retinopathy. This research did not find any case of serious retinal detachment. A study conducted in Malaysia by Veerbeek *et al.* (2015) [14] reported one case of serious retinal detachment.

The changes in the retinal arterioles and retinal hemorrhages indicate that similar changes could be happening in the placenta (Shah *et al.*, 2015) [11]. The well-being and safety of a fetus depend on safe conditions within the placenta. Therefore, measures need to be taken to ensure that the circulation within the placenta is sufficient for fetal development (Soriano & Soriano, 2017) [12]. Mother's fundus needs to be examined regularly to determine any possible changes in the placental micro-circulation. This helps to improve fetal outcomes.

Conclusion

Obstetricians need ophthalmoscopy as a tool to assess disease severity in PIH cases. Present studies have confirmed that there are a significant correlation between hypertension levels and severity of the disease. This means that these cases need to be diagnosed and treatment began in time to prevent any possible complications. In most cases, fundus changes in PIH remain underdiagnosed. Current healthcare systems have invested much in patient awareness regarding various diseases and techniques for self-management and regular examinations. However, disease complications like serious retinal detachments continue to occur. This results in ocular morbidity during physiological states such as pregnancy. More studies are needed regarding the fundus changes in PIH to continue improving the fetal outcomes.



(Shah *et al.*, 2015) [11]

Fig 2: Direct Ophthalmoscopy

Acknowledgement

Statistical analysis support availed from Dr. Nishanth Gowda N, KIMS Bangalore

References

1. Bharathi NR, Raju NRS, Prasad PK, Raju RSN, Mayee K. Fundus changes in pregnancy induced hypertension: a clinical study. *Journal of Evolution of Medical and Dental Sciences*. 2015; 4(9):1552-1563.
2. Karki P, Basnet PS, Basnet A, Sijapati MJ, Manish KC, Pokharel K. Fundus Changes In Pregnancy Induced Hypertension. *Journal of Universal College of Medical Sciences*. 2017; 5(1):42-44.
3. Kintiraki E, Papakatsika S, Kotronis G, Goulis DG, Kotsis V. Pregnancy-induced hypertension. *Hormones*. 2015; 14(2):211-223.
4. Madkar CS, Sinha G, Burute S, Puri MS, Salvi PP. Effect of pregnancy induced hypertension on maternal and fetal outcomes. *Indian Journal of Obstetrics and Gynecology Research*. 2018; 5(1):20-26.
5. Marcos-Figueiredo P, Marcos-Figueiredo A, Menéres P, Braga J. Ocular Changes During Pregnancy. *Revista Brasileira de Ginecologia e Obstetrícia*. 2018; 40(1):32-42.
6. Maurya RP, Srivastav T, Chaudhary S, Awasthi P, Rajan M. Retinal vascular disorders during pregnancy: An observational study. *Indian Journal of Obstetrics and Gynecology Research*. 2018; 5(2):282-286.
7. Meher P, Meher SK, Jena SK. Cord blood parameters change in pregnancy induced hypertension. *International Journal of Research in Medical Sciences*. 2017; 5:5.
8. Patel DB, Patel RK, Patel H, Rana P, Rajput T, Brahmhatt J. A Study of Fundus Changes in Patients with Pregnancy Induced Hypertension Attending Tertiary Care Centre. *National Journal of Integrated Research in Medicine*. 2018; 9:1.
9. Reddy SC. Fundus changes in pregnancy induced hypertension. *International journal of ophthalmology*. 2012; 5(6):694.
10. Rosenthal JM, Johnson MW. Management of retinal diseases in pregnant patients. *Journal of ophthalmic & vision research*. 2018; 13(1):62.
11. Shah AP, Lune AA, Magdum RM, Deshpande H, Shah AP, Bhavsar D. Retinal changes in pregnancy-induced hypertension. *Medical Journal of Dr. DY Patil University*. 2015; 8(3):304.
12. Soriano NCT, Soriano MET. Pregnancy-associated Retinal Diseases. *Ophthalmology*. 2017; 3:249-282.
13. Tadin I, Bojić L, Mimica M, Karelović D, Đogaš Z. Hypertensive retinopathy and pre-eclampsia. *Collegium antropologicum*. 2001; 25(1):77-81.
14. Veerbeek JH, Hermes W, Breimer AY, Van Rijn BB, Koenen SV, Mol, BW, *et al.* Cardiovascular disease risk factors after early-onset preeclampsia, late-onset preeclampsia, and pregnancy-induced hypertension. *Hypertension*. 2015; 65(3):600-606.