

Study of common anatomical variations of the paranasal sinuses

Devika C¹, Ravindra BN^{2*}, Rajesh Raman³

^{1,2} Assistant Professor, Department of Radiology, Mandya Institute of Medical Sciences, Mandya, Karnataka, India

³ Professor and HOD, Department of Radiology, Mandya Institute of Medical Sciences, Mandya, Karnataka, India

Abstract

Purpose: This study aimed to determine the prevalence of common anatomical variations of paranasal sinuses by computed tomography (CT) images among the study population of patients attending OPD of ENT Department with complaints of chronic cold, nasal blocks, headache, etc.

Methodology: This observational study comprised of 124 patients who were recommended for FESS and were referred to the Radiology Department for CT scan of PNS between July 2019 to December 2019 at MIMS, Mandya. Various anatomical variations were evaluated, associated with the genders & age groups.

Results: The results showed both right and left sinuses were involved maximum in the maxillary sinus in 45(36.3%), ethmoidal sinus in 27 (21.8%), sphenoid sinus in 7(5.6%), paradoxical middle turbinate in 15 (12.1%), agger Nasi cells- 80 (64.5%) and maxillary sinus septations in 8 (6.5%). Choncha Bullosa was found in eighteen cases (14.5%) on right side, twelve (9.7%) on left side and bilateral in eighteen (14.5%) cases. Left side sinus was involved more in Frontal sinus-8 (6.5%). Right side sinus was involved more in maxillary sinus 24(19.4). Right side involvement was found in Haller cells-7 (5.6%), Onodi cells-11 (8.9%), and anterior clinoid process (ACP) Pneumatization in 13(10.5%) of the subjects.

Conclusion: It is extremely essential to know common anatomical variations of paranasal sinuses pre-operatively as they serve as a roadmap for ENT surgeons cautioning them in advance about the risks of damaging the normal structures thinking as pathology.

Keywords: paranasal sinuses, sinusitis, tomography

Introduction

Anatomical variations are extremely essential to be known, considered and well-identified in any surgical method, particularly when in plans for performing fine surgical procedures. The Endoscopic sinus surgery (ESS) is one of those very fine surgical procedures that make use of nasal endoscopes to expand the paranasal sinuses (PNS) nasal drainage pathways to improvise the ventilation of the sinus [1] This technique is usually used for treating infectious and inflammatory sinus diseases which also include chronic rhinosinusitis that does not respond to medications, nasal polyps, some cancers, and decompression of optic nerves/eye sockets in Graves ophthalmopathy [2] For a clinician, precise knowledge of PNS anatomy is important to identify while practicing functional endoscopic sinus surgery (FESS). Inadequate knowledge in surgeons performing ESS, regarding the commonly occurring anatomical variations can lead to a variety of complications having substantial mortality and morbidity.

There is the availability of several imaging modalities for PNS assessment. Conventional radiography offers valuable information on maxillary and frontal sinus disease but has a restricted function in the assessment of ethmoid, nasal cavity & sphenoid sinus. The conventional radiography does not delineate the osteomeatal complexes (OMC) [3] Optimum details regarding soft tissues, adjacent bones are obtainable with computed tomography making it the choice of imaging modality for PNS assessment. Direct coronal scanning and sagittal reconstructions, along with the axial sections, provide a detailed delineation of the micro anatomic locales and disease in the paranasal sinuses.[4]

Knowledge of these differences in each patient is necessary to prevent damage to important surrounding structures like the brain and the orbit before conducting FESS. As it is known that there is a lot of variations based on gender and age among individuals and the prevalence of these variations varies across different ethnic groups [4].

The English literature has rich descriptions in anatomical variations of paranasal sinus, but there is a dearth of such research, as well as a dearth of studies dealing gender and age groups disparities in these anatomical variations. The incidence of more common anatomical variations are DNS, agger nasi, and incidence of sinus cells was seen in Kraikal, South India [5] In Pallakad, Kerala, all the patients had at least one anatomical variation and a high incidence of more than one anatomical variation was observed among the population [6] Increased prevalence of concha bullosa among females was reported among Indian ethnic groups.[7,8] With this scenario, this study was carried out to evaluate the different anatomical variations among individuals who underwent CT scan in the Department of Radiology at MIMS, Mandya.

Materials and methods

In this observational study, a total of 124 patients who were recommended for FESS and were referred to the Radiology Department for CT scan between July 2019 to December 2019 and were enrolled for this study. The study was initiated after obtaining Ethical Committee approval. Informed Consent was obtained from the study subjects. Subjects with previous sinus surgery, nasal polyposis, severe cervical arthropathy, sinonasal tumors, or neck and

head injury were excluded. The CT scans of the subjects aged 12 to 70 years of both sexes planned for FESS were included in the study. The age and sex of the patient along with the symptoms and its duration were recorded. A complete medical history and physical examination of the head and neck were carried out on all subjects. A high resolution, 1 mm thick CT scan of paranasal sinuses in three planes namely, axial, coronal, and sagittal planes were obtained using Philips 16 slice CT scanner. Several clinically

Pertinent anatomical variations evaluated were associated to the genders and age groups. SPSS v.22 was used for data analysis.

Results

The study included 124 subjects— 63.7% males and 36.3% females. The age of the study population ranged between 5 & ≥ 55 years old with a mean age of 34 years. Most of the study subjects were young and middle-aged adults, ranging from 16 to 45 years, 67.7% (Table 1).

Table 1: Distribution of the subjects based on age and gender

S. No.	Characteristics	Frequency	Percent
1	Age in years		
	Mean age 33.62 ± 16.03		
	5 to 15 yrs	14	11.3
	16 to 25 yrs	35	28.2
	26 to 35 yrs	26	21.0
	36 to 45 yrs	23	18.5
	46 to 55 yrs	13	10.5
	Above 55 yrs	13	10.5
	Total	124	100
2	Gender		
	Male	45	36.3
	Female	79	63.7
	Total	124	100.0

The presence of Deviated nasal septum was seen in 56.4%, primarily to the right side (30.6%). Amongst gender and age groups, the young adult male group showed its highest presence (63.7%). Both right and left sinuses were

involved— maximum in maxillary sinus – 45 (36.3%), followed by ethmoidal sinus – 27 (21.8%), ACP pneumatization-13 (10.5%), maxillary sinus septations- 8 (6.5%), and sphenoidal sinusitis in 7 (5.6%) (Table 2).

Table 2: Distribution of sinus involvement among subjects

		Right	Left	Both	Nil	Total
Maxillary sinus	n	24	20	45	35	124
	%	19.4	16.1	36.3	28.2	100
Ethmoidal sinus	n	5	6	27	86	124
	%	4.0	4.8	21.8	69.4	100
Sphenoidal sinus	n	7	4	7	106	124
	%	5.6	3.2	5.6	85.5	100
Frontal sinus	n	3	8	3	110	124
	%	2.4	6.5	2.4	88.7	100
Concha Bullosa	n	18	12	18	76	124
	%	14.5	9.7	14.5	61.3	100
Paradoxical middle turbinate	n	14	6	15	89	124
	%	11.3	4.8	12.1	71.8	100
Aggar Nasi cells	n	6	1	80	37	124
	%	4.8	.8	64.5	29.8	100
Haller cells	n	7	5	3	109	124
	%	5.6	4.0	2.4	87.9	100
Onodi cells	n	11	7	10	96	124
	%	8.9	5.6	8.1	77.4	100
ACP Pneumatization	n	13	8	10	93	124
	%	10.5	6.5	8.1	75.0	100
Maxillary Sinus Septations	n	6	7	8	103	124
	%	4.8	5.6	6.5	83.1	100

The frontal sinus was involved in 3 cases (2.4%), only on right side in 3 (2.4%) and on left side 8 (6.5%) (Table 2). All sinuses were involved in 23 of 124 cases (18.5%). The Onodi air-cell, the most posterior ethmoid air cell, was seen to be present bilaterally in 10 cases (8.1%), in 11 cases

On the right side (8.9%) and in 7 cases on the left (5.6%). The bilateral Onodi cells found to exhibit Type IV Optic nerves. (Table 2 and Figure 1A and 1B). The asymmetry of Olfactory Fossa was present in 38 (30.6%). (Table 2 and Figure 2).

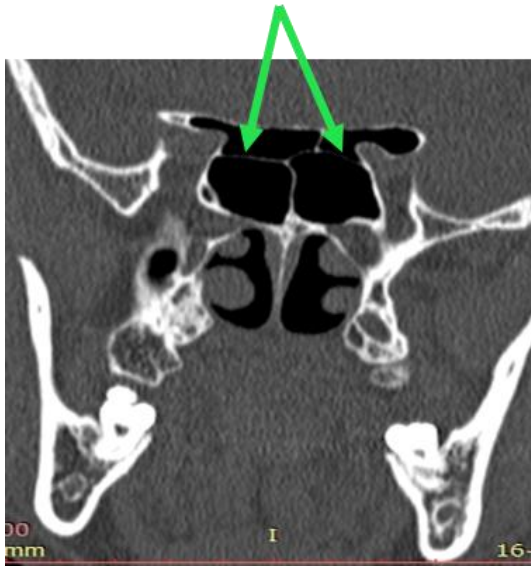


Fig 1: ABilateral Onodi cells.

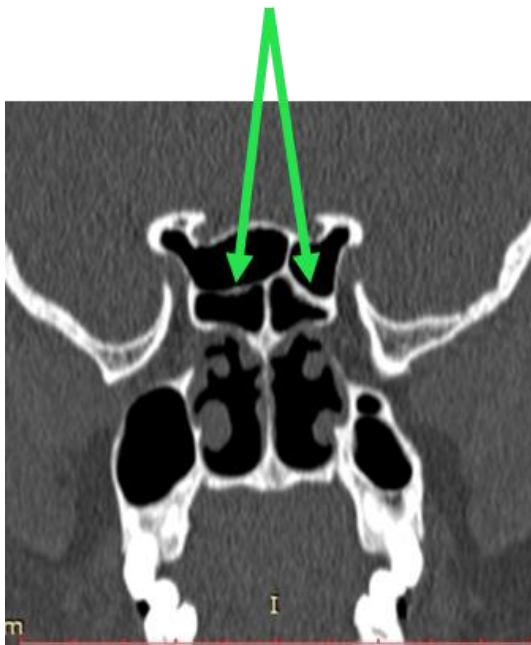


Fig 2: Bilateral Onodi cells with Type IV Optic nerves

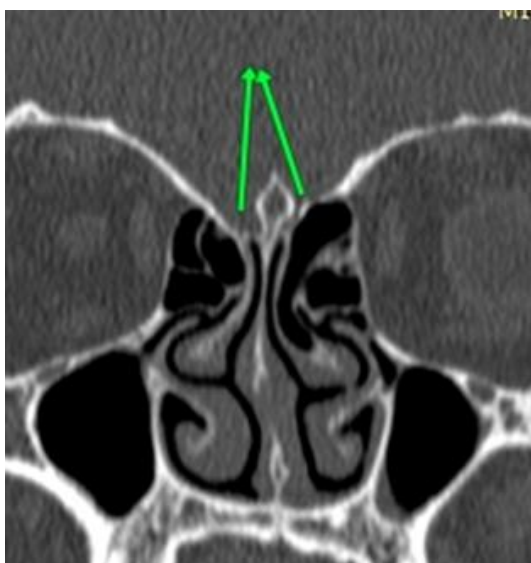


Fig 3: Asymmetry of olfactory fossa

The middle turbinate was seen to be paradoxical in shape in 15 (12.1%), 14 (11.3%) on the right side and 6 (4.8%) on the left side. (Table 2 and Figure 3). The concha bullosa was seen bilaterally in 18 (14.5%), on the right side 18(14.5%) and 12 (9.7%) on the left side (Table 2 and Figure 4). The most common variant, Aggar Nasi cells were seen in 80 (64.5%), 6 (4.8%) on the right side, and 1(0.8%) on the left side. (Table 2 & Figure 5). The air-cell of Haller, the anterior ethmoid air cell situated in the orbital floor, was found to be present bilaterally in 3 (2.4%), 7 (5.6%) on the right side, and 5 (4.0%) on the left (Table 2 Figure 6A and 6B).

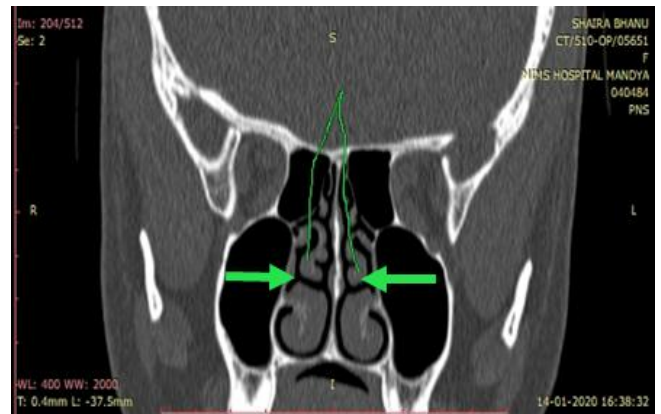


Fig 4: Bilateral paradoxical middle turbinates

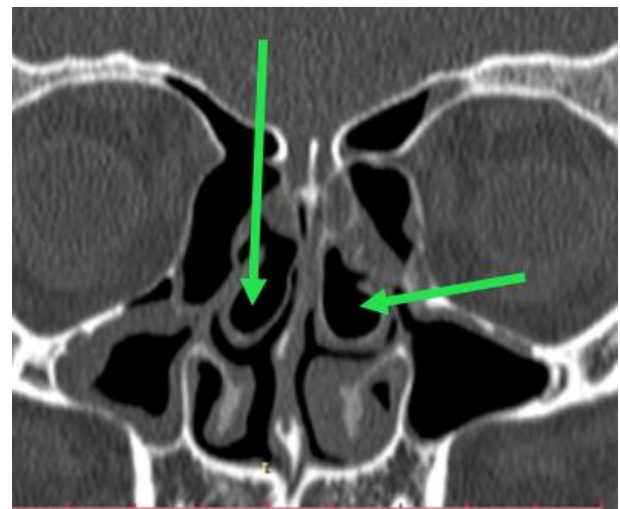


Fig 5: Bilateral concha bullosa

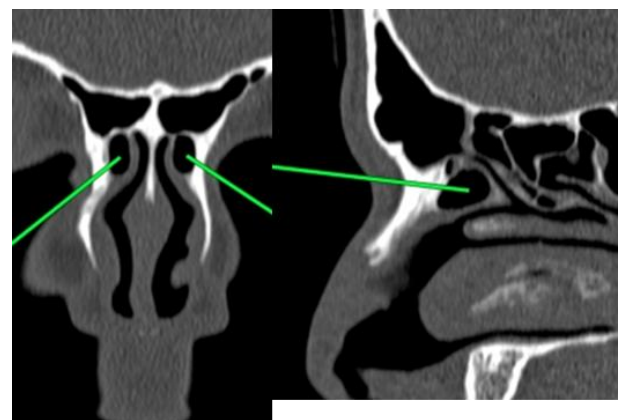

Fig 6: Bilateral Aggar Nasi cells anterior to Naso-frontal recess

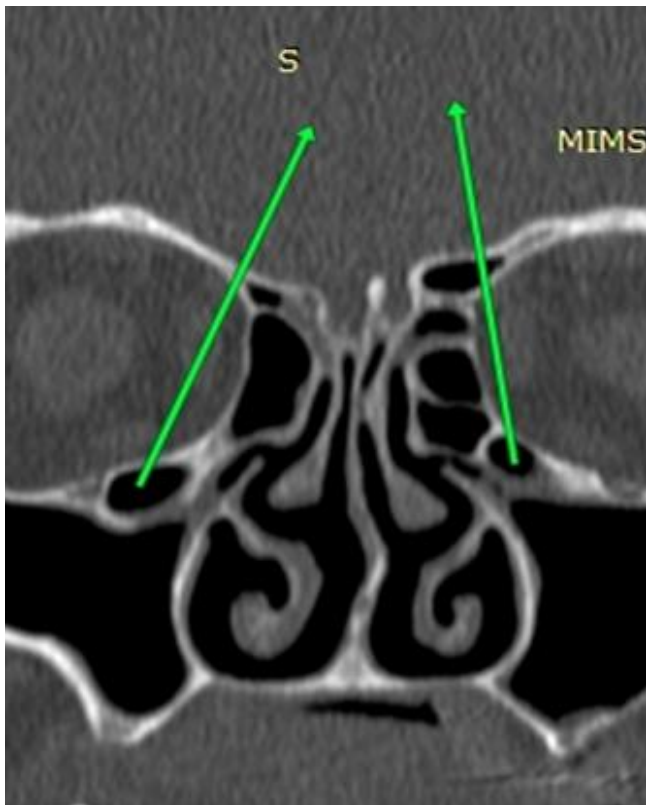


Fig 7: Bilateral Haller cells

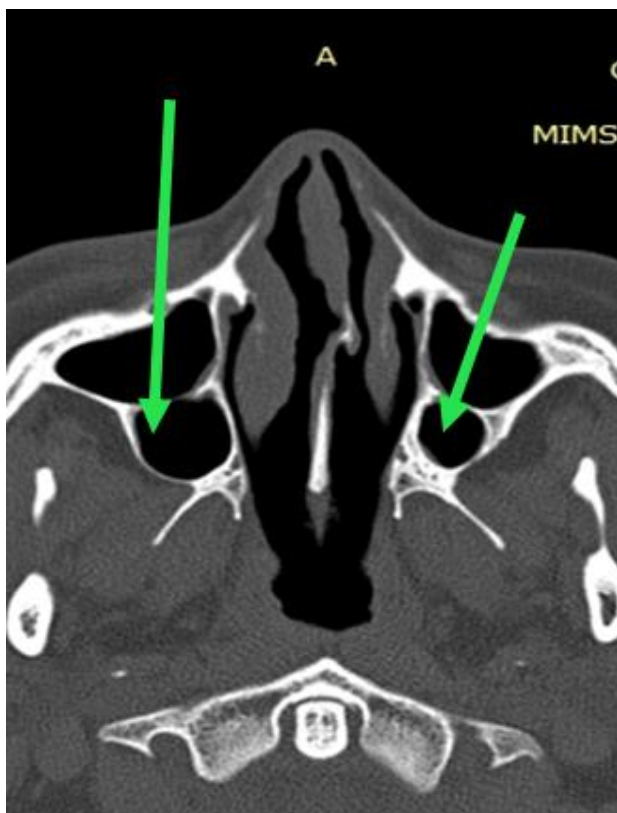


Fig 8: Septations in bilateral maxillary sinuses

Discussion

Anatomy of the Sinonasal is clinically and radiologically complex. The reason for its complexity is the wide range of anatomical variations that might affect the pathophysiology and surgical techniques in this field.^[9] Hence a surgeon needs to understand it well. ESS is a fine procedure in which a surgeon ought to be well organized and meticulous

concerning each part of this complex anatomy. Studying and reporting the anatomical variations ought to be useful for otorhinolaryngologist to consider those variations when handling the subjects and planning for surgical interventions on them. There are four paranasal sinuses pairs in human being. Embryo logically developing in this sequence, ethmoid, maxillary, sphenoid, and frontal. These sinuses have a different degree of development and pneumatization, and variable relationships with surrounding structures, particularly the base of the skull and orbit. Furthermore, the lateral nasal wall is comprised of 3 turbinate's, uncinat processes, & perpendicular plate of palatine bone. Variant relations are seen among each of these structures with sinuses, orbit, and base of the skull.^[10, 11] Computed tomography as a gold standard, is extremely essential to assess anatomical variation of the paranasal sinuses, these variations and in correlating them with inflammatory changes of the paranasal sinuses. Furthermore, it is highly essential to plan any surgical intervention. Inadvertent breach of the cribriform plate might bring about leakage of cerebrospinal fluid, direct penetration trauma to the dura, severe intracerebral & intracranial complications.^[12,3] Nouarei *et al.* studied the anatomical variations incidence among 278 subjects in the year 2009 and concluded that no correlation existed between anatomical variations of bony structures and the risk of developing sinus mucosal disease. Despite this observation, the potential impact on surgery safety cannot be excluded. Hence, the evaluation of anatomical variations is necessary during the pre-operative assessment^[12].

In this study, 124 subjects of age group between 5 and ≥ 55 years old were included. The subjects' mean age who underwent study was 34 years and the majority of subjects studied were young adults (16 to 45 years of age). It was highest among the gender and age groups i.e. 63.7% in the young adult male population was similar to the other studies.^[13-15] Deviated Nasal septum 56.4%, Concha Bullosa 14.5%, were the noted anatomical variations. These results could be compared to the local study carried out by Santos *et al* & between the Caucasian & Mediterranean populations, which displayed that the most prevalent anatomical variant was Agger Nasi followed by Septal Deviation & Concha Bullosa^[16] In our study, there is a common incidence of Maxillary sinusitis (36.3%). This is reported in three other studies reported in the literature.^[17,18] Maxillary Sinus Septations was found to be 6.5% in our study, these findings were similar to Alshaikh N *et al*^[19] Paradoxical Middle Turbinate was 30.6%, and literature reports revealed that its incidence was 2-3 times more the incidence we found in our subjects^[18, 20].

In our research, the Agger nasi cells incidence was noted to be 64.5%. This result was comparable to a research performed between the Caucasian & Mediterranean populations, which found Agger Nasi to be the most ubiquitous anatomical variant^[16, 21, 22] In our study, the incidence of isolated frontal sinusitis was 2.4%, whereas it was 19% and 26.9% in other study findings.^[9, 19] There is a lesser incidence of frontal sinusitis in this study, whereas its incidence was higher when compared to several other studies reported in the literature^[12, 23, 24] In our study, the incidence of anterior ethmoid air-cells is 22.6%. This is highly essential to be assessed as a latent illness can be missed which could lead to persistence or recurrence of symptoms. The Haller & Onodi ethmoid air-cell have been

well studied in recent papers. In our study, 2.4% of Haller air cell were found to be lesser, while 8.1% of Onodi air cell and 6.5% of maxillary sinus septations were found to be comparable to most other studies [19, 25]. The Asymmetry of Olfactory Fossa 30.6% in our study and in the recent study reported by Madani GA *et al* wherein it was found to be 22.5 % [26].

These wide ranges of variations regarding the asymmetry, gender, or laterality among various populations may be attributed to genetic or ethnic causes [4, 12, 23]. Hence it is very important to take care of anatomical variations of PNS while reviewing and planning endoscopic sinus surgery.

Conclusion

Paranasal sinuses anatomical variations are highly essential to be detected pre-operatively, as these variations are seen to differ amongst gender, age, & demographic locations. We reported important anatomical variations *viz.* Concha Bullosa, Agger Nasi cells, Haller cells, & Onodi cells and the results of this study on these anatomical variations of paranasal sinuses have clinical importance in minimizing complications of sinus surgery.

References

1. Yarlagadda A, Murthy JV, Prasad MK. A novel method for human age group classification based on Correlation Fractal Dimension of facial edges. *Journal of King Saud University-Computer and Information Sciences*. 2015; 27(4):468-76.
2. Lebowitz RA, Terk A, Jacobs JB, Holliday RA. Asymmetry of the ethmoid roof: analysis using coronal computed tomography. *The Laryngoscope*. 2001; 111(12):2122-4.
3. Başak S, Akdilli A, Karaman CZ, Kunt T. Assessment of some important anatomical variations and dangerous areas of the paranasal sinuses by computed tomography in children. *International journal of pediatric otorhinolaryngology*. 2000; 55(2):81-9.
4. Alrumaih RA, Ashoor MM, Obidan AA, Al-Khater KM, Al-Jubran SA, *et al.* Radiological sinonasal anatomy: exploring the Saudi population. *Saudi Medical Journal*. 2016; 37(5):521.
5. Gouripur K, Kumar U, Janagond AB, Elangovan S, Srinivasa V. Incidence of sinonasal anatomical variations associated with chronic sinusitis by CT scan in Karaikal, South India. *International Journal of Otorhinolaryngology and Head and Neck Surgery*. 2017; 3(3):576-9.
6. Vinodhini P. Anatomical Variations of the Nose and Paranasal Sinuses in Palakkad Population Using CT Scan-A Case Control Study. *Online Journal of Health and Allied Sciences*. 2017; 16(1).
7. Tuli IP, Sengupta S, Munjal S, Kesari SP, Chakraborty S. Anatomical variations of uncinat process observed in chronic sinusitis. *Indian Journal of Otolaryngology and Head & Neck Surgery*. 2013; 65(2):157-61.
8. Srivastava M, Tyagi S. Role of anatomic variations of uncinat process in frontal sinusitis. *Indian Journal of Otolaryngology and Head & Neck Surgery*. 2016; 68(4):441-4.
9. Fadda GL, Rosso S, Aversa S, Petrelli A, Ondolo C, Succo G, *et al.* Multiparametric statistical correlations between paranasal sinus anatomic variations and chronic rhinosinusitis. *ACTA otorhinolaryngologica*. 2012; 32(4):244.
10. Roman RA, Hedeşiu M, Gersak M, Fidan F, Băciuş G, Băciuş M, *et al.* Assessing the prevalence of paranasal sinuses anatomical variants in patients with sinusitis using cone beam computer tomography. *Clujul Medical*. 2016; 89(3):423.
11. Adeel M, Rajput MS, Akhter S, Ikram M, Arain A, Khattak YJ, *et al.* Anatomical variations of nose and para-nasal sinuses; CT scan review. *Journal of the Pakistan Medical Association*. 2013; 63(3):317.
12. Nouraei SA, Elisay AR, Dimarco A, Abdi R, Majidi H, Madani SA, *et al.* Variations in paranasal sinus anatomy: implications for the pathophysiology of chronic rhinosinusitis and safety of endoscopic sinus surgery. *Journal of Otolaryngology-Head and Neck Surgery*. 2009; 38(1):32.
13. Espinosa W, Genito R, Ramos RZ. Anatomic variations of the nasal cavity and paranasal sinus and their correlation with chronic rhinosinusitis using Harvard staging system. *J Otolaryngol ENT Res*. 2018; 10(4):190-3.
14. Kaygusuz A, Haksever M, Akduman D, Aslan S, Sayar Z. Sinonasal anatomical variations: their relationship with chronic rhinosinusitis and effect on the severity of disease—a computerized tomography assisted anatomical and clinical study. *Indian Journal of Otolaryngology and Head & Neck Surgery*. 2014; 66(3):260-6.
15. Hadi HH, Al-Bayati HA, Al-Gazali SS. Prevalence of normal anatomical variations in the region of paranasal sinuses in patients with chronic rhinosinusitis. *Medical Journal of Babylon*. 2018; 15(3):243-50.
16. Santos CA, Jarin PS. Computed Tomographic Analysis of Paranasal Sinus Anatomic Variations among Filipinos. *The Philippine Journal of Otolaryngology Head and Neck Surgery*. 2003; 19(3-4):155-160.
17. Abdul-Hameed A, Daudu ZA, Abubakar B, Shiitu BS, Danjuma UJ, Aziz MM, *et al.* Normal anatomical variations of maxillary sinus septa using computerized tomography from Sokoto Northwestern Nigeria. *West African Journal of Radiology*. 2016; 23(1):12.
18. Shokri A, Faradmal MJ, Hekmat B. Correlations between anatomical variations of the nasal cavity and ethmoidal sinuses on cone-beam computed tomography scans. *Imaging science in dentistry*. 2019; 49(2):103-13.
19. Alshaikh N, Aldhurais A. Anatomic variations of the nose and paranasal sinuses in Saudi population: computed tomography scan analysis. *The Egyptian Journal of Otolaryngology*. 2018; 34(4):234.
20. Shalini S, Gopal T. Paradoxical Curvature of Middle Turbinate: A Computed Tomographic Study. *International Journal of Contemporary Medical Research*. 2018; 5(9):110-113.
21. Baradaranfar MH, Labibi M. Anatomic variations of paranasal sinuses in patients with chronic sinusitis and their correlation with CT scan staging. *Acta Medica Iranica*, 2007, 477-80.
22. Madani SA, Hashemi SA, Kianejad AH, Heidari S. Association Between Anatomical Variations of the Sinonasal Region and Chronic Rhino-Sinusitis: A Prospective Case Series Study. *Acta Facultatis Medicinae Naissensis*. 2013; 30(2):73-7.
23. Al-Abri R, Bhargava D, Al-Bassam W, Al-Badaai Y,

- Sawhney S. Clinically significant anatomical variants of the paranasal sinuses. *Oman Medical Journal*. 2014; 29(2):110.
24. Perez-Pinas I, Sabate J, Carmona A, Catalina-Herrera CJ, Jimenez-Castellanos J. Anatomical variations in the human paranasal sinus region studied by CT. *Journal of anatomy*. 2000; 197(2):221-7.
25. Devareddy MM, Devakar S. Evaluation of Anatomical Variations in Nose and Paranasal Sinuses by using Multidetector Computed Tomography. *Indian Journal of Contemporary Medicine Surgery and Radiology*. 2018; 4(3):C146-C151.
26. Madani GA, El-mardi AS, El-Din WA. Analysis of the anatomic variations of the ethmoid roof among Saudi population: A radiological study. *Eur J Anat*. 2020; 24(2):121-8.