

## Role of MRI in rotator cuff injuries

\*<sup>1</sup> Dr. Tushar Kalekar, <sup>2</sup> Dr. Rajesh Kuber

<sup>1</sup> Associate Professor, Department of Radiology, DY Patil Medical College, Pimpri, Pune, Maharashtra, India

<sup>2</sup> Professor, Department of Radiology, DY Patil Medical College, Pimpri, Pune, Maharashtra, India

### Abstract

MRI provides useful information regarding rotator cuff tears such as tear dimensions, tear depth or thickness and tear shape, involvement of adjacent structures (eg, rotator interval, long head of biceps brachii tendon etc) and muscle atrophy, all of which have implications for rotator cuff treatment and prognosis. Information about coracoacromial arch and impingement as it relates to rotator cuff tears can also be obtained with MRI. It provides accurate information regarding glenoid labrum injuries and helps to classify the injuries.

**Keywords:** MRI, rotator cuff, hillsach's lesion, bankart's lesion

### 1. Introduction

The shoulder joint is an elegant anatomic structure; its range of motion exceeds all other joints, yet, under most circumstances, it is stable. The shoulder joint relies on a variety of structures for stability, including the osseous glenoid, the fibrous labrum, the joint capsule, the glenohumeral ligaments, and various muscles about the shoulder <sup>[1]</sup>.

The shoulder joint is a ball and socket type of joint that has two main stabilizers: the rotator cuff muscles (dynamic) and the labral-ligamentous complex (static). The primary function of the rotator cuff muscles (supraspinatus, infraspinatus, subscapularis, and teres minor) is to centralize the humeral head, limiting superior translation during abduction <sup>[2]</sup>.

The rotator cuff consists of the supraspinatus, infraspinatus, subscapularis, and teres minor muscles and tendons. <sup>(fig.1)</sup>At the distal aspect of the rotator cuff, tendons splay out and interdigitate, forming a common continuous insertion on the middle facet of the humeral greater tuberosity. <sup>3</sup>The rotator cuff is a functional-anatomic unit rather than four unrelated tendons, and injury to one component may have an influence on other regions of the rotator cuff <sup>[4]</sup>.

The shoulder has the greatest range of motion of any joint in the body, making it tremendously versatile. This versatility makes the joint unstable and liable to injuries. Anatomically, the articulation of the large humeral head with the small glenoid cavity confers relatively little joint stability. The glenoidlabrum provides attachments for the shoulder capsule and various tendons and ligaments, which contributes to shoulder stability by increasing the glenoid surface <sup>[5]</sup>.

MRI can provide information about rotator cuff tears such as tear dimensions, tear depth or thickness and tear shape, <sup>(fig.2)</sup>involvement of adjacent structures (eg, rotator interval, long head of biceps brachii tendon etc) and muscle atrophy, all of which have implications for rotator cuff treatment and prognosis. Information about coracoacromial arch and impingement as it relates to rotator cuff tears can also be obtained with MRI <sup>[3]</sup>.

### 2. Aims and Objectives

The purpose of this study is:

- To identify the rotator cuff tear
- To describe MRI grading of rotator cuff injuries.
- To study the diagnostic accuracy of MRI in detection and characterisation of rotator cuff injuries.

### 3. Materials and Methods

- All patients who are clinically suspected of a rotator cuff and labrum injury and referred to the department of Radiodiagnosis, Dr. D.Y. Patil Medical College Hospital and Research Centre, Pimpri, Pune will be evaluated with clinical history and MR imaging. The characteristics of different rotator cuff and labrum disorders will be described.
- All patients with clinical suspicious of rotator cuff and labrum injuries.
- Cases of all age groups irrespective of sex
- Patients with metallic implants, cardiac pacemakers, cochlear implants.
- Post treatment patients.
- Post-surgery patients.
- Patients who are claustrophobic.

#### Technique

MRI performed using 1.5 T Siemen's Scanner with use of dedicated shoulder surface coil.

Axial, sagittal and coronal T1 and PD fat sat images were obtained with 3 mm slice thickness. Followed by Axial gradient images of 1mm thickness

#### Observations

Age	Patients
30-40	30 (30%)
41-50	34 (34%)
51-60	22 (22%)
>60	14 (14%)

Sex	Patients
Male	72
Female	28

**MRI in Rotator Cuff Pathology**

Findings	Number of patients	percentages
Supraspinatus lesions	74	74%
Infraspinatus lesions	30	30%
Subscapularis lesions	7	7%
Biceps tendon pathologies	40	40%
Joint effusion	66	66%
Bony changes	39	39%
Labral pathologies	22	22%
Glenohumeral ligaments	5	5%
Normal	12	12%

**MRI in Recurrent Dislocation and Instability**

In total 9 patients of recurrent dislocation of shoulder were evaluated on MRI. These patients had several lesions other than rotator cuff pathologies, which are-

MRI Findings	Number of patients	Percentage
Hill-Sachs lesion	16	88.8%
Bony bankart's lesion	18	100%
Cartilaginous Bankart's lesion	18	100%
Labral tear	18	100%
Glenohumeral ligament tear	0	0%

**4. Discussion**

MRI have become the standard imaging technique for successfully diagnosing rotator cuff lesions and primary form of investigation for recurrent dislocation and instability.

In the present study, the most common age group of patients presenting with a rotator cuff injury was in the 41-50 years range. Males were the majority of the patients constituting around 72% of the cases.

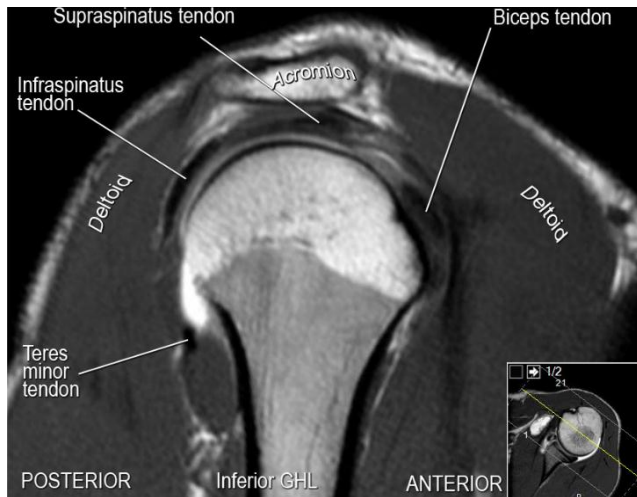
Over all rotator cuff pathology including rotator cuff tears and impingement was the most common cause for radiology referral, comprising almost 88% of our cases. (fig.3) this is in accordance with the study done by Hawkins *et al* [6] who found that more than 60% of shoulder abnormalities were due to rotator cuff disease.

Supraspinatus tendon was more commonly involved than Infraspinatus or Subscapularis tendon of all the lesions Zlatkin *et al* [7] wherein they found supraspinatus tendon involvement in around 80% of their cases. The characteristic anatomic location of the supraspinatus tendon is the likely cause.it is located between the greater tuberosity and the acromion process leading to repeated friction during overhead abduction of the shoulder. (Fig 4)

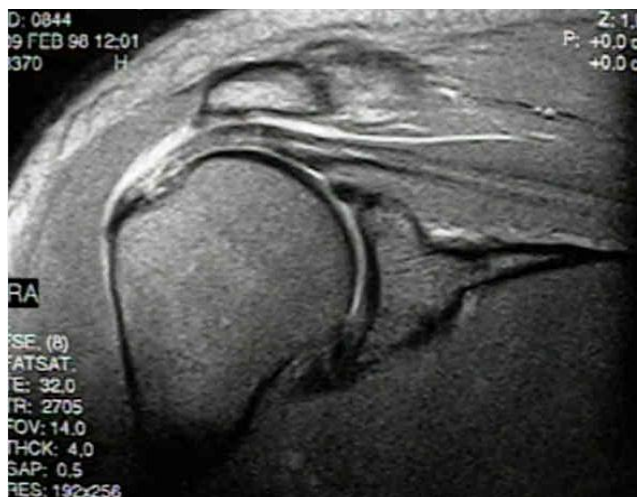Subsapularis tendon tear have always been considered uncommon and most commonly it is associated with supraspinatous and/or infraspinatous tear (fig. 6). In our study we found only 4 patients with subscapularis tendon tear. (Fig 5)These findings correlate well with that of codman *et al*, who reported involvement of subscapularis tendon in less than 3.5% patients in a series of 200 rotator cuff tears [8]

MRI easily detected various bone changes like bankart's lesion, hill-sach's lesion, (fig 7) labro-ligamentous lesions. Partial thickness tears were the most common pathologies in rotator cuff group.

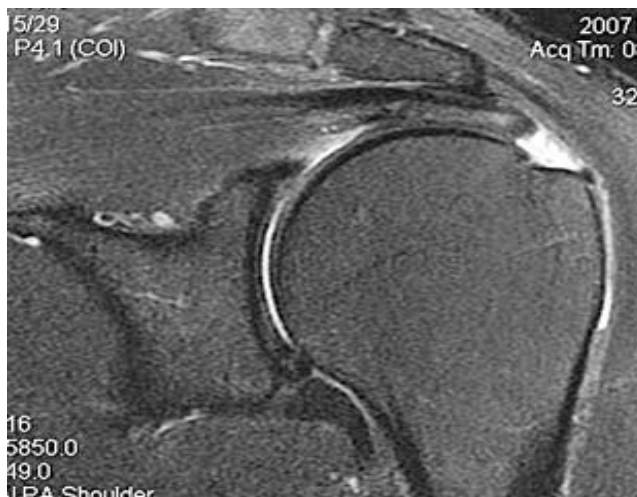
In cases of recurrent dislocation of shoulder and instability MRI successfully detected labral involvement in all cases. The sensitivity, specificity and accuracy for detecting Bankart lesions (fig 8) for MRI were 100%, 100%, and 100% respectively which were corresponding to the study of Joseph P Iannotti *et al* [9].



**Fig 1:** Normal anatomy of rotator cuff (sagittal T1)



**Fig 2:** Supraspinatus tendon partial tear distal portion (Coronal PD)



**Fig 3:** Full thickness tear of supraspinatus tendon with proximal retraction (coronal PD)

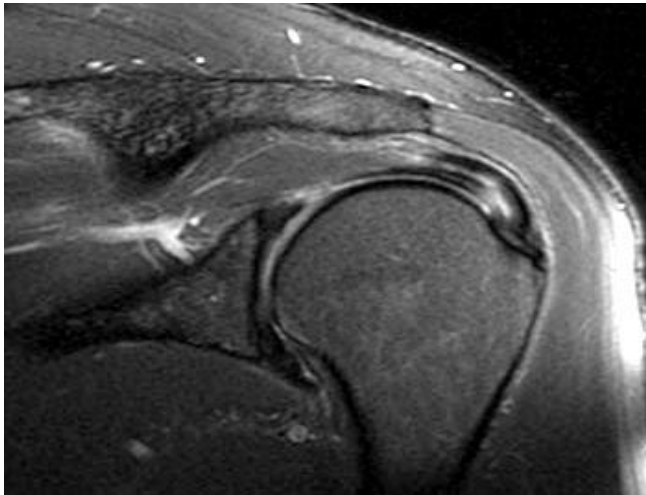


Fig 4: Intrasubstance tear of supraspinatus tendon (coronal PD)

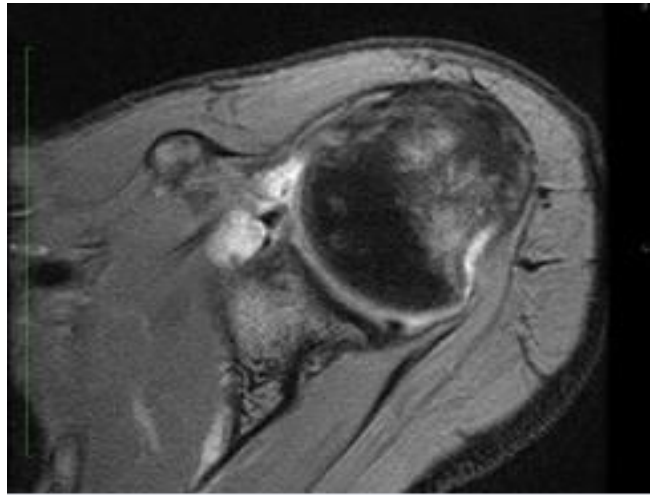


Fig 7: Hill-Sachs's lesion (Axial PD)

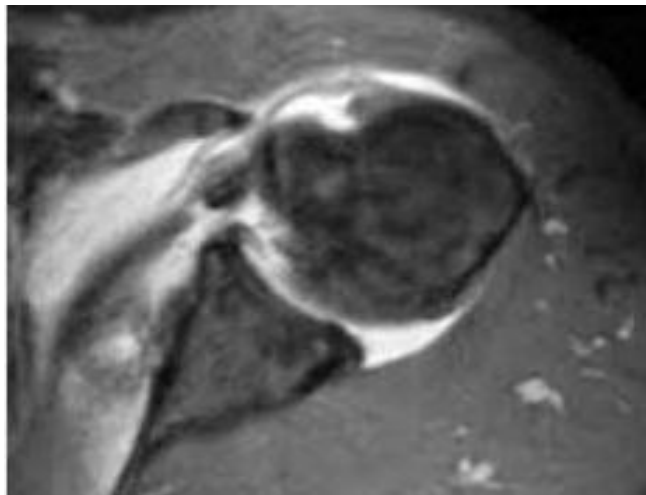


Fig 5: Subscapularis tendon partial tear with fluid collection in subcoracoid bursa (Axial PD)

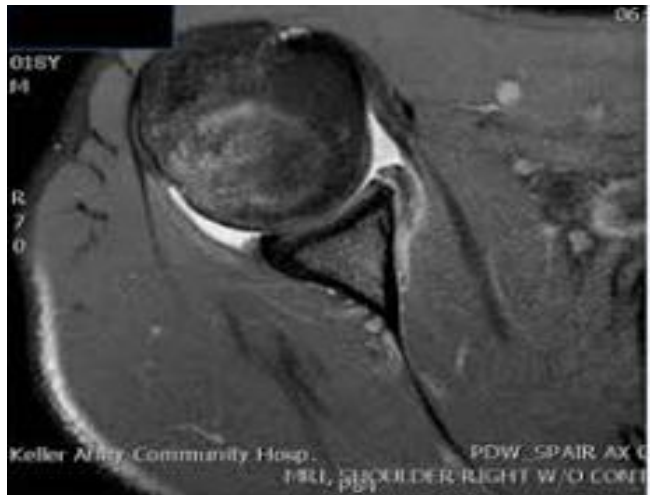


Fig 8: Bankart's lesion (Axial PD)

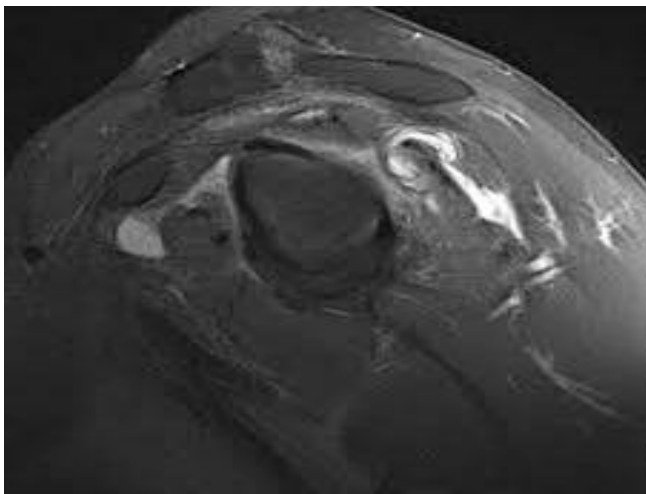


Fig 6: Infraspinatus tendon tear myotendinous junction (sag PD)

### 5. References

1. Joshua M, Farber, Kenneth A, Buckwalter. Sports-related injuries of the shoulder instability. *Radiologic clinics of North America*. 2002; 40(5):235-236.
2. Stoller DW. *Magnetic resonance imaging in orthopaedics and sports medicine*. 3<sup>rd</sup> ed. Philadelphia: Lippincott Williams and Wilkins. 2007, 1324-412.
3. Yoav Morag, Jon A, Jacobson, Bruce Miller, Michel De Maeseneer. MR Imaging of Rotator Cuff Injury: What the Clinician Needs to Know: *RadioGraphics*. 2006; 26(4):1046-1047.
4. Sharkey NA, Marder RA, Hanson PB. The entire rotator cuff contributes to elevation of the arm. *J Orthop Res*. 1994; 12(5):699-708.
5. Cernyik DL, Ewald TJ, Sastry A, Amin NH, Liao JG, Tom JA. Outcomes of isolated glenoid labral injuries in professional baseball pitchers. *Clin J Sport Med*. 2008; 18(3):255-8.

6. Hawkins RJ, Kunkel Sanford S. Rotator cuff tear. In: Torg JS, Welsh RP, Shepherd RJ. Current therapy in sports medicine-2. Toronto: BC Decker, 1999.
7. Zlatkin MB, Lannotti JP, Roberts MC *et al.* Rotator cuff tear: Diagnostic performance of MR imaging. *Radiology*, 1989.
8. Codman EA. The shoulder: rupture of the supraspinatus tendon and other lesions in or about the subacromial space. Boston, Mass: Thomas Todd, 1934.
9. Iannotti JP, Zlatkin MB, Esterhai JL *et al.* MRI of the shoulder: Sensitivity, specificity and predictive value. *J Bone Joint Surg Am.* 1991; 73:17-29.