



## Management of idiopathic CTEV by Ponseti method: A prospective study

\*<sup>1</sup> Reneesh Uruniyan Paramban, <sup>2</sup> Rahul MK

<sup>1</sup> Assistant professor, Department of Orthopedics, Kerala Medical College & Hospital, Palakkad, Kerala, India

<sup>2</sup> Junior Resident, Department of Orthopedics, Kerala Medical College & Hospital, Palakkad, Kerala, India

### Abstract

**Background:** Congenital idiopathic clubfoot is a complex deformity which occurs in an otherwise normal child. The Ponseti method of clubfoot management has been shown to be effective, producing better results and fewer complications than traditional surgical methods. The Ponseti technique is a well-proven way of managing paediatric clubfoot deformity. We describe a management set-up which spreads the care between secondary and tertiary care with no loss of quality.

**Patients and Methods:** Data was collected from patients with idiopathic clubfoot, presenting at Kerala Medical College & Hospital, Palakkad a teaching institution between October 2015 to October 2017. Both unilateral and bilateral were included in the study.

In present series, we have treated 30 children with idiopathic clubfoot by Ponseti method of correction of serial manipulation and casting. Among the 30 children, 17 had unilateral and 13 bilateral involvement. Most children had grade III and grade IV (Dimeglio et al grading) deformity. The mean number of casts required was 5.76 (4 to 10). Tenotomy was required in 12 feet (40%). The scores for the entire group ranged from 4.0 to 7.0 (of 10) and 4 to 19 (of 20) in the Dimeglio classification. Pirani scores for the age group 0- 6 months were 4.46, 6 months to 1 year were 5.36 and 1-2 years were 5.75 respectively. The results were excellent in 88.3% and good in 11.7%. Initial and final scores were statistically evaluated with paired 'T' test with a 'T' value of 36.76 with a 'P' value of less than 0.001. Thus there was a significant reduction in the score from the pre level because of intervention.

**Results:** Similar good results and low requirement for surgical interventions other than Achilles tenotomy, which forms part of the Ponseti regimen, were found. In terms of number of patients the success rate is 87% and in terms of the number of feet the success rate is 91%.

**Conclusions:** This study demonstrates that treatment of congenital talipes equine varus by conservative management of ponseti method can be sufficient.

**Keywords:** clubfoot, foot deformities, congenital, ponseti

### Introduction

Club foot, or talipes equinovarus, is a congenital deformity consisting of cavus, forefoot adduction, heel varus, ankle equinus and internal tibial torsion. The deformity was described as early as the time of Hippocrates. The term talipes is derived from latin *talus-ankle*, and *pes-foot* <sup>[1]</sup>. The term refers to the gait of severely affected patients, who walked on their ankles.

The goal of treatment is to correct all components of the deformity so that the patient has a pain-free plantigrade foot with good mobility, without calluses, and without the need to wear special or modified shoes. In 1889, L.H. Bradford has been quoted as saying. "The literature on the treatment of clubfoot is, as a general rule, that of unvarying success. It is often as brilliant as an advertising sheet and yet in practice there is no lack of half-cured or relapses cases, sufficient evidence that method of cure are not universally understood. "More than a hundred years on, these words, unfortunately, still ring true.

### Aim of the Study

To evaluate the outcome following treatment of idiopathic

club foot with Ponseti technique in children below two years of age coming to the orthopaedics OPD of Kerala Medical College & Hospital between October 2015 to October 2017.

### Materials and Methods

The study was executed in the out-patient department of Kerala Medical College with no extra funding resorted to whatsoever. The study confirmed to the guidelines of the declaration of Helsinki, 1964 revised in 1975.

### Inclusion Criteria

All children under 2 year having idiopathic congenital talipes equinovarus both unilateral and bilateral were included in the study.

### Exclusion Criteria

1. Children with clubfeet above the age of 2 year and children with any associated congenital anomalies were excluded from the study.
2. Recurrent and relapsed clubfeet consequent to failed surgical/ conservative treatment were also excluded.

### Details of Ponseti Technique<sup>[2]</sup>

Treatment is ideally started soon after birth by passive manipulations which are taught to the parents till casting is started after 7 – 10 days.

1. **First cast (reduce the cavus):** The first element of management is correction of the cavus deformity by positioning the forefoot in proper alignment with the hindfoot.
2. **Manipulation:** The manipulation consists of abduction of the foot beneath the stabilized talar head. Locate the head of the talus. All components of clubfoot deformity, except for the ankle equinus, are corrected simultaneously. To gain this correction, one must locate the head of the talus, which is the fulcrum for correction.
3. **Second, Third and Fourth Casts:** During this phase of treatment, the adductus and varus are corrected. The distance between the medial malleolus and the tuberosity of the navicular when palpated with the fingers tells the degree of correction of the navicular. When the clubfoot is corrected, that distance measures approximately 1.5 to 2cm and the navicular covers the anterior surface of the head of the talus. Similarly, the extent of the lateral displacement of the anterior tuberosity of the calcaneus under the head of the talus indicates the increase in value of the talo-calcaneal angle, and thus, the degree of correction of the heel varus.

### Equinus

The equinus deformity gradually improves with correction of adductus and varus. This is part of correction because the calcaneus dorsiflexes as it abducts under the talus. No direct attempt at the equinus correction is made until the heel varus is corrected. In very flexible feet, equinus may be corrected by additional casting without tenotomy. when in doubt, perform the tenotomy.

### Cast Application, Moulding and Removal

Success in ponseti management requires good casting technique. Those with previous club foot casting experience may find it easier than those learning clubfoot casting for the first time.

### End-Point

The endpoint was a score less than 1.5 with the feet having 70 degrees of external rotation and 15 degree of dorsiflexion. The parents were advised to preserve the plaster casts as they served as replica for assessing the correction

### Bracing Protocol

The brace is applied immediately after the last cast is removed, 3 weeks after tenotomy. The brace consists of open toe high-top straight last shoes attached to a bar. For unilateral cases, the brace is set at 60 to 70 degrees of external rotation on the clubfoot side and 30 to 40 degrees on the normal side. On bilateral cases, it is set at 70 degrees of external rotation on each side. The bar should be of sufficient length so that heels of the shoes are at shoulder width. A narrow brace is a common reason for lack of compliance. The bar should be bent 5 to 15 degrees with the convexity away from the child to hold the feet in dorsiflexion.

The brace should be worn full time (day and night) for the first 3 months after the last cast is removed. After that, the child should wear the brace for 12 hrs at night and 2 to 4 hrs in the middle of the day for a total of 14 to 16 hrs during each 24-hr period. This protocol continues until the child is 3 to 4 years of age.

### Follow-UP

After applying the brace for the first time when the last cast is removed the child returns according to the following suggested schedule

- 2 weeks to troubleshoot compliance issues
- 3 months to graduate to the nights- and – naps protocol
- Every 4 months until age 3years to monitor compliance and check for relapses
- Every 6 months until age 4 years
- Every 1 to 2 years until skeletal maturity

Once the child is above one year of age, he is put on clubfoot shoes. These characteristically are an ankle foot orthoses, with a straight medial border, lateral wedge, no heel and an ankle strap with a gap at the point of heel to monitor the correct dorsiflexed position of the ankle through the shoes. The Dennis brown splint is still worn at night for four hours. Whenever possible slight manipulations are done by parents.

### Pirani Severity Scoring

We have used the pirani severity scoring<sup>3</sup> developed by Catterall and Shafique pirani to evaluate the correction in an unoperated congenital clubfoot less than 2 year of age. This rating has proved its efficacy in having little inter and intra-observer variability. Documenting the amount of deformity allows the treating practitioner where he or she is with respect to the road map of treatment, to know when tenotomy is indicated, and to reassure parents regarding progress. It allows meaningful comparison of results, extractions of subgroups, etc.

Scores	clinical signs
0	normal
0.5	moderately normal
1	severely abnormal

Midfoot Score. Three signs comprise the midfoot score (MS), grading the amount of midfoot deformity between 0 and 3

1. Curved lateral border [A]
2. Medial crease [B]
3. Talar head coverage[C]

Hindfoot score. Three signs comprise the Hindfoot score (HS), grading the amount of Hindfoot deformity between 0 and 3

1. Posterior crease [D]
2. Rigid equines [E]
3. Empty heel [F]

### Results

There were altogether 30 patients with 44 feet included in the study. We evaluated the following variables.

- Age of the patient at first visit to our institution,
- Previous treatment and type of treatment before referral,
- Number of casts required at our institution,

- Need for percutaneous tendoachilles tenotomy and
- Compliance with the foot –abduction brace

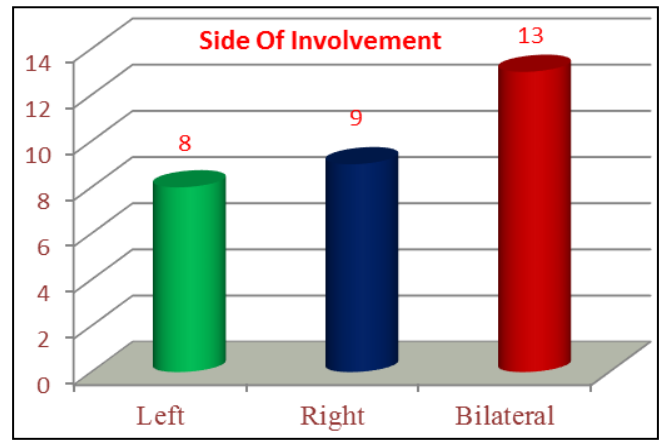
These variables were in turn related to the need for extensive corrective surgery and the incidence of relapses. Fisher exact tests, t tests, and odds ratio were used as appropriate.

**Biostatistics**

The following are the outstanding biostatistical data derived from the study.

- Male patients were 11 (37%) and female patients were 19 (63%)
- At initial ponseti casting, all patients were younger than 12 months of age. The initial pirani score ranged from 5 – 6 (Fig 1)
- The number of casts ranged from 6 - 8. All the patients had above-knee casts. Corrective surgery was recommended to 12 patients (40%).
- 17 patients had unilateral feet and thus unilateral feet exceeded bilateral feet in this study (Fig 2). Of the unilateral feet 9 were right and 8 left (Fig 3).

Throughout the course of plaster treatment special care was taken to counsel the parents regarding their role in watching for vascular and other plaster related complications.



**Fig 3:** Side of Involvement

**Results of Plaster Treatment**

Clubfoot correction was obtained in all patients. Fortunately no patient had too severe a deformity that evaded correction. The end- point of correction was defined to be achieved if the feet had a score less than 1.5 with full correction of equinus.

**Number of Casts**

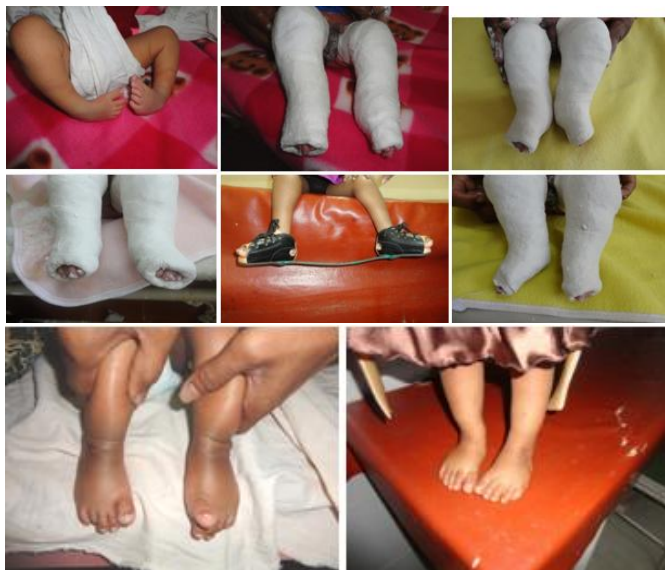Correction was obtained with 6-8 casts. 63% feet required 6 casts for correction. The last cast was usually left on for 2 weeks if a tendoachilles tenotomy was done. 13% feet required 8 casts for correction and this was indicated because of minor complications and the severity of the deformity. This corroborates with the world literature where ponseti’s method usually achieves plaster correction with 5 or 6 casts.

**Duration**

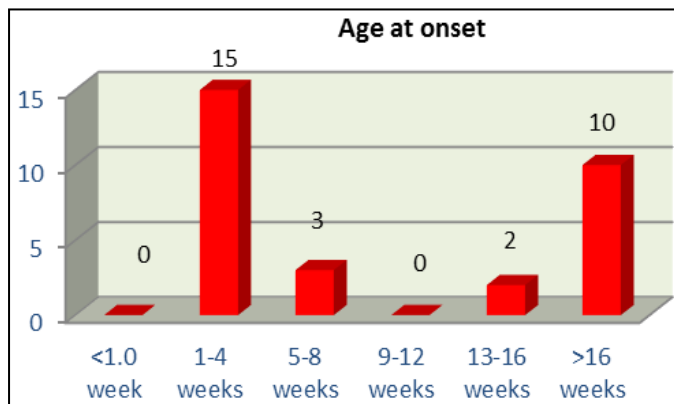
The average time from the first cast to the tendoachilles tenotomy/full correction of the deformity was 42 days.

**Percutaneous Tenotomy**

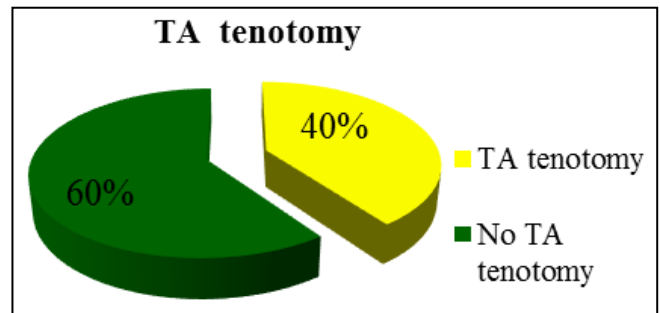
Percutaneous tendoachilles tenotomy was performed in 40% (12 feet) of the cases (Fig 4). We had a patient population less than 12 months of age with an average of less than 1 months and all the feet responded well to the technique protocol. Average posttenotomy ankle dorsiflexion was 15 degrees.



**Fig 1:** 2 Months old Child Initial Score - 6, final score - 0



**Fig 2:** Age Distribution



**Fig 4:** Ta Tenotomy

**Bracing**

The parent compliance with the bracing protocol was remarkable. They were sounded as to their role in maintaining the correction with proper fitting shoes and changing the shoe size as the feet grew.

### Follow-Up

A minimum follow-up of 12 months was possible with all the patients (Fig 5). The majority of patients started walking at the age of 16-18 months. 19 patients were followed up for 12 months and 11 patients upto 16-18 months within the time-span of the study. Strict concordance to the protocol for follow-up outlined by ponseti was maintained throughout the study. At each follow-up the feet were evaluated for any early sign of relapse if any.

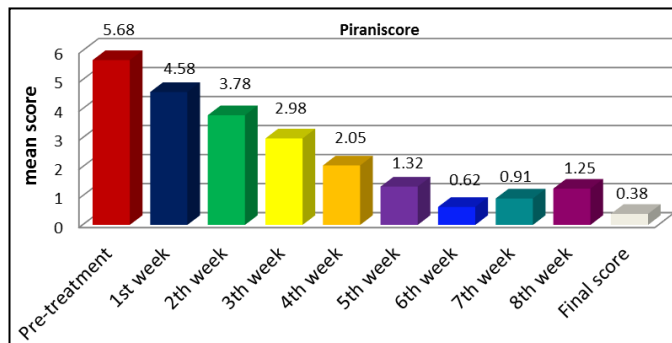


Fig 5: Pirani Score

### Results

Initial and final scores were statistically evaluated with paired ‘T’ test with a ‘T’ value of 36.76 with a ‘P’ value of less than 0.001 (Table 1). Thus there was a significant reduction in the score from the pre level because of intervention (Table 2).

Table 1: Paired T Test

	Mean	SD	t-value	df	p-value,result
Initial score	5.68	0.43	36.76	58	<0.001,HS
Final score	0.38	0.67			

Table 2: Progression of Score from Pre-Treatment to 8 Weeks - Cohort Analysis

Score	Min-Max	Mean ± SD	Difference from pretreatment	P value from pretreatment
Pre-treatment	5-6	5.68 ± 0.43	--	--
1st week	4-5.5	4.58 ± 0.46	0.5	<0.001,HS
2th week	3-4.5	3.78 ± 0.47	1.5	<0.001,HS
3th week	2.5-4	2.98 ± 0.48	2	<0.001,HS
4th week	1-3.5	2.05 ± 0.67	2.5	<0.001,HS
5th week	0.5-3.5	1.32 ± 0.8	2.5	<0.001,HS
6th week	0-3	0.62 ± 0.85	3	<0.001,HS
7th week	0-2.5	0.91 ± 0.89	3.5	<0.001,HS
8th week	0-2.5	1.25 ± 1.04	3.5	0.003,Sig
Final score	0-2.5	0.38 ± 0.67	3.5	<0.001,HS

### Failure

Two patients had an average final score of 2. The reason for failure in those patients could be attributed to defective casting technique.

### Complications

12 patients out of 30 had minor complications. All the complications were due to defective plastering technique and were unique to initial patients

### Relapse

A relapse is defined as the appearance of any of the components of the deformity, including cavus, adductus, varus, and/or equines. Relapses after initial correction are treated with additional manipulation and serial casting in marked foot abduction. A tendoachilles tenotomy [4, 5] is indicated when dorsiflexion of ankle is <15%. When the anterior tibial muscle tends to strongly supinate the foot during gait, its transfer to the third cuneiform will prevent additional relapses in most patients.

There were 3 relapses (4 feet) in our series as follows. All the three relapses were treated with re-manipulation and casting in the subsequent weeks and all responded to treatment. The one patient with equines relapse did not have a previous tenotomy and the same was performed this time. Until the last follow-up within the time span of the study no further relapses have been noted.

Relapse of the deformity was not significantly related to age at presentation, previous unsuccessful treatment at other institution or the no. of cast required for correction. All the relapses were due to slackening of the bracing protocol by patients.

### Final Result

Hence in this study, as there is only 2 patients out of 30 patients who had failure, ponseti’s method was a success [6, 7, 8]. In terms of number of patients the success rate is 93% (Table 3). This is in good agreement with the values in literature.

Table 3: Standard Deviation

	N	Mean	Std. Deviation	Minimum	Maximum
Pirani scoring_Baseline	30	5.68	0.43	5	6
Pirani scoring-Final	30	0.38	0.67	0	2.5

### Discussion

A conservative method of management of idiopathic CTEV has been recommended by most paediatric orthopedicians in the early days of infancy starting as early as possible after birth. There have been many conservative protocols of management for idiopathic CTEV deformity. Traditional<sup>9</sup>, Kite [10] and Ponseti [11] methods are among the commonly used protocol treatment methods. In the recent years the Ponseti method is the most advocated method of the conservative management of idiopathic CTEV deformity. Several studies have been conducted to prove its efficacy [12]. After serial manipulation and cast treatment the maintenance of correction is an important issue. Various foot abduction orthoses such as Dennis Brown splint [13], Stenbek Foot abduction orthoses and Dobb’s brace have been suggested as essential orthotic management for the prevention of recurrence. We, in our study evaluated the effectiveness of Ponseti casting as a mode of correction and maintenance of idiopathic CTEV deformity. There were altogether 30 patients with 44 feet included in the study. We evaluated the following variables. Age of the patient at first visit to our institution, Previous treatment and type of treatment before referral, Number of casts, Number of casts required at our institution,



Need for percutaneous tendoachilles tenotomy and Compliance with the foot –abduction brace. These variables were in turn related to the need for corrective surgery and the incidence of relapses. Fisher exact tests, t tests, and odds ratio were used as appropriate.

The following are the outstanding bio statistical data derived from the study. A total of 26 (83 percent) patients were male, Kite in his series of 1509 cases has reported 70% males and 30% females <sup>[14]</sup>. In Turco's <sup>[15]</sup> series of 468 patients there were 334 (71.36%) males and 134(28.63%) females a sex ratio of 2.5:1; Male: Female.

16 patients had unilateral feet and thus unilateral feet exceeded bilateral feet in this study. Of the unilateral feet 9 were right and 7 left, Chung <sup>[16]</sup> observed a 50% bilaterality 30 Turco's series of 468 pts. Had 56% bilateral, 22% rt and 21% Lt side involvement. At initial ponseti casting, all patients were younger than 12 months of age. The initial ponseti score ranged from 5 – 6. A total of 20 patients had some form of treatment before their initial visit to our institution. All the twenty had serial manipulation and casting done elsewhere. The number of casts ranged from 2 – 10. Stephen MD has reported an average of 2.5 months of treatment in his series of 37 pts. Fifty percent of these patients had below –knee casts and the rest had above-knee casts. All came to our clinic with all of the components of the deformity uncorrected. Throughout the course of plaster treatment special care was taken to counsel the parents regarding their role in watching for vascular and other plaster related complications. This counseling was effective and on several occasions the parents had contacted over phone from distant places and adequate advice could be given.

### Conclusion

- It can be rightly concluded from our study that Ponseti's method is a patient friendly and economically compliant method of easy and early correction of the club foot deformity. It is based on a strong scientific understanding of what the deformity is due to and what it is made up of.
- The results of our study closely match that available in literature which is an evidence of reproducibility of the correction irrespective of individual variations. All that is required is adherence to the basic principles outlined by the founder of the method.
- There is a limited but important learning curve for perfecting the method which is crucial to pass through to avoid basic errors as outlined by Ponseti as committable and preventable. These errors invariably lead to failure.

### References

1. Ponseti. Ponseti IV. Treatment of congenital clubfoot. J Bone Joint Surg. 1992; 74A:448.
2. Ponseti IV. Treatment of congenital clubfoot. J Bone Joint Surg Am. 1992; 74:448-454.
3. Pirani, Pirani S, Outerbridge H, Moran M, *et al.* A method of evaluating the virgin clubfoot with substantial interobserver reliability. Presented at the annual meeting of the Pediatric Orthopaedic Society of North America, Miami, Fla, 1995.
4. Tarraf IN, Carrot NC, Analysis of the components of residual deformity in clubfeet presenting for reoperation. J

- Paediatr Orthop. 1992; 12:207-216.
5. Caroll NC, Mc Murtky R, Leete SF. The pathoanatomy of congenital clubfoot orthopedic clinics of North America. 1995; 9:2255.
6. Vesely DC. A method of application of a clubfoot cast. Clin Orthop. 1972; 84:47-49.
7. Karski T, Wogko I. Experience in the conservative treatment of congenital clubfoot in newborns and infants. J Pediatr Orthop. 1989; 9:134-136.
8. Colburn M, Williams M. Evaluation of the treatment of idiopathic clubfoot by using the Ponseti method. J Foot Ankle Surg. 2003; 42(5):259-67.
9. Herzenberg JE, Radler C, Bor N. Ponseti versus traditional methods of casting for idiopathic clubfoot J Pediatric Orthop B. 2003; 12:133-140.
10. Kite JH. The clubfoot. London: William (Heinmann) Medical Books Ltd, 1964.
11. Dobbs MB, Morcuende JA, Gurnett CA, Ponseti IV. Treatment of idiopathic clubfoot: an historical review. Iowa Ortho pJ. 2000; 20:59-64.
12. Staheli Clubfoot L. Ponseti management 3<sup>rd</sup> ed, Seattle, Washington: Global Help Publications, 2009.
13. Hattori T, Ono Y, Kitakoji T, Iwata H. Effect of the Dennis Browne splint in conservative treatment of congenital clubfoot J Pediatric Orthop B. 2003; 12:59-62.
14. Kite JH Principles in the treatment of congenital clubfoot J. Bone Joint Surgery. 1939; 21:595-606.
15. Turco VJ. Resistant congenital clubfoot American Academy of Orthopedic Surgeons Instructional Course Lectures, St Louis the CV Mosby Co. 1975; 24.
16. Chung CS, Nemechek RW, Larsen IJ, Chung GHS. Genetic and epidemiological studies of clubfoot in Hawaii Human Heredity. 1969; 19:321.