

Skeletal abnormalities induced by antimalarial drug alpha/beta artether on developing chick embryo

¹Lavlesh Kumar Mittal, ²Vishram Singh, ³Ashoka RK, ⁴Garg AK, ⁵Sushma Tomar, ⁶Abhibhushan Mishra, ⁷Ghazal Mittal

¹Ph.D. scholar, Santosh University Ghaziabad U.P. India.

²Professor, Department of Anatomy, Santosh medical College, Ghaziabad, Uttar Pradesh, India.

³Professor, Department of Anatomy, Gold Field Institute of Medical Sciences & Research, Chhainsa, Ballabgarh, Haryana, India.

⁴Professor, Department of Anatomy, Divya Jyoti Institute of Medical Sciences, Modi Nagar U.P. India.

⁵Assistant professor, Department of Anatomy, Gold Field Institute of Medical Sciences & Research, Ballabgarh, Haryana, India.

⁶Demonstrator, Department of Anatomy, Gold Field Institute of Medical Science & Research, Ballabgarh, Haryana, India.

⁷Student B.Tech & M.Tech (Dual degree programme) (Biotechnology), School of Biotechnology, Gautam Buddha University
Greater Noida, Gautam Buddha Nagar U.P., India.

Abstract

Since a long time chick embryo is proving a satisfactory animal for embryological research work due to several advantages as eggs of chick are large in size, can be incubated artificially and are easy to control. Malaria a febrile infection caused by protozoa Plasmodium and spread by female anopheles mosquito still continues to be one of the India's leading public health problem. In the south-east Asia approximately 1.2 billion population are presented to the danger of malaria and majority of whom live in India. α/β artether is one of the most common antimalarial drug used worldwide to treat chloroquine resistant malaria and malaria falciparum. The present study was designed to assess the effects of α/β artether on developing chick embryo. The study was conducted in the Department of Anatomy, Santosh Medical College, Santosh Nagar, Ghaziabad U.P. in association with. Department of Anatomy, Gold Field Institute of Medical Sciences And Research, village Chhainsa, Ballabgarh, Faridabad, Haryana. The study was performed on 300 fertilized eggs of white leg horn chicken. The eggs were divided in to five experimental groups A, B, C, D, E having 50 eggs each and five control groups a, b, c, d, e one each for every control group respectively and having 10 eggs each. On 5th day of incubation eggs from experimental groups A, B, C, D and E were exposed to α/β artether with doses of 0.12mg, 0.24mg, 0.36 mg, 0.48mg and 0.60mg in volume of 0.04ml, 0.08ml, 0.12ml, 0.16ml, and 0.20ml respectively. Whereas the control groups were treated with same amount of normal saline. On 20th day of incubation the eggs were broken and embryos were removed. The results showed growth retardation and some significant morphological and skeletal abnormalities.

Keywords: Artemisinins, α/β artether, Teratogenicity, Lordosis, Scoliosis, Kyphosis.

1. Introduction

The only method of attaining a comprehensive understanding of embryological processes is through the study and comparison of development in various animals and the chick is one of the most satisfactory animal on which embryological laboratory work may be based [1]. The traditional strength of chicken embryos for studying development is that they are easily manipulated and this character of the chicken has led to some major discoveries in embryological science [2]. Malaria a febrile illness spread through mosquito continues to be one of the world's leading public health problem. In India malaria imposes incredible socio-economic burden on humankind and with six other diseases like diarrhea, HIV/AIDS, tuberculosis, measles, hepatitis B and pneumonia represent 85% of Global infectious disease burden [3]. In the south-east Asian locality of WHO, out of 1.4 billion individuals living in 11 countries, approximately 1.2 billion are presented to the danger of malaria and majority of whom live in India. India reports approximately two million cases and 1000 deaths attributable to malaria yearly [4].

Artemisinin is a concentrate of artemisia plant found in china also called as Qinghaosu, and its subordinates (α/β artether, artesunate, artemether and Di-hydro artemisinin etc). Are a group of drugs that have the most rapid action of all current drugs against *Plasmodium falciparum*.

2. Materials and method

2.1 Materials used

Eggs of *Gallus Gallus domesticus* (white leg horn chicken), candle box, antimalarial drug α/β artether, disposable tuberculin syringes, distill water, spirit lamp, wax, Incubator with humidifier, measuring tape, electronic weighing machine, Vernier caliper and magnifying glass.

2.2. Methodology

Inclusion Criteria

- Proper calcified eggs with intact shell.
- Eggs having air cell at broader end.
- Egg's having air cell without any blood clot.

Exclusion Criteria

- Eggs with cracked shell due to improper calcification.
- Eggs not having air cell at broader end.
- Eggs having blood clot in air cell.

The present study was designed to assess the effects of α/β artether, an antimalarial drug on developing chick embryo in 300 eggs of white leg horn chicken. The study was conducted in the Department of Anatomy, Santosh Medical College, Santosh Nagar, Ghaziabad U.P. in association with department of Anatomy, Gold Field Institute of Medical Sciences And Research, Chhainsa, Ballabgarh, Faridabad, Haryana. The eggs were obtained from Metro Feeds, Agro Products, village Dabua, Dabua Pali road, Faridabad.

The method was adopted as adopted by P.E. Natekar (2007) [5], Ritu Singroha *et al* (2012) [6] Sywicha Thongphanich and Jantima Roongruangchai (2013) [7] and Muktyaz Hussain *et al* (2014) [8]. The eggs were candled in order to exclude defective ones and to mark outline the exact location of air cell with a pencil. For this purpose a specially made wooden box was procured. This box had a connection for an electric bulb and was painted black from inside. The slots for the chicken eggs made on the top. The weight of selected eggs were found between 33.30 grams to 48.15 grams (average 40 gm). Before starting the study 10 fertilized eggs of white leg horn chicken were developed in incubator without normal saline or distilled water or any drug. On 20th day of incubation eggs were sacrificed and chick embryos were obtained. Their weight by electronic machine and CR length by thread and centimeter scale were measured. The minimum weight of embryo 17.98 gram, maximum weight 27.98 gram and minimum crown rump length 4.90 cm. maximum crown rump length 6.70 cm. were noted. The weight and crown rump length of embryos same and between minimum and maximum measurement were considered as normal.

The selected eggs were thoroughly washed with soap water solution and put in incubator with their broad end up where chorioallantoic membrane is situated. The temperature and humidity inside the incubator were maintained at 38^oc and 80% respectively with no additional CO₂ or O₂. The eggs were tilted two times a day. On the 5th day of incubation eggs were removed from incubator and candled again prior to administration of drug.

2.3. Drug- α/β artether

- Availability : Injection E- Mal – α/β artether 150 mg / 2ml
- Name of the manufacturer : Themis Medicare
- Recommended dose : 150 mg by intramuscular route for 3 consecutive days (Adults)
: 3 mg / kg of body weight by intramuscular route for 3 consecutive days (Children)

2.4. Dose Titration

- 1 Kg body weight (1000 gm) requires = 3 mg
- 40 gm body weight requires = 3 X 40 / 1000 = 0.12 mg
- Solution was made by-2ml α/β artether + 48 ml distilled water = 50 ml.

- 150 mg α/β artether is present in = 50 ml solution
- 0.12 mg α/β artether is present in = 50 x .12 / 150 = .04 ml

2.5. Method for drug administration

Eggs were divided into five experimental groups A, B, C, D, E having 50 eggs each and five control group a, b, c, d, e for each test group respectively having 10 eggs each. Experimental groups A, B, C, D, E were exposed to α/β artether with dose of 0.12mg, 0.24mg, 0.36mg, 0.48mg and 0.60mg in a volume of 0.04ml, 0.08ml, 0.12ml, 0.16ml, and 0.20ml and control groups were treated with same volume of normal saline. The solution was taken in a tuberculin syringe. The broad end of eggs were wiped with sterile gauze pad moistened with 70% isopropyl alcohol solution. A hole was drilled in egg shells in the center of surface over the air cell with a lancet. It was taken care not to damage the shell membranes with point of drill. The needle of the tuberculin syringe filled with injectable solution was inserted horizontally into the air cell and the solution was injected. The needle of the syringe was sterilized after wiping with sterile 70% isopropyl alcohol swab between each injection. The hole of the shell was sealed with candle melted wax immediately after injection. After the injection sealed eggs were kept again into incubator at 38 ^oC and 70% to 80% humidity and tilted two times a day. On the 20th day of incubation eggs were removed from the incubator and sacrificed. The egg shells were broken with a scalpel and the embryos were removed.

2.6. Staining of skeleton

20th day old chick embryos were washed with tap water and eviscerated and processed through cartilage and bone double staining method described by McLeod [9] with little modifications. The embryos were fixed in absolute ethyl alcohol for 7 days. After fixation embryos were stained for 4 days in a solution prepared by (a) 1 volume of 0.1% Alizarin-red-s in absolute ethyl alcohol (b) 1 volume of glacial acetic acid and (c) 1 volume of absolute ethyl alcohol. To make sure proper and uniform staining 100 ml solution was used for each skeleton in a separate jar and avoid overlapping of one part body to another. After staining the embryos were washed with tap water and placed in 2% KOH solution for 48 hours. Macerated stained embryos were passed up through the increasing concentration of glycerin as 20%, 40%, 60%, 80% and then ultimately stored in pure glycerin with some thymol crystals to avoid mold proliferation. Photographs were taken in photographic laboratory of the department.

3. Observation

Number of dead and alive embryos were noted and percentage of lethal effects given in table no. 1. Morphological abnormalities were the teratogenic effects of antimalarial drug α/β artether on skeleton of developing chick embryo were analyzed and compared with control groups with necked eyes and magnifying glass.

3.1. Axial Skeleton

3.1(a). Skull

Retarded ossification of skull bones was found in 8% chick embryos belong to experimental group A, 12% to experimental group B, 10% to control group c, 36% to

experimental group C, 10% to control group d, 14% to experimental group D, 10% to control group e and 22% to experimental group E. Short mandible were found in 2% embryos belong to experimental group E.

3.1(b). Vertebral column

In 2% chick embryos obtained from experimental group A, 14% from experimental group B, 10% from control group c, 18% from experimental group C, 10% from control group d, 20% from experimental group D, 20% from control group e and 40% from experimental group E poor ossification of vertebrae was found whereas displacement of the vertebrae was found in 2% chick embryos obtained from experimental group D and experimental group E. During the observation of curvatures of spine the 14% chick embryos obtained from experimental group C, 4% from experimental group D and 8% from experimental group E were found suffering from Scoliosis whereas 4% from experimental group B, 2% from experimental group C, 4% from experimental group D and 4% from experimental group E were found suffering from Lordosis and 4% from experimental group C, 2% from experimental group D and 4% from experimental group E were found suffering from Kyphosis.

3.1(c). Ribs

The incomplete or poorly ossification of the ribs was found in chick embryos obtained from all control as well as experimental groups as from control group a (10%) and experimental group A (14%), from control group b (10%) and experimental group B (14%), from control group c (10%) and experimental group C (36%), from control group d (20%) and experimental group D (24%) and from control group e (20%) and experimental group E (40%). In the chick embryos belong to 6% from experimental group B, 6% from experimental group C, 6% from experimental group D, 10% from control group e and 40% from experimental group E, the displacement of the ribs was found. While 4% chick embryos obtained from experimental group E were found having Synostosis.

3.1(d). Sternum

In the chick embryos obtained 4% from experimental group A, 10% from experimental group B, 10% from control group c, 28% from experimental group C, 28% from experimental group D and 32% from experimental group E the sternum is found poorly ossified.

3.2. Appendicular Skeleton

3.2(a). Thoracic Limb

In the skeleton of thoracic limb no abnormality was found in the chick embryos belong to control groups a while radius in 4%, ulna in 4%, metacarpals in 6% and phalanges in 10% were found poorly ossified in embryos belong to experimental group A. In 10% chick embryos obtained from control group b poorly ossification of radius and metacarpals was found whereas humerus in 2%, metacarpals in 5% and phalanges in 10% chick embryos obtained from experimental group B were found poorly ossified. There was no abnormality found in the chick embryos belong to control group c but poor ossification was seen in humerus in 24%, ulna in 20%, metacarpals in 24% and phalanges in 20% chick embryos obtained from experimental group C. Poorly ossification of humerus in 10%, ulna in 10%, metacarpals in 20% and phalanges in 10% was

seen in embryos found from control group d while humerus in 14%, ulna in 20%, metacarpals in 22% and phalanges in 28% were found poorly ossified in embryos belong to experimental group D. In association with poor ossification of the bones in 6% chick embryos obtain from experimental group D metacarpals and phalanges were found little bit bended. In 10% embryos from control group e were found poor ossification of humerus, ulna and metacarpals each while humerus in 14%, ulna in 20%, metacarpals in 22% and phalanges in 28% embryos obtain from experimental group E were found poorly ossified. Radius in 8%, ulna in 8% and phalanges in 12% found shortened and metacarpals in 14% and phalanges in 12% found bended in the chick embryos belong to experimental group E.

3.2(b). Pelvic limb

The abnormalities in the skeleton of pelvic limb of chick embryos were found as follows– The poor ossification of metatarsals in 10%, phalanges in 10% in control group a was found. In the chick embryos pelvis in 12%, femur in 10%, fibula in 8%, metatarsals in 14% and phalanges in 14% in experimental group A, pelvis in 10%, fibula in 10%, metatarsals in 10% and phalanges in 10% in control group b, pelvis in 10% femur in 10%, tibia in 14%, fibula in 12%, metatarsals in 28% and phalanges in 26% in experimental group B, pelvis in 10% in control group c, pelvis in 16%, femur in 10%, tibia in 14%, fibula in 12%, metatarsals in 28% and phalanges in 26% in experimental group C, pelvis in 10% femur in 10%, metatarsals in 20% and phalanges in 10% in control group d, pelvis in 14%, femur in 16%, tibia in 16%, fibula in 26% metatarsals in 36% and phalanges in 38% in experimental group D, fibula in 10% in control group e and pelvis in 32%, femur in 24%, tibia in 24%, fibula in 22%, metatarsals in 36% and phalanges in 42%. metatarsals in 10% and phalanges in 10% in control group a, metatarsals in 10% and phalanges in 12% in experimental group A, pelvis in 2%, femur in 2%, tibia in 2%, fibula in 2%, metatarsals is 6% and phalanges in 8% in experimental group B, pelvis in 4%, femur in 6%, tibia in 4% fibula in 8% metatarsals in 16% and phalanges in 20% in experimental group C, pelvis in 10%, femur in 10%, metatarsals in 20% and phalanges in 10% in control group D, pelvis in 14%, femur in 16%, tibia in 16%, fibula in 26%, metatarsals in 36% and phalanges in 38% in experimental group D, fibula in 10% in control group e and pelvis in 32%, femur in 24%, tibia in 24% fibula in 22% metatarsals in 36% and phalanges in 42% in experimental group E poor ossification was found

The metatarsals and phalanges 10% each in control group a, Metatarsals in 10% and phalanges in 12% in experimental group A, Pelvis in 2%, femur in 2%, fibula in 2%, metatarsals in 6% and phalanges in 8% in experimental group B, 20% metatarsals in control group d, pelvis in 4%, femur in 2%, tibia in 2%, metatarsals in 8% and phalanges in 14% in experimental group D, pelvis in 10% in control group E and pelvis in 18%, femur in 18%, tibia in 14%, fibula in 8%, metatarsals in 6% and phalanges in 6% in experimental group E chick embryos were found bended or displaced from their natural place.

Pelvis in 2%, fibula in 8%, metatarsals in 12% and phalanges in 12% in experimental group C, pelvis in 4%, femur in 2%, tibia in 4%, fibula in 4%, metatarsals in 18% and phalanges in 20% in experimental group D, pelvis in 12% femur in 16%,

tibia in 8%, fibula in 14%, metatarsals in 24% and phalanges in 26% chick embryos were found a little bit shortened. Apart of these abnormal findings femur in experimental group C and pelvis and femur in experimental group D and experimental group E were found thin.

4. Tables and Figures

Table1: Showing lethal effects induced by α/β artether in developing chick embryo

Name of the groups	No. of fertile eggs used	No. of dead embryos	No. of live embryos	Percentile lethality
a	10	00	10	0%
A	50	02	48	4%
b	10	01	09	10%
B	50	07	43	14%
c	10	03	07	30%
C	50	10	40	20%
d	10	03	07	30%
D	50	11	39	22%
e	10	03	06	30%
E	50	17	33	34%

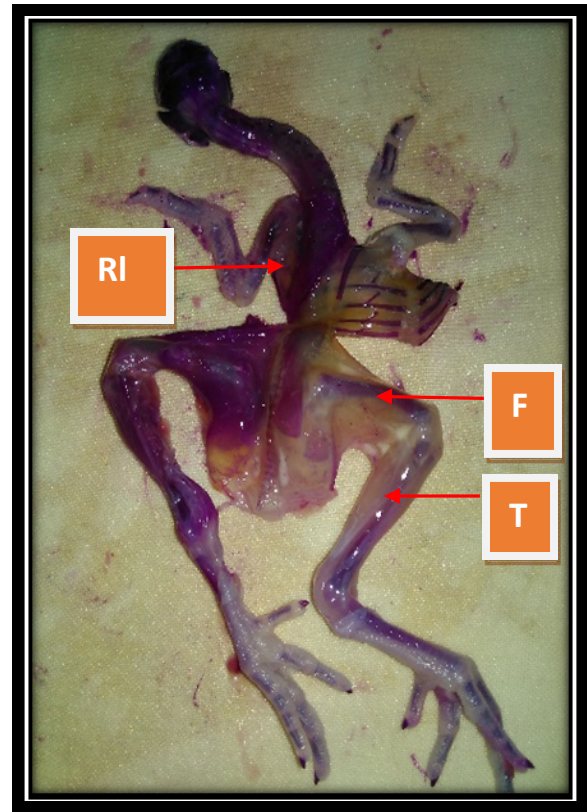


Fig 2: Poorly ossified and thin femur (F) and poorly ossified tibia (T) of right side, and under developed ribs(RI) of left side

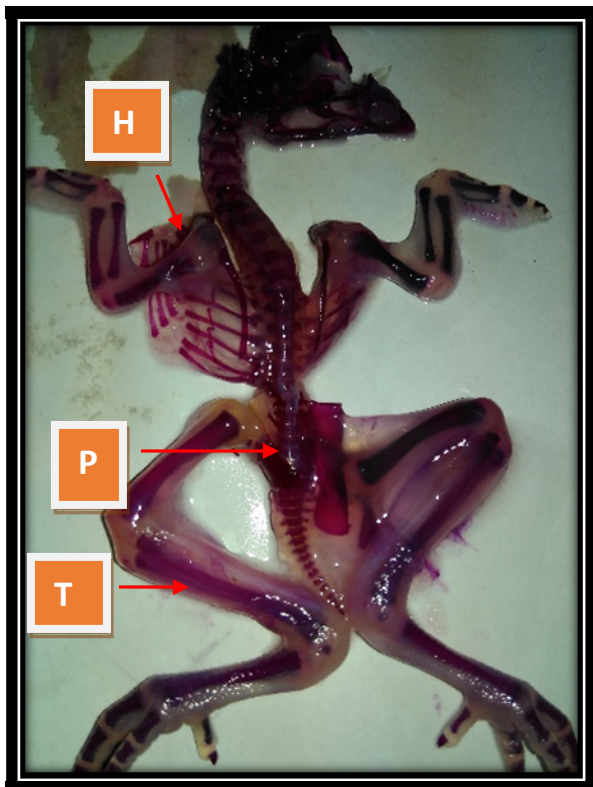


Fig 1: Poor ossification of pelvis (P), humerus (H) and tibia (T) of left side

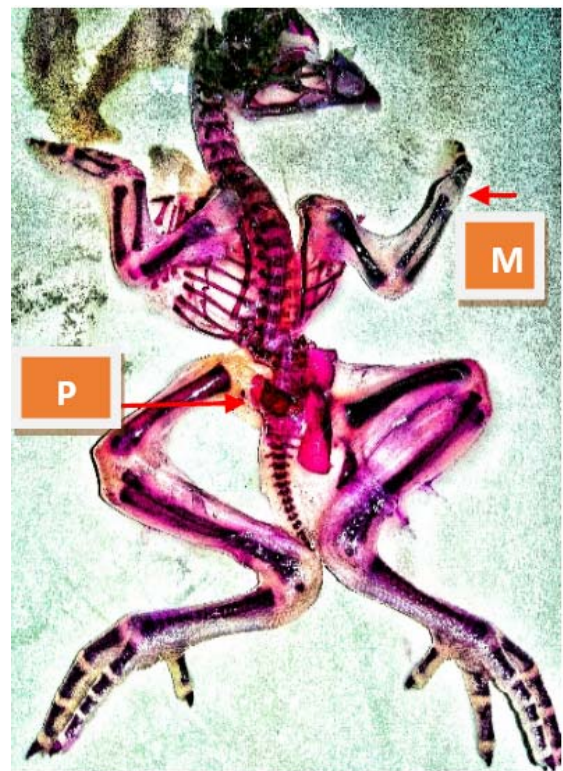


Fig 3: Poor ossification of Metacarpals (M) of right side and pelvis (P) of left side

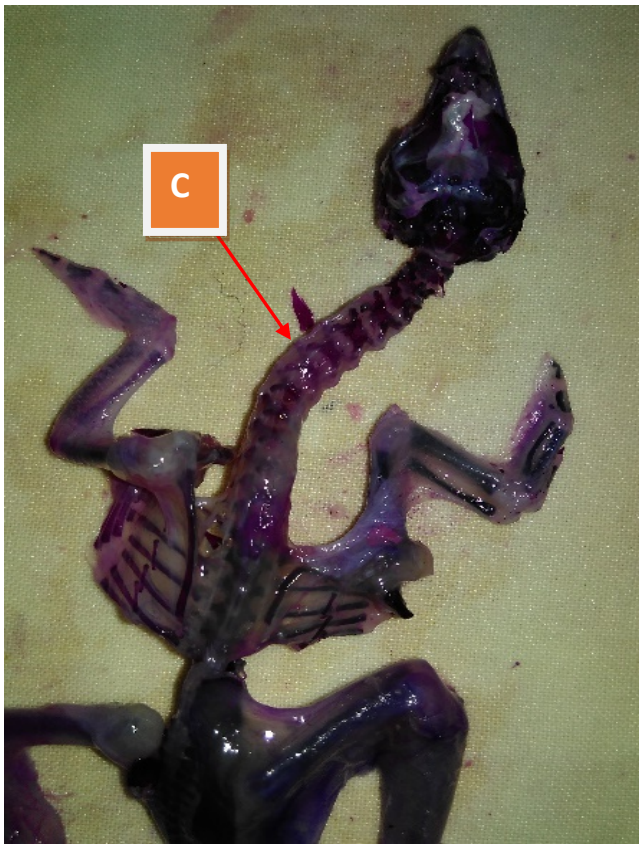

Fig 4: Poor ossification of cervical vertebrae (C)

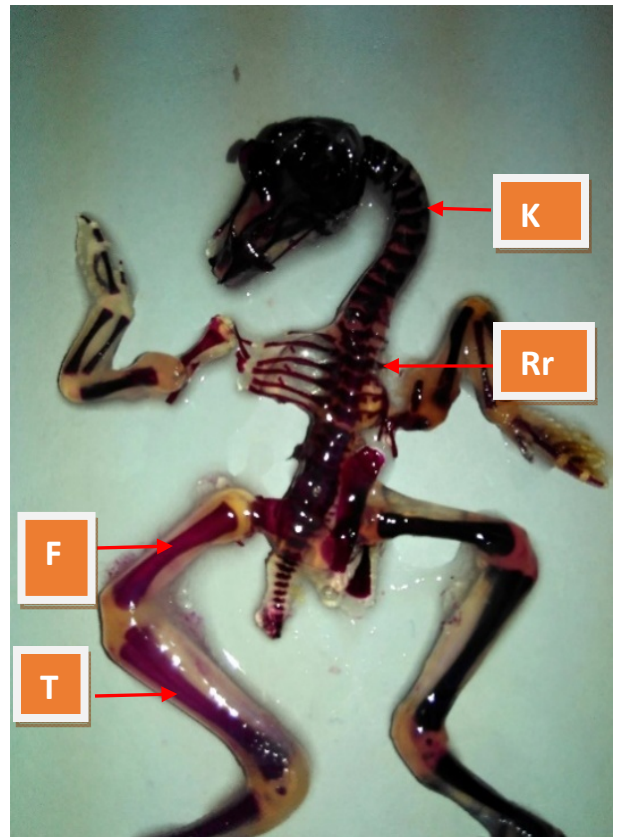


Fig 6: Kyphosis (K), poorly ossified ribs of right side (Rr) and femur (F) and tibia (T) of left side

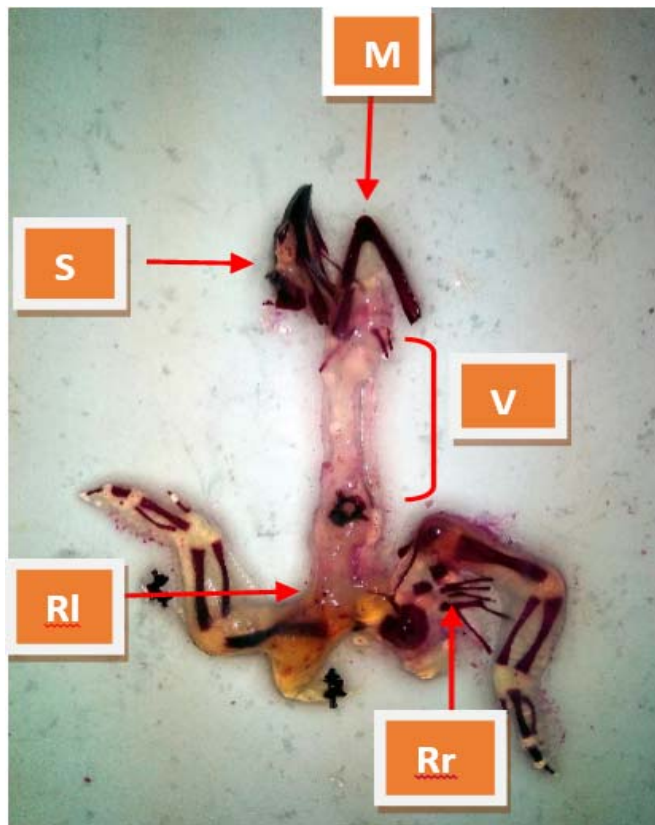


Fig 5: Short mandible (M), poorly developed skull bones (S), vertebral column (V) and ribs of left side (RI) and poorly ossified and displaced ribs of right side (Rr) and undeveloped pelvic limbs

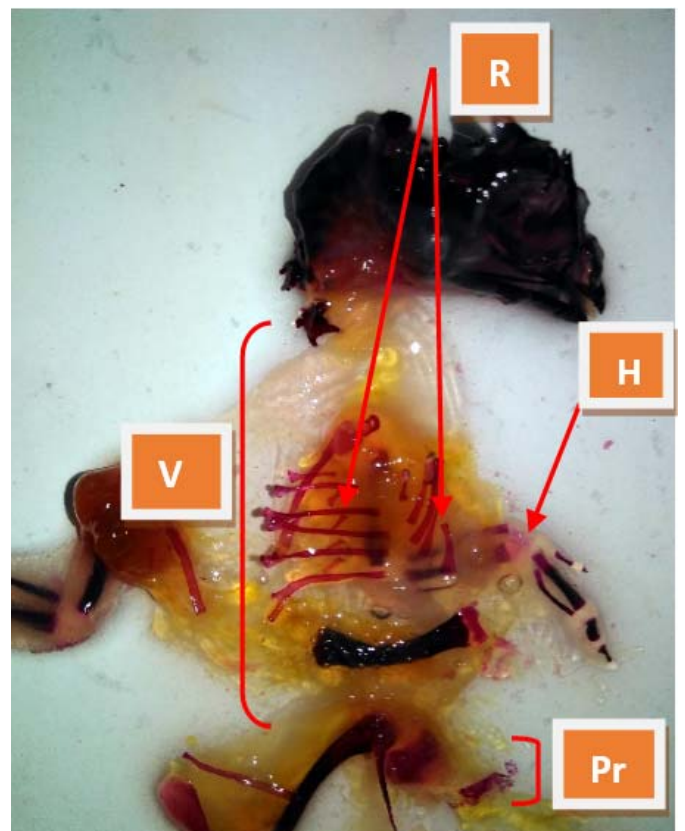


Fig 7: Poorly developed vertebral column (V), humerus (H) of right side and right pelvic limb (Pr) with poorly ossified and displaced ribs (R) of both side

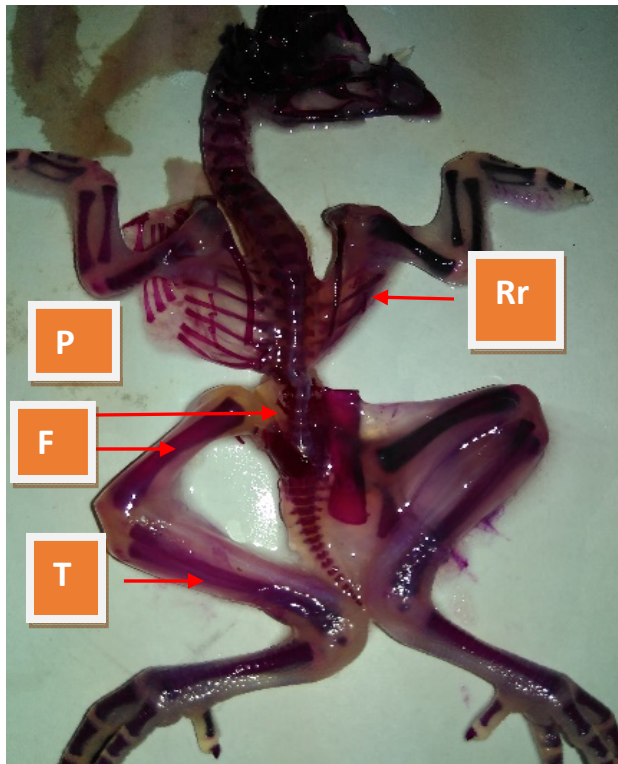


Fig 8: Poorly developed ribs (Rr) of right side and pelvis (P), femur (F) and tibia (T) of left side



Fig 9: Scoliosis (S)

5. Discussion

Teratogenic mechanism covers the series of events that occur from the movement a teratogen exerts its influence on the tissues of developing chick embryos to the final results of malformations either structural or functional. The initial event in teratogenesis may be brought about by a teratogen by its own or by its metabolites and the influence being exerted (a) on an organ primordium which will be malformed later or (b) on the embryonic tissues other than the one going to be malformed or (c) the maternal tissue or placenta. A review of teratological studies shows that a large number of factors initiate the abnormal development at cellular or sub cellular levels like genetic mutation, chromosomal aberration, mitotic interference, altered nucleic acid integrity or function, lack of precursors and substrates etc., altered energy sources, enzyme inhibition, fluid osmolytes imbalance and changed membrane characteristics ^[10] morphogenesis and tissue interaction ^[11] may take place between two or more tissues of different properties (heterotype) or between like cells (homotype) ^[12] and these are concerned as the central control mechanism for differentiation and morphogenesis.

Many cytotoxic agents at lower doses inhibit proliferative activity and result in reduced cell number, which play a central role in most malformations and teratogenesis. Sequential events in this process are inhibition of RNA synthesis and reduction of mucopolysaccharides, hydroxyproline ^[13] and phospholipid contents in the palatell shelves ^[14]. Reduced proliferative rates has resulted in a lot of studies with cyclophosphamide ^[15], hypervitaminosis A, aminocentesis ^[15] and chlorpromazine ^[16].

Multiple teratological investigations reveal that physical or chemical insult produces cell necrosis in tissues destined to be malformed within a few hours or days ^[17]. It has found that higher doses cause cell death and teratogenesis and at lower kill the cell at a lower rate but May not produce malformations. There are varied responses to cytotoxic agents from cell to cell. This might be due to many reasons. Most important is intrinsic cell difference which determines whether the cell will die or not. With 6 aminonicotinamide, a severe vacuolation was found in ectodermal cells but not in mesodermal or endodermal derivatives ^[18]. The sensitivity of the cells depend on the nutritional state, which is carried out by diffusion. Cells farthest from nutritional source are affected most. There are abundant evidences that insecticides produce their acute toxic actions by inhibiting acetylcholinesterase ^[19]. In the present study α/β artether in different doses effects embryonic chick development as indicated by the conditions such as lethality, growth retardation, and poor ossification of bones. So many defects indicate the probable involvement of more than one biochemical lesion or mode of action. The observation on poor ossification of skeleton could be due to the impairment of chondrochondroitin sulfate, possibly through interference with an NAD dependent process ^[20]. The inhibition of yolk sac membrane K-phase activity has been directly correlated with the lowering of the embryo NAD level and teratogenic signs ^[21]. This may be result of nutritional deficiencies, due to the failure of the embryo to receive some esters-metabolized products from the yolk sac ^[22]. The vertebral defects (lordosis) are attributable to acetylcholinesterase inhibition ^[23-26] and associated disruption of the cholinergic system ^[27-29]. α/β artether has a long plasma life and narrow safety range. Therefore adding similar drug

halfway through the treatment only add to the adverse effects and not to the therapeutic benefit. It should not misuse the newer antimalarial drug α/β artether and need to preserve it for future. Research into α/β artether is scanty and the parasite is fast developing resistance even for α/β artether. Depletion of artemisinins by misusing them may have nothing left for treating all drug resistant malaria in nearly coming future. Therefore α/β artether, the drug of choice for the treatment for chloroquine resistant malaria and life threatening malaria falciparum should be used only when definitely indicated and not discriminately. α/β artether should be used only when parasite index or other methods prove drug resistant malaria. In addition α/β artether (artemisinins) can be used in cases of hyperparasitemia or life threatening complications on account of their ability to clear the parasitemia to other antimalarial drugs. Infection with plasmodium falciparum and chloroquine resistant plasmodium Vivax is dangerous so effective and safe treatment is required. At present α/β artether is drug of choice for the treatment of Malaria falciparum and chloroquine resistant malaria Vivax because no other drug is available for the same. Due to non-availability of any other drug and more over due to insufficient qualified health infrastructure in hugely populated India α/β Artether and other drugs of its group are being using very frequently resultant α/β artether resistance malaria cases are started to report. Under the circumstances people are helpless to take α/β artether in higher dose or for a long period for the treatment of malaria falciparum. The role of α/β artether is controversial in many previous studies. In a study α/β artether and other drugs of its group were found embryo fetal and angiogenesis inhibitor in rats [10]. By using artemisinin combination therapy during 1st trimester in 685 pregnant Senegal found 2.6% stillbirth, 2.8% miscarriages and in 1.6% major congenital malformations were identified [11]. In previous animal experiments there are clear evidence of death of embryos and some evidence of gross anatomical abnormalities [9] by using α/β artether and drugs of its group.

There are so many research fellows [30-31] who worked on teratogenic effects of α/β artether and other drugs of its group with respect to pregnancy and concluded toxic in early pregnancy and safe in 2nd and 3rd trimester but as far as teratogenic effects of higher dose of same drug is concern the data is very much insufficient almost negligible. In present study the percentage of lethality (mortality) and retarded ossification of skeleton in experimental groups is significant and indirectly implies the growth of the embryos.

6. Conclusion

In present study increased mortality percentage and adverse effects on growth retardation, poor ossification, alteration in curvature of vertebral column etc. Due to higher dose of the α/β artether drug warn to stop misuse of the drug and require more work to do until or unless availability of another effective drug against chloroquine resistant malaria and malaria falciparum.

7. References

1. The chick embryo past, present and future as a Yuji model system in developmental Biology, Elsevier Ireland limited, Mechanism of development 2004; 121:1011-1013.

2. Kotpal RL. Modern Text Book of Zoology; 3rd Edition 2013; page no.651-662.
3. Estimation of True Malaria Burden in India. A profile of National Institute of Malaria Research, Page no.91-99.
4. National Vector Borne Disease Control Programme. Directorate General of Health Services, Ministry of Health & Family Welfare Govt. of India, 2014.
5. Natekar PE. Methotrexate Induced Gross Malformations in Chick Embryos J. Hum. Ecol. 2007; 21(3):223-226.
6. Ritu Singroha, Srivastava SK, Pankaj Chhikara. Effect of Gentamicin on kidneys in developing chicks, Eur. J Anat. 2012; 16(2):119-126.
7. Suwicha Thongphanich, Jantima Roongruangchai. The effects of Alphacypermethrin Pesticide on the development of in ovo Gallus domesticus, the 29th National Graduate Research Conference, Mae Fah Luang University, 2013.
8. Muktyaz Hussein, Vishram Singh, Prerna Gupta, Birendra Yadav, Singh AK. Developmetal and Biochemical Effects of Imidacloprid on Developing Chick Embryos; JASI. 2014; 22(2):12.
9. McLeod MJ. Differential staining of cartilage and bone in whole mouse fetuses by Alcian blue and Alizarin red S, Teratology, 1980; 22:299-301.
10. Wilson JG, Environmental in Wilson JG, and Fraser FC (eds). Hand Book of Teratology, General Principles and etiology, Plenum press. New York, 1977; 1:357-85.
11. Grobstein C. Inductive tissue interaction in the development. Advances in cancer Research. 1956; 4:187-236.
12. Moscona AA, Garber BB. Reconstruction of skin from single cell and integumental differentiation in cell aggregates: in epithelial mesenchymal interactions (Fleischmajer R, Billingham RE eds) Williams and Wilkins: Baltimore, 1968; PP. 230-243.
13. Shapira Y, Shoshan S. The effects of cortisone on collagen synthesis in the secondary plate of mice; Arch Oral Biol. 1972; 17:1699-1703.
14. Stepanovich V, Gianelly A. Preliminary studies of lipids of normal and cleft palates of the rat. J. Dent Res. 1971; 50:1360.
15. Singh S, Mathur MM, Singh G. Congenital abnormalities in rat fetuses induced by amniocentesis. Ind. J. Med. Res. 1974; 62:394-401.
16. Singh S, Padmanabhan R. Teratogenic effects of chlorpromazine hydrochloride in fetuses. Ind. J. Med. Res. 1978; 67:300-309.
17. Scott WJ. Cell death and reduced proliferation rate. In Handbook of Teratology, 1977; 2.
18. Neubert D, Merker HJ, Kohler E, Krowke R, Barrach HJ. Biochemical aspects of teratology, Adv. in Bio.sci. 1971; 6:575-621.
19. Farage Elawar M, Rowles TK. Toxicology of carbaryl and aldicarb on brain and limb cultures of chick embryos. J. Appl. Toxicol. 1992; 12(4):239-244.
20. Overman DO, Seegmiller RE, Runner MN. Coenzyme competition and precursor specificity during teratogenesis induced by 6-aminonicotinamide developmental Biology 1972; 28:573-582.
21. Scifert J, Casida JE. Mechanism of teratogenesis induced by organophosphorus and methyl carbamate insecticides 1981; 1:219-246.

22. Ushell DG, Roger JC, Casida JE. Biochemical studies on the teratogenic action of bidrin and other neuroactive agents in developing hen eggs. *Biochemical Pharmacology*. 1968; 17:1529-42.
23. Greenberg J, La Ham QN. malathion-induced teratisms in the developing chick. *Canadian Journal of Zoology*. 1969; 47:539-542.
24. Khera KS. Toxic and teratogenic effects of insecticides in duck and chick embryos. *Toxicology and Applied Pharmacology*. 1966; 8:345.
25. Meiniel R. Cholinesterase activities and expression of axial teratogenesis in quail embryo exposed to organophosphates. *Compte Rendu Hebdomadaire séances de l'Académie des Sciences, Paris Ser. D* Cited in chemical abstracts. 1977; 87(285):401-404.
26. Walker NE. The effects of malathion and malaaxon on esterase and gross development of the chick embryo. *Toxicology and Applied Pharmacology*. 1971; 19:590-601.
27. Landauer W. Cholinomimetic teratogens: Studies with chicken embryos. *Teratology*. 1975; 12:125-140.
28. Meiniel R. Neuroactive compound and vertebral teratogenesis in the bird embryos. *Experientia*. 1978; 34:394-396.
29. Rogor JC, Upshell DG, Casida JE. Structure- activity and metabolism studies on organophosphate teratogens and their alleviating agents in developing hen eggs with special emphasis on bidrun. *Biochemical pharmacology*. 1969; 18:373-376.
30. Li Q, Si Smith Y, Zeng Q, Weina PJ. Embryotoxicity of artesunate in animal species related to drug tissue distribution and toxicokinetic profiles, *Birth Defects Res. Reprod. Toxicol*. 2008; 83:435-445.
31. Bhabagrahi Rath. Reproductive profile of artemisinin in albino rats. *Indian J Pharmacol*. 2010; 42(3):192-193.
32. Dellicour S, Brasseur P, Thorn P, Gaye O, Olliaro P, Badiane M. Problastic record Linkage for monitoring the safety of artemisinin– based combination therapy in first Trimester of pregnancy in Senegal; *Drug. Saf*. 2013; 36(7):505-513.
33. Qigui Li, Peter Weina J. Severe embryo toxicity of Artemisinin Derivatives in Experimental Animals, but Possibly Safe in Pregnant Women. 2010; 15:40-57.
34. Phillips-Howard PA, Wood D. The safety of antimalarial drugs in pregnancy. *Drug Saf*. 1996; 14(3):131-145.p