

A rare case of asymptomatic malplaced Double-J ureteric stent

^{*1}Dr Amit M Mungarwadi, ²Dr Rajendra B Nerli, ³Dr Vikram Prabha, ⁴Dr Shrikanth P, ⁵Dr Amey Patil,

⁶ Mr Shridhar Ghagane

^{1, 2, 3, 4, 5} Department of Urology KLES Kidney Foundation KLES Dr. Prabhakar Kore Hospital & M.R.C, Nehru Nagar, Belagavi, Karnataka 590010, India.

⁶ Department of Biotechnology & Microbiology Karnatak University Dharwad Karnataka, India.

Abstract

Double-J ureteral stenting is a common urological procedure and has various complications. We report a case of 49 year old female with asymptomatic renal parenchymal perforation by DJ urethral stent following ureterorenoscopy. Post-operative fluoro imaging, computed tomography and ultrasonography is the best way to rule out stent malposition and complications. Early repositioning is the initial step in the management.

Keywords: rare case, asymptomatic, ureteric stent, management

1. Introduction

Double-J (DJ) ureteral stenting is commonly used procedure in urological practice for relief of obstruction, as part of drainage procedures and splinting of a ureteric repair or anastomosis. This procedure has various complication like stent discomfort, irritative bladder symptoms and hematuria [1] as early complaints and migration, encrustation, are the most frequent complications in the late period [1] with renal parenchymal perforation with a DJ ureteral stent has been reported twice in the literature [2-3]. We report a patient with asymptomatic renal parenchymal perforation caused by DJ ureteral stent while being treated for urolithiasis. This complication of ureteral stents is rare and the patient being asymptomatic is not reported till date.

2. Case report

We report a case of 49 year old female patient who attended urology clinic for the management of urolithiasis. Patient was

asymptomatic at presentation. Two months back patient had presented with history pain in the left flank, nausea and vomiting in another medical center where she was diagnosed to have left upper ureteric calculus with left renal calculus, for which she underwent left ureterorenoscopy and DJ stenting. Later patient was referred for extra corporeal shock wave lithotripsy (ESWL) for the renal calculus. Kidney ureter bladder (KUB) radiography (figure 1) revealed a left DJ stent, the lower end of which was in the bladder and the upper end of the DJ stent outside the left renal shadow. Her serum urea, creatinine and hemoglobin levels were normal on presentation. Computerized tomography (CT) (figure 2) revealed a renal parenchymal perforation caused by the DJ stent, and the upper end of the stent lying below the diaphragm and the lower end being in the bladder. The patient underwent DJ stent removal and re-stenting under fluoroscopic guidance. After 2 weeks she underwent ESWL to the lower calyceal calculus followed by DJ stent removal 2 weeks later following stone clearance.

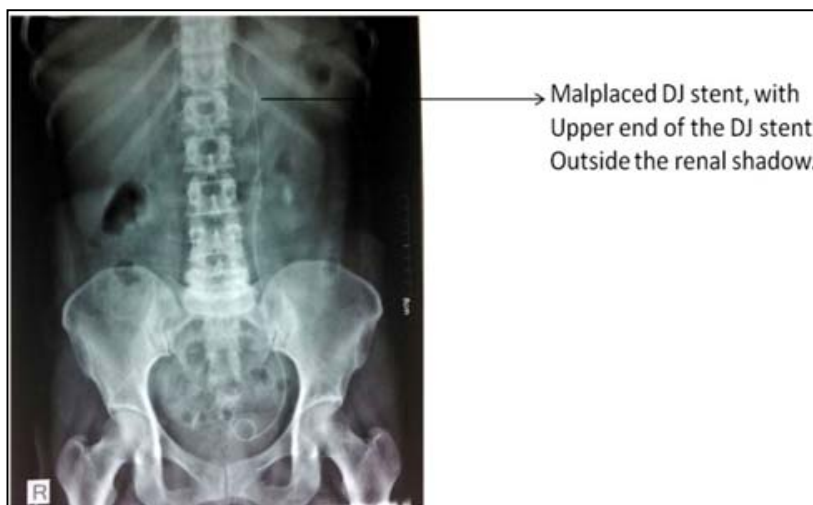


Fig 1: X-ray showing malplaced DJ stent

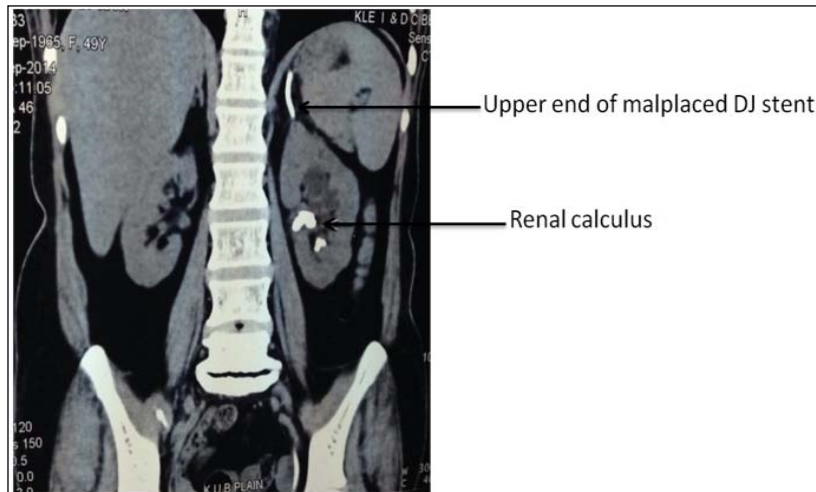


Fig 2: Plain CT showing malplaced DJ stent and left renal calculus

3. Discussion

Ureteral DJ stenting is a common urologic procedure for supra-vesical obstruction and which provides near-physiologic drainage of the kidney. Memon *et al.* and Richter *et al.* reported the most common indication of stent insertion as obstructive uropathy and Nawaz *et al.* reported prophylactic stenting as the most common indication [4-6]. Although ureteral stenting is a common and safe procedure in urology practice, life-threatening complications, including hemoperitoneum, renal vein perforation and ureter arterial fistula, have been reported [10-11]. Ureteral stricture formation may be observed less frequently with stenting after ureteroscopy [7]. Renal parenchymal perforations had been rarely reported earlier. Mehmet D. reported a case wherein a double J stent inserted after ureteroscopic removal of ureteric and renal calculi produced a perirenal haematoma from a parenchymal perforation [8]. A similar case was reported by Nomkomos *et al* [9]. Salazar JE pointed out that an X-ray done post insertion of a stent is an important confirmation of correct placement of the position of the stent [12]. Early detection and treatment of malplaced DJ stents by proper positioning under fluoroscopic guidance is important. The unusual event of this case is that though there was renal perforation by DJ stent, there were no signs of extravasation from the pelvicalyceal system or renal perforation causing hematoma which were seen in the case reports presented earlier.

4. Conclusion

Insertion of a DJ stent should be performed carefully to avoid complications. Post-operative fluoro imaging and ultrasonography both in early postoperative period and later with regular intervals is the best way to rule out stent malposition or other serious complications. Early detection and replacement of the malplaced stent under fluoro guidance is an important step in the management.

5. References

1. Damiano R, Oliva A, Esposito C, de Sio M, Autorino R, D'Armiento M. Early and late complications of double pigtail ureteral stent. *Urol Int.* 2002; 69:136-40.

2. Dundar M, Caliskan T, Kocak I. Unexpected complication: renal parenchymal perforation with double-j ureteral stent. *Urol Res.* 2008; 36:279-81.
3. Nomikos MS, Chousianitis Z, Georgiou C, Georgellis C, Rikas P, Anagnostou T. Renal parenchyma perforation and hematoma formation following Double-J stent insertion in a solitary functioning kidney: an unusual complication. *Case Rep Urol.* 2012, 301-275.
4. Memon NA, Talpur AA, Memon JM. Indications and complications of indwelling ureteral stenting at NMCH, Nawabshah. *Pak J of Surg.* 2007; 23(3):187-91.
5. Richter S, Ringel A, Shalev Nissenkorm I. The indwelling ureteric stent: a 'friendly' procedure with unfriendly high morbidity. *Br J Urol Intl.* 2000; 85(4):408-11.
6. Nawaz H, Hussain M, Hashmi A, *et al.* Experience with indwelling "J.J" ureteral stents. *J Pak Med Assoc.* 1993; 43(8):147-9.
7. Srivastava A, Gupta R, Kumar A, Kapoor R, Mandhani A. Routine stenting after ureteroscopy for distal ureteral calculi is unnecessary: results of a randomized controlled trial. *J Endourol.* 2003; 17:871-4.
8. Mehmet D, Cahson T, Izzet K. Unexpected complications: Renal parenchymal perforation with double J stent. *Urol Res.* 2008; 36:279-81.
9. Nomikos MS, Chousianitis Z, Georgiou C, Georgellis C, Rikas P, Anagnostou T. Renal parenchyma perforation and hematoma formation following Double-J stent insertion in a solitary functioning kidney: an unusual complication. *Case Rep Urol.* 2012, 301-275.
10. Kidd RV, Confer DJ, Baskin AM. Ureteral and renal vein perforation with placement into the renal vein as a complication of the pigtail ureteral stent. *J Urol.* 1980; 124:424-6.
11. Chitale SV, Ho ET. Haemoperitoneum secondary to ureteric stenting. *Int Urol Nephrol.* 2002; 34:197-8.
12. Salazar JE, Johnson J, Scott L. Perforation of renal pelvis by ureteric stents. *AJR Am. J Roentgenol.* 1984; 143:816-818.