

A study on Ultrasonographic fetal surveillance in the management of isoimmunized pregnancy

¹Dr. Arvind Kumar Choudhary, ²Dr. Seema Choudhary, ³Dr. Gaurav Pandey, ⁴Dr. Supriya Sharma,
⁵Dr. Sushma Pandey

¹ Associate Professor, Department of Pediatrics, Narayan Medical College & Hospital, Sasaram, Bihar, India

² Associate Professor, Department of Obs & Gynae, Himalayan Institute of Medical Sciences, Dehradun, Uttarakhand, India

³ Assistant Professor, Department of Gastroenterology, Sanjay Gandhi Post Graduate Institute of Medical Science, Lucknow, Uttar Pradesh, India

⁴ Assistant Professor, Department of Surgical Gastroenterology, Sanjay Gandhi Post Graduate Institute of Medical Science, Lucknow, Uttar Pradesh, India

⁵ Ex-Professor & HOD, Department of Obs & Gynae, Patna Medical College and Hospital, Patna, Bihar, India

Abstract

Our purpose was to evaluate the impact of non-invasive assessment of fetal anemia and anti-D antibody quantification on the timing and frequency of invasive procedures in pregnancies complicated by rhesus alloimmunization. Nineteen consecutive non-hydrops pregnancies referred to the fetal medicine center were assigned a prior risk category (none/mild, moderate or severe) and monitored by:

(1) Serial fetal measurements of umbilical vein maximal flow velocity (UVV max), liver length and spleen perimeter measurements; and

(2) Serial anti-D antibody concentration. Invasive tests for fetal anemia (amniocentesis or fetal blood sampling) were deferred in the absence of abnormal ultrasound findings and/or rising antibody levels.

In six cases serial non-invasive tests were normal with stable antibody levels, and no invasive tests were performed; four infants were mildly affected, one was unaffected and one required postnatal exchange transfusion. In the remaining 13 affected cases, amniocentesis was performed in nine cases for: elevated UVVmax alone (n = 3), elevated UVVmax and an increased antibody level (n = 2), or normal UVVmax with an increased antibody level (> 15 IU/ml) and severe prior risk category (n = 4).

Six fetuses underwent fetal blood sampling (initial hematocrit 9–29%), and five of these had an elevated UVVmax. Liver length and spleen perimeter measurements were increased in only one anemic fetus (hematocrit 13%). Of 17 infants born alive, an elevated UVVmax prior to delivery was predictive of the need for exchange transfusion (six of seven cases with an elevated UVVmax vs. one of ten with a normal UVVmax; $\chi^2 = 5.73$, $p = 0.017$ with Yates' correction). These preliminary data suggest that pregnancies with a mild or no history of fetal anemia may be monitored by a combination of serial antibody quantification and Doppler monitoring of UVVmax.

Keywords: red cell alloimmunization, non-invasive assessment, anti-d antibody, umbilical vein maximal flow velocity, ultrasonography

Introduction

The management of severe red cell alloimmunization has been transformed by ultrasound-guided invasive diagnosis and treatment in the form of fetal blood sampling and intravascular transfusion. Pregnancies with a history of severe disease, or those that are hydropic at first assessment, clearly benefit from this approach, with a perinatal survival rate of 85–90% [1, 2]. With the increasing use of antenatal prophylaxis for rhesus D-negative women, the incidence of severe disease has fallen³. This is reflected by a reduction in the number of severely affected cases being referred to tertiary referral fetal medicine units. This trend has been accompanied by an increase in the number of women referred with either mild or no history of fetal anemia and low levels of antibody concentration. For such patients invasive testing may accelerate the disease process through fetomaternal hemorrhage [4–7], increasing the likelihood of fetal blood sampling and intravascular transfusion in either this, or a subsequent, pregnancy. Non-

invasive monitoring may allow the obstetrician to defer a decision to perform an invasive test, thereby reducing the overall risk of any procedure-related complication. Amniocentesis can be deferred until the end of the second trimester, when amniotic fluid OD450 estimations are more reliable [8, 9]. As a consequence of fetal anemia, tissue oxygenation is preserved through an increase in fetal cardiac output. Noninvasive assessment of fetal anemia by Doppler ultrasound is based on the principle that an increase in cardiac output is shown by changes in arterial or venous flow velocity waveforms [10–14]. These studies have all been cross-sectional (i.e. at the time of invasive testing), so a prospective longitudinal evaluation is required. In this study we report our preliminary experience of introducing prospective non-invasive assessment of fetal anemia by serial umbilical vein maximal flow velocity (UVVmax) measurements, together with estimations of liver length and spleen perimeter, and serial determination of maternal antibody levels.

Materials and Methods

A total of 19 women with singleton non-hydropic fetuses were referred to our unit following detection of maternal anti-D antibody and therefore suspected fetal red cell anti-D alloimmunization. At the first visit women referred with rhesus alloimmunization were grouped according to history as follows: none (n = 7); mild (term delivery with phototherapy) (n = 4); moderate (previous neonatal exchange transfusion following delivery at term) (n = 4); or severe (previous fetal transfusion, fetal death due to hydrops or neonatal exchange transfusion at < 34 weeks) (n = 4). Alloimmunization had occurred to the following antigens: D alone (n = 14); D+c (n = 2); D+e (n = 1); D+c+e (n = 1); and D+c+Kell (n = 1). At each visit a sample of maternal blood was taken for anti-D quantification (and titer estimation of other antibodies, if present).

Table 1 shows initial anti-D quantification according to history and invasive procedures performed. At each visit a conventional ultrasound examination was performed to look for the presence of hydrops and to monitor fetal growth, umbilical artery Doppler findings and amniotic fluid volume. In addition, the following measurements were made, as described by Oepkes and colleagues [12, 15]. UVVmax was

recorded in a cross-section of the fetal abdomen during apnea with an angle of insonation of < 30° as shown in Figure 1.

Table 1: Anti-D quantification at the first examination according to history, and subsequent invasive tests.

	History		
	None or mild	Moderate	Severe
Number	11	5	3
Gestational age (weeks) at first examination	23 (14–30)	23 (13–30)	19 (14–20)
First antibody concentration (IU/ml)	6.8 (1.2–38)	8.5 (4–24)	62.2 (56–69)
<i>Invasive procedures</i>			
First amniocentesis			
n	5*	4*	—
gestational age (weeks)	31 (26–35)	31 (28–34)	—
FBS and transfusion			
n	1	2	3
gestational age (weeks)	31	30.5 (27–34)	22 (21–22)
<i>Reason for invasive procedure</i>			
Elevated UVV _{max}	3/5	4/5	2/3
Normal UVV _{max} and elevated anti-D	2/5	1/5	1/3
No invasive procedure	6	0	0

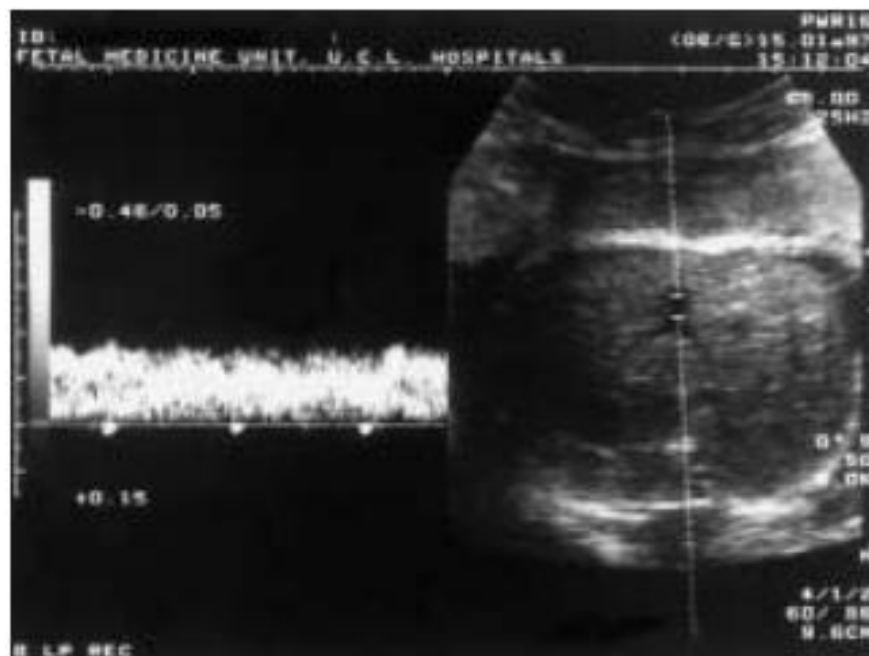


Fig 1: Cross-sectional view of the fetal abdomen, recording the umbilical vein maximal flow velocity (0.15 m/s). Note that the angle of insonation is less than 30°

Maximum fetal liver length was measured in a parasagittal scan of the fetal abdomen from the diaphragm to the lower edge of the right liver [16, 17]. The fetal spleen perimeter was measured by the trace method in the same cross-sectional plane as used for the fetal stomach [15]. These three measurements were plotted on a graphical data sheet with the reference ranges of Oepkes [17]. Measurements above the 95th centile were regarded as abnormal. Patients with no or mild history of anemia were seen every 4 weeks before 28 weeks and every 2 weeks thereafter, provided the non-invasive tests were normal and the antibody concentration was < 15 IU/ml. Visits were scheduled every 1–2 weeks in patients with a moderate or severe history or a rapidly rising antibody level. Abnormal

non-invasive assessment and/or rising antibodies were indications for invasive procedures. Amniocentesis was performed under continuous ultrasound guidance with a 22-gauge needle.

The ΔOD450 measurement was obtained spectrophotometrically and plotted on a modified Liley chart [18]. Fetal blood sampling was performed with the use of a 20-gauge spinal needle and freehand technique, as described previously [6]. The following information was ascertained, following delivery: indication for and mode of delivery, gestational age and birth weight, initial hematocrit and bilirubin concentration, need for either phototherapy or exchange transfusion. Seventeen pregnancies resulted in a live

birth and two fetal deaths occurred as a direct complication of intravascular transfusion. The χ^2 test with Yates' correction was used to evaluate the utility of the UVVmax in predicting the need for neonatal exchange transfusion.

Results

Complete follow-up was available in all patients (n = 19). This is summarized in Table 1. Fifteen partners were homozygous for the relevant antigen. Of the four remaining heterozygotes, two of the fetuses were genotyped following amniocentesis (one correctly diagnosed as RhD-positive and one was inconclusive: this fetus was found to be RhD-negative postnatally). The remaining two cases had histories of mild anemia, stable antibody levels and normal UVVmax values throughout the pregnancy. Therefore, 18 of 19 pregnancies were affected.

Figure 2 shows the reference range for UVV max according to Oepkes and co-workers [17], and on this are plotted the single/serial data of the six pregnancies that were monitored by serial non-invasive assessments without any procedure (one was found to be unaffected postnatally). In none were either liver or spleen measurements found to be abnormal and all UVVmax measurements were within the reference range. One neonate from this group required exchange transfusion when delivery took place 14 days after the last fetal assessment, and a Cesarean section was performed for fetal distress when there was evidence of a retroplacental clot.

Nine of the remaining 13 pregnancies underwent single (n = 5) or serial (n = 4) amniocentesis for Δ OD450. The indications for amniocentesis were: elevated UVVmax alone (n = 3); elevated UVVmax and an increased antibody level (n = 2); or normal UVVmax with an increased antibody level (> 15 IU/ml) and severe prior risk category (n = 4). Of the five cases with high UVVmax values at the time of amniocentesis, four had an amniotic fluid Δ OD450 value in zone II/III and one of these underwent fetal blood sampling/ intravascular transfusion. A second case with a normal UVVmax and high anti-D level subsequently showed an increasing level of anti-D and a high UVVmax, and therefore underwent fetal blood sampling/intravascular transfusion.

Longitudinal data in these two cases are shown in Figure 3a. Liver length and spleen perimeter measurements were normal in each case. Six fetuses underwent fetal blood sampling/intravascular transfusion, the hematocrit values at the first procedure were 9–29% (median 26%) and all were transfused. Figure 3 shows serial individual UVVmax values in these cases. In five cases, UVVmax at the first fetal blood sampling/intravascular transfusion procedure was elevated. However, subsequent procedures were sometimes performed with a normal UVVmax, either because of a rising anti-D level or because of our estimate of the decline in the fetal hematocrit. Liver length and spleen perimeters were abnormal in only one case, in which the pre-transfusion hematocrit was 13% (Figure 3a).

One case needed fetal blood sampling/intravascular transfusion with a low UVVmax, because the fetus had developed hydrops by the second visit (Figure 3b). One case had a very severe obstetric history with previous hydropic losses before 18 weeks of gestation. Three intraperitoneal transfusions were therefore performed between 16 and 19 weeks prior to the first intravascular transfusion at 22 weeks (Figure 3b). Of the 17

infants born alive, seven required exchange transfusion and six of these had an elevated UVVmax at the last assessment prior to delivery. Of the ten cases who did not require exchange transfusion, only one had an elevated UVVmax at the last assessment prior to delivery.

An elevated UVVmax prior to delivery was therefore predictive of the need for exchange transfusion ($\chi^2 = 5.73$; p = 0.017 with Yates' correction).

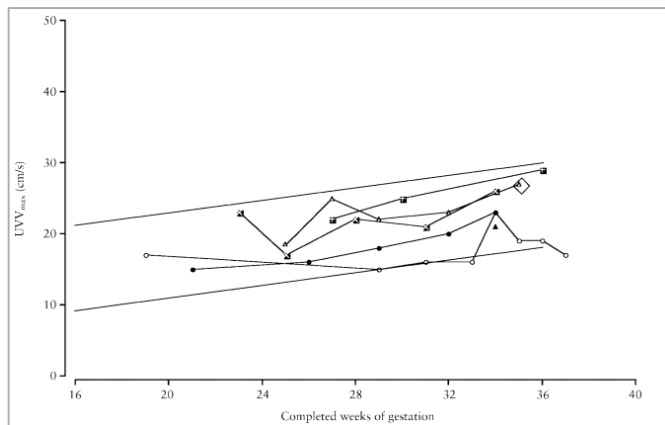


Fig 2: Umbilical vein maximal blood flow velocity (UVVmax) measurements in six cases monitored by ultrasound in the absence of any invasive procedures, according to the reference range of Oepkes and colleagues

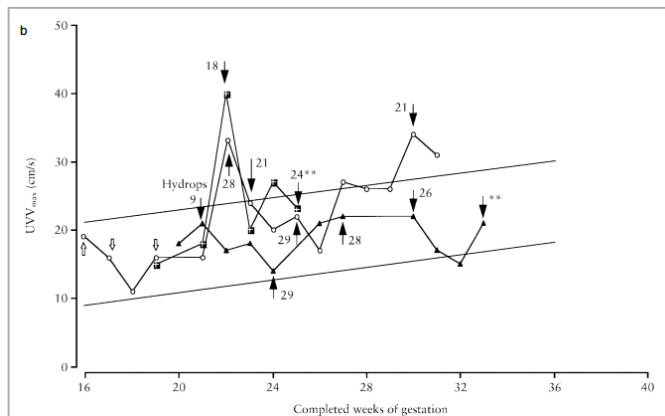
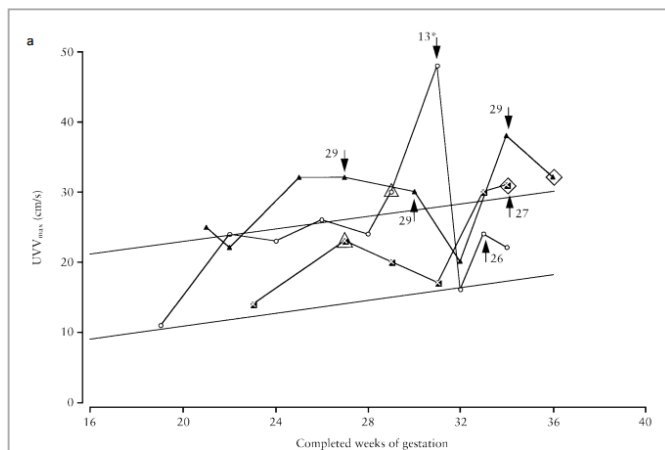


Fig 3: Serial umbilical vein maximal blood flow velocity (UVVmax) values in six cases (a and b) that underwent fetal blood sampling (FBS)/transfusion

Discussion

In this preliminary report we describe our evolving experience of the use of serial determination of antibody concentration, together with ultrasound measurements of umbilical vein flow velocity (UVVmax), liver length and spleen perimeter, in the management of pregnancies referred with RhD red cell alloimmunization. Since we elected to defer invasive testing for fetal anemia in patients with no or a mild history and normal non-invasive tests, we moved to a policy of serial quantification, rather than titer estimation, of maternal anti-D antibody, since this is less prone to laboratory variation.

Of the 19 patients evaluated, six had no history or mild history of anemia, with low levels of anti-D; all had normal non-invasive tests, and only one fetus required an exchange transfusion postnatally. Serial assessments in the remaining 13 patients allowed us safely to defer the timing of the first invasive procedure with the exception of one case that developed hydrops at 21 weeks' gestation, seen during the early part of 1995, prior to our institution of a policy of reviewing all antibody results within 7 days of fetal assessment.

The mother's anti-D level had increased to 69 IU/ml; a subsequent visit 1 week later, rather than after 2 weeks, may have prevented this complication from arising.

In addition, she had a severe history, illustrating the importance of this component of patient assessment. We record the severity of the history on our data sheet in order to emphasize this point. There are a large number of reports in the literature describing the correlation between arterial and venous Doppler measurements and the degree of fetal anemia^[10-14, 17]. However, in all of these studies the data were obtained cross-sectionally, i.e. at the time of an already planned invasive procedure (fetal blood sampling), except for a single case report that was studied longitudinally^[19].

To our knowledge, this is the first report of the prospective use of non-invasive tests to influence clinical management in a cohort of patients. Of the ultrasound and Doppler parameters evaluated cross-sectionally by Oepkes and colleagues^[12] our data suggest that serial measurement of UVVmax is worthwhile but that the measurement of either liver length or spleen perimeter was of little value. We did observe elevated values for both liver length and spleen perimeter in one case with a pre-transfusion hematocrit of 13%, but, as shown in Figure 3a, the UVVmax value was considerably elevated. The correlation between the UVVmax and the fetal hematocrit has been shown previously^[17].

Presumably, elevation in UVVmax with progressive fetal anemia precedes demonstrable increases in either liver length or spleen perimeter. The value of careful attention to both the severity of the past history and serial determination of antibody concentration means that patient management does not rely solely upon UVVmax determinations. Ouzounian and colleagues²⁰, in a study of the management of rhesus isoimmunization using the non-stress test as a predictor of the need for fetal transfusion, showed that 12 of 51 (23.5%) patients with reactive non-stress tests and seven of nine (77.8%) patients with non-reactive non-stress tests required neonatal transfusion ($p = 0.003$; odds ratio 11.4; 95% confidence interval 1.7-120.2). This study demonstrated the potential for the non-stress test to predict the need for neonatal transfusion in pregnancies with red cell isoimmunization.

Likewise, in our study, high UVVmax results before delivery indicated a high risk for requiring postnatal exchange transfusion. By contrast, low UVVmax values within a week of delivery in the context of a history of mild anemia and/or low antibody levels is expected to predict a low risk of the infant requiring exchange transfusion. For this reason we recommend passing such information to the neonatal pediatricians before delivery. Amniocentesis will always be indicated for either karyotyping or fetal genotyping with a heterozygous male partner^[21, 22].

At present, our experience is not yet sufficient to consider abandoning indirect assessment of fetal anemia using amniotic fluid $\Delta OD450$ measurements. However, we believe a policy of serial non-invasive monitoring, using the umbilical vein maximum flow velocity and serial antibody quantification, deserves further examination as an alternative to routine invasive assessment in rhesus-sensitized women.

References

1. Rodeck CH, Nicolaides KH, Warsof SL, Fysh WJ, Gamsu HR, Kemp JR. et al. The management of severe rhesus isoimmunization by fetoscopic intravascular transfusion. *Am J Obstet Gynecol.* 1984; 150:769-74.
2. Nicolaides KH, Soothill PW, Rodeck CH, Clewell W. Rh disease: intravascular fetal blood transfusion by cordocentesis. *Fetal Ther* 1986; 1:185-92.
3. Hughes RG, Craig JIO, Murphy WG, Greer IA. Causes and clinical consequences of Rhesus (D) haemolytic disease of the newborn: a study of a Scottish population, 1985-1990. *Br J Obstet Gynaecol.* 1994; 101:297-300.
4. Murray JC, Karp LE, Williamson RA, Cheng EY, Luthy DA. Rh isoimmunization related to amniocentesis. *Am J Med Genet* 1983;16:527-34.
5. Bowman JM, Pollock JM. Transplacental fetal hemorrhage after amniocentesis. *Obstet Gynecol* 1985; 66:749-54.
6. Nicolini U, Kochenour NK, Greco P, Letsky EA, Johnson RD, Contreras M, Rodeck CH. Consequences of fetomaternal haemorrhage after intrauterine transfusion. *Br Med J.* 1988; 297:1379-81.
7. Bowell PJ, Selinger M, Furgeson J, Giles J, Mackenzie IZ. Antenatal fetal blood sampling for the management of alloimmunised pregnancies: effect upon maternal anti-D potency levels. *Br J Obstet Gynaecol.* 1988; 95:759-64.
8. Nicolaides KH, Rodeck CH, Mibashan RS, Kemp JR. Have Liley charts outlive their usefulness? *Am J Obstet Gynecol* 1986; 155:90-4.
9. Frigoletto FD, Greene MF, Benacerraf BR, Barss VA, Saltzman DH. Ultrasonographic fetal surveillance in the management of the isoimmunized pregnancy. *N Engl J Med.* 1986; 315:430-2.
10. Rightmire DA, Nicolaides KH, Rodeck CH, Campbell S. Fetal blood velocities in Rh isoimmunization: relationship to gestational age and to fetal hematocrit. *Obstet Gynecol* 1986; 68:233-6.
11. Nicolaides KH, Bilardo CM, Campbell S. Prediction of fetal anemia by measurement of the mean blood velocity in the fetal aorta. *Am J Obstet Gynecol* 1990;162:209-12.
12. Oepkes D, Brand R, Vandenbussche FP, Meerman RH, Kanhai HHH. The use of ultrasonography and Doppler in

- the prediction of fetal haemolytic anaemia: a multivariate analysis. *Br J Obstet Gynaecol.* 1994; 101:680-4.
13. Hecher K, Snijders R, Campbell S, Nicolaides KH. Fetal venous, arterial, and intracardiac blood flows in red cell isoimmunization. *Obstet Gynecol.* 1995; 85:122-8.
 14. Steiner H, Schaffer H, Spitzer D, Batka M, Graf AH, Staudach A. The relationship between peak velocity in the fetal descending aorta and hematocrit in rhesus isoimmunization. *Obstet Gynecol* 1995; 85:659-62.
 15. Oepkes D, Meerman RH, Vandenbussche FPHA, vanKamp IL, Kok FG, Kanhai HHH. Ultrasonographic fetal spleen measurements in red blood cell-alloimmunized pregnancies. *Am J Obstet Gynecol.* 1993; 169:121-8.
 16. Weiner S, Bolognese RJ, Librizzi RJ. Ultrasound in the evaluation and management of the isoimmunized pregnancy. *J Clin Ultrasound.* 1981; 9:315-23.
 17. Oepkes D. Ultrasonography and Doppler in the management of red cell alloimmunized pregnancies. MD thesis, University of Leiden, The Netherlands, 1993
 18. Fairweather DV, Whyley GA, Millar MD. Six years' experience of the prediction of severity in rhesus haemolytic disease. *Br J Obstet Gynaecol* 1976; 83:689-706.
 19. Warren PS, Gill RW, Fisher CC. Doppler flow studies in rhesus isoimmunization. *Semin Perinatol* 1987; 11:375-8.
 20. Ouzounian JG, Alsulyman OM, Montiero HA, Songster GS. The non-reactive non-stress test: predictive value for neonatal anemia in the isoimmunized pregnancy. *Obstet Gynecol* 1996; 88:3647.
 21. Bennett PR, Le Van Kim C, Colin Y, Warwick RM, Cherif Zahar B, Fisk NM, Cartron JP. Prenatal determination of fetal RhD type by DNA amplification. *N Engl J Med* 1993; 329:607-10.
 22. Fisk NM, Bennett PR, Warwick RM, Letsky EA, Welch R, Vaughan JI, et al. Clinical utility of fetal RhD typing in alloimmunized pregnancies by means of polymerase chain reaction on amniocytes or chorionic villi. *Am J Obstet Gynecol.* 1994; 171:50-4.