

Utility of cranial ultrasonography in preterm and critically ill neonates

¹Dr Suryakant Ingale, ²Dr Pulkit Sheta

¹ Associate Professor, Department of Paediatrics, KIMSUDU, Karad, Maharashtra, India

² Post Graduate Resident, Department of Paediatrics, KIMSUDU, Karad, Maharashtra, India

Abstract

Neonatal care in India is advancing at an impressive phase at the level of the community as well as in tertiary care units. Concept of “survival” of newborn has given way to “intact survival” of the high risk newborn emphasizing detection of neurological subnormalities at the earliest. Neurosonography, which is now ubiquitously available, is an ideal tool for the primary screening of the neonatal brain. Despite its wide availability in the hospitals, the penetration of cranial ultrasonography in Indian NICU’s is still very little.

Objective: This study was undertaken to assess the importance of cranial ultrasound as an investigatory modality for high risk neonates and to find out the morphology of various cerebral lesions and correlate clinically.

Methods: This observational clinical study was conducted at Krishna Institute of Medical Sciences university, Karad between December 2016 and July 2017. 100 high risk neonates admitted to our NICU were included in the study. Detailed history and clinical examination with appropriate investigations were done. These neonates were subjected to neurosonography on selected days as per protocol and morphology of various findings was recorded. Clinical correlation with CUS findings and follow up was done.

Results: Incidence of CUS abnormalities in high risk neonates is 26% in the present study. 11% of these had evidence of intracranial bleed, 7% hyperechogenic thalami, 3% definite HIE, and 5% had cerebral edema. Of the 28% of neonates with abnormal findings on CUS 27.5% had no evidence of perinatal asphyxia, 32.6% had severe, 33% had moderate 34.4% had mild perinatal asphyxia as per Apgar scoring?

Conclusion: This study highlights the convenience and diagnostic efficiency of cranial ultrasound in high risk neonates in NICU. It also emphasizes its use as a screening modality for preterms and birth asphyxia neonates influencing their neurodevelopmental outcome. CUS is critical as an investigatory modality in NICU which effectively documents morphology of brain damage.

Keywords: cranial ultrasound, NICU, high risk neonates

Introduction

In parallel to the dawn of modern neonatal intensive care, the survival of the “High Risk Neonate” has greatly improved necessitating early detection of neurological subnormalities.

Cranial ultrasound (CUS) has become an essential diagnostic tool in modern neonatology for depicting normal anatomy and pathological changes in neonatal brain. Because in the neonate, many sutures and fontanels are still open and these can be used as acoustic windows to “look” into the brain ^[1].

It can be easily performed at the bedside with a portable ultrasound machine, conveniently in the NICU which meets the definition of point-of-care testing (POCT). It is also cost effective, radiation free and its safety is well established in infants ^[2].

Any neonate, regardless of birth weight, size, or gestational age, who has a greater than average chance of morbidity or mortality, due to fatal, maternal or placental anomalies or an otherwise compromised pregnancy, especially within the first 28 days of life is categorized as high risk neonate ^[3]. CUS plays an important role in assessing neurological prognosis of these high risk infants.

Modern machines, a variety of acoustic windows and sequential scanning at optimal times giving high-quality images has increased the recognition of features suggestive of developmental, metabolic and infectious disorders.

It detects most of the hemorrhagic, ischemic and cystic brain lesions as well as calcifications, cerebral infections and major structural abnormalities in high risk infants ^[1].

It is also very helpful in the early diagnosis of the many etiologies of neonatal encephalopathy and seizures in the term infant and the subsequent monitoring of progress of hypoxic-ischemic brain injury.

Most new-born intensive care unit centres perform serial cranial ultrasound evaluations early in the course of hospitalization for premature infants and often, a follow-up examination is done at a later age. These evaluations are done to document the presence of intracranial hemorrhage, to guide choice of therapies that may exacerbate risk of further hemorrhage, and to counsel families about neurodevelopment outcomes ^[4].

CUS is also very helpful in assessing severity and neurodevelopment outcome in infants with HIE⁵ and in seriously ill neonates with cerebral abnormalities, either congenital or acquired, it plays a role in decision making on continuation or withdrawal of intensive treatment.

The quality of CUS imaging and its diagnostic accuracy depends on the ultrasound machine and also expertise of the examiner. When performed as per protocol it is reliable investigation for commonly occurring neonatal events. CUS can be initiated even immediately after birth and hence suitable

for screening and can be repeated as often as possible without any adverse- affects and hence helps in proper follow up of babies with neurological problems.

Materials and Methods

This study was conducted at krishna Institute of Medical Sciences university, karad between december 2016 and July 2017. 100 high risk neonates admitted to neonatal intensive care unit were selected as per the inclusion criteria on non-randomized purposive sampling basis and were subjected to neurosonography on selected days. If cranial ultrasonography revealed various findings, repeat neurosonogram were done to follow up sequelae if any.

High risk neonates with any of the following were included in the study:

1. Neonatal convulsions
2. Birth asphyxia & HIE
3. Respiratory distress
4. Neonatal sepsis
5. Preterm neonates
6. Neonates born out of traumatic/instrumental labor
7. Metabolic disturbances with convulsions
8. Congenital malformation of CNS & neural tube defects

After obtaining the informed consent from the parents/guardian regarding inclusion of the neonate in the study. Assessment of factors placing the neonate in a high risk category was done taking detailed maternal and perinatal history reviewing antenatal records. Detailed clinical examination with special emphasis on neurological system was done.

Evaluation with baseline routine investigations was done for all babies and cranial ultrasound of the high risk neonate fulfilling the inclusion criteria was performed. Follow up cranial ultrasound was done in case of findings revealed and for preterm neonates. Morphology of cranial ultrasound findings was studied and recorded and clinical correlation with various findings on cranial ultrasound was done. Neonates

were followed till recovery and discharge from NICU.

The sonograms were performed on a Voluson 630 pro GE machine using a multi frequency high density volume -TV/TR probe. All ultrasounds were performed by a single radiologist to avoid inter-observer variation

Statistical Analysis

Descriptive statistical analysis was carried out in the present study. Results on continuous measurements are presented on Mean±SD (Min-Max) and results on categorical measurements presented in Number (%). Significance is assessed at 5% level of significance.

Chi-square/Fisher Exact test was used to find the significance of study parameters on categorical scale between two or more groups.

Results

Incidence of CUS abnormalities in high risk neonates is 28% in the present study. There were 64% male and 36% female neonates enrolled of which 40% were preterm and 60% term high risk neonates with birth weight distribution of Mean ± SD: 2.19±0.72. Mode of delivery was normal vaginal for 47% neonates and 53% via LSCS for various reasons.

In the correlation of perinatal risk factors with abnormal cranial ultrasound findings, there was statistically significant correlation only with PIH (pvalue-0.05). Correlation of APH, PROM, multiple births and birth trauma was statistically not significant.

There was statistically significant correlation between abnormal cry (pvalue-0.049), abnormal tone (p-0.014), abnormal activity (p-0.018), and presence of cyanosis (p value-0.035) on clinical examination and presence of abnormalities on cranial ultrasound.

Of the high risk neonates with term gestation, 76.6% had normal and 24.6% had abnormal CUS. Of the high risk neonates with preterm gestation, 65% had normal and 35% had abnormal CUS.

Table 1: Correlation of gestational age with various cranial ultrasound findings

Cranial Ultrasound	Number of neonates (n=100)	Gestational age (weeks)			p value
		<32 (n=16)	33-36 (n=24)	>37 (n=60)	
Normal	72(72%)	9(56.2%)	17(70.8%)	46(76.6%)	0.170
Abnormal	26(26%)	9(35.7%)	4(24%)	13(24.6%)	
Gmh	10(10%)	3(18.7%)	3(12.5%)	4(6.6%)	0.140
Other bleeds	1(1%)	0(0%)	0(0%)	1(1.6%)	1.000
HIE	3(3%)	1(6.2%)	0(0%)	2(3.3%)	0.322
Thalamic Hyperechogenicity	7(7%)	2(12.5%)	0(0%)	5(8.3%)	0.464
Cerebral edema	5(5%)	0(0%)	0(0%)	5(8.3%)	0.467
Other findings	2(2%)	1(6.2%)	1(4.1%)	0(0%)	0.057+

Some patients had multiple CUS findings.

In the present study, 40% high risk neonates were preterms, 32% had evidence of perinatal asphyxia, 4% had birth trauma, 40% had evidence of neonatal sepsis, 23% had neonatal seizures in NICU stay, 43% clinically had respiratory distress,

8% had documentation of hypoglycemia and 12% had hypocalcemia on investigatory record. There were no neonates with congenital malformations or neural tube defects.

Table 2: Correlation of CUS abnormalities in high risk neonates

Cranial ultrasound	Number of neonates (n=100)	Inclusion criteria			
		Preterm (n=40)	Neonatal sepsis (n=40)	Seizures (n=23)	Birth trauma (n=4)
Normal	72(72%)	28(70%)	33(82.5%)	17(73.9%)	2(50%)
Abnormal	26(26%)	14(35.0%)	7(17.5%)	7(2%)	2(50%)
GMH	10(10%)	7(17.5%)	1(2.5%)	1(4.3%)	0(0%)
Other bleeds	1(1%)	0(0%)	1(2.5%)	1(4.3%)	0(0%)
HIE	3(3%)	1(2.5%)	2(5.0%)	1(4.3%)	0(0%)
Thalamic hyperechogenicity	7(7%)	4(10.0%)	4(10.0%)	3(13%)	0(0%)
Cerebral edema	5(5%)	0(0%)	0(0%)	5(21%)	1(25%)
Other findings	2(2%)	2(4.5%)	2(4.3%)	1(4.3%)	1(25%)

Correlation of CUS abnormalities and birth asphyxia showed that of the 26% of neonates with abnormal findings on CUS 23.5% had no evidence of perinatal asphyxia, 28.6% had severe, 30% had moderate 33.3% had mild perinatal asphyxia as per Apgar scoring.

Of the high risk neonates with term gestation having abnormal findings on CUS, 7.5% had thalamic hyperechogenicity, 8.3% had cerebral edema, 8.2% had intracranial bleed and 3.3% had HIE.

Of the high risk neonates with preterm gestation having abnormal findings on CUS, 15.0% had intracranial bleed, 5% had thalamic hyperechogenicity, 10% had other findings and 2.5% had HIE.

There was statistically significant correlation between findings on CUS and day of life of neonate when CUS was done. All the abnormal findings on CUS were picked up during 24-72 hours of life. 82.4% normal CUS were picked up during 24-72 hours, 4.1% in less than 24 hours and 13.5% after 72 hours of life.

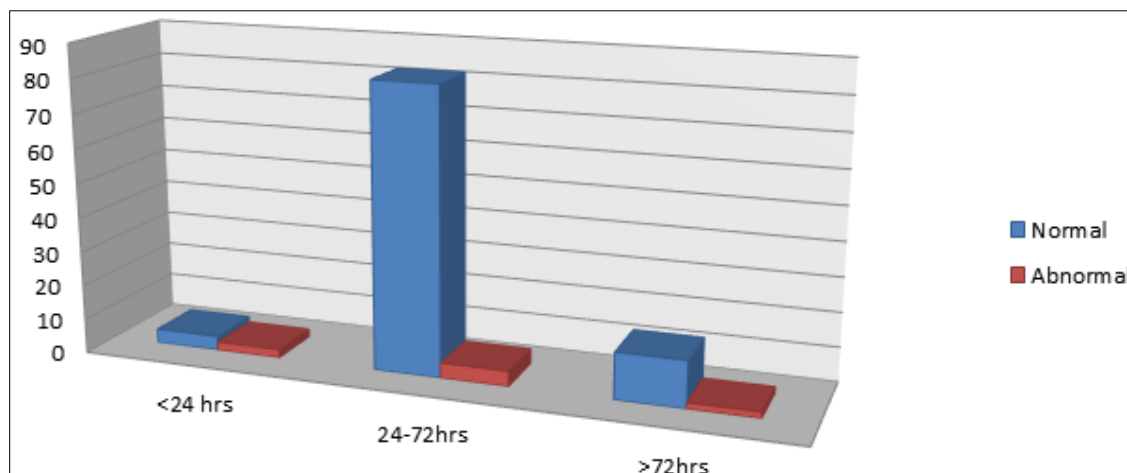


Fig 1: Bar chart showing distribution of high risk Neonates based on timing of cranial ultrasound

One preterm neonate on regular follow up CUS developed findings suggestive of cystic periventricular leucomalacia well correlating with clinical outcome and two other neonates on regular follow up CUS had developed cystic encephalomalacia. There was no statistically significant correlation between various findings on CUS and clinical outcome of the neonate. 89% of neonates enrolled had good recovery at the time of NICU discharge, 3% died and 8% were discharged from NICU for various reasons before clinical recovery.

Discussion

Despite the wide availability of ultrasound machines in the hospitals, the penetration of CUS in Indian NICU’s is still very little.

CUS has several advantages, it is cheap, easy to perform, non-invasive and can be initiated at a very early stage, even immediately after birth. It can be repeated as often as necessary, and thereby enables visualization of ongoing brain maturation and the evolution of brain lesions. In addition, it can be used to assess the timing of brain damage [1].

De Vries and Cowan *et al.* [6] have suggested that cranial ultrasound and MRI are complementary modalities, with ultrasound as an especially useful tool in the early days, when the infant is unstable for transport and ultrasound findings may be sufficient for major clinical decisions. Present study aims at proving the same.

In four studies [7, 10] reporting results of a total of 87 autopsies performed on Preterm infants, USG was 76% to 100% accurate in detecting grade 1 lesions of > 5 mm and grade 3 and grade 4 hemorrhages.

Detection of grade 2 hemorrhages was much less accurate. Correlation of US findings of cystic periventricular leukomalacia (PVL) with neuropathologic data was evaluated in three studies [10, 12]. Each study found 100% correlation between USG findings and neuropathologic data. Ultrasound is also particularly useful in detecting some important congenital malformations such as cystic lesions (hydrocephalus, porencephalic cysts, Dandy-Walker cysts complex, and arachnoid cysts), corpus callosal agenesis and aneurysm of vein of Galen (color Doppler).

Eugenio Mercuri, Lilly Dubowitz *et al.* [13] reported an incidence 20% of ultrasound abnormalities in apparently well neonates and reported ischemic lesions, such as periventricular and thalamic densities were the most common finding (8%), followed by intracranial hemorrhagic lesions (6%) on CUS. In the present study, on CUS, 24% of neonates had abnormal findings. 11% of these had evidence of intracranial bleed, 7% hyperechogenic thalami, 2% definite HIE, 4% had cerebral edema.

Hence high efficacy of CUS in detecting presence of brain damage and its evolution on regular follow up guides clinical decisions and prognosis.

Conclusion

This study highlights the convenience and diagnostic efficiency of cranial ultrasound in high risk neonates in NICU. It also emphasizes its use as a screening modality for high risk preterm and term neonates influencing their neuro-developmental outcome which is particularly important in the anticipation of potential preventive, protective, and rehabilitative strategies for the management of critically ill newborn infants.

The study concludes that CUS is critical as an investigatory modality in NICU and effectively documents morphology of brain damage. Finally, individualized protocols need to be laid down in the NICU for CUS based on the neonatal work load and the available resources.

References

1. Gerda van Wezel-Meijler. Cranial Ultrasonography: Advantages and Aims Part 1, Neonatal Cranial Ultrasonography, 1st edn. Berlin: Springer, 2007, 3-4.
2. Bracci R, Perrone SN, Buonocore G. The Timing of Neonatal Brain Damage. *Biol Neonate* 2006; 90:145-155
3. Mosby's Medical Dictionary, 8th edition, Elsevier, 2009
4. De Vries LS, Groenendaal F. Neuroimaging in the preterm infant. *Ment Retard Dev Disabil Res Rev.* 2002; 8:273-280.
5. Volpe JJ. ed Hypoxic-ischemic encephalopathy: clinical aspects. Neurology of the newborn. ed. Philadelphia: WB Saunders, 2001, 218-280.
6. De Vries LS, Cowan FM. Should cranial MRI screening of preterm infants become routine? *Nat Clin Pract Neurol.* 2007; 3(10):532-3.
7. De Vries LS, Eken P, Dubowitz LM, *et al.* The spectrum of Leukomalacia using cranial ultrasound. *Behav Brain Res.* 1992; 49:1-6.
8. Mack LA, Wright K, Hirsch JH, *et al.* Intracranial hemorrhage in premature infants: accuracy in sonographic evaluation. *AJR Am J Roentgenol.* 1981; 137: 245-250.
9. Pape KE, Bennett-Britton S, Szymonowicz W, Martin DJ, Fitz CR, Becker LE. Diagnostic accuracy of neonatal brain imaging: a postmortem correlation of computed tomography and ultrasound scans. *J Pediatr.* 1983; 102:275-280.
10. Levene MI. Measurement of the growth of the lateral ventricles in preterm infants with real-time ultrasound. *Arch Dis Child.* 1981; 56:900-904.
11. Virkola K. The lateral ventricle in early infancy. Thesis, Helsinki, (ISBN; 952-90012-9-0), 1988.

12. Stark JE, Seibert JJ. Cerebral artery Doppler ultrasonography for prediction of outcome after perinatal asphyxia. *J Ultrasound Med.* 1994; 13:595-600.
13. Eugenio Mercuri, Lilly Dubowitz, Sara Paterson Brown, Frances Cowan, *et al.* Incidence of cranial ultrasound abnormalities in apparently well neonates on a postnatal ward and neurological status correlation with antenatal and perinatal factors. *Arch Dis Child Fetal Neonatal Ed.* 1998; 79:185-189.