

Biometry of Talus as a forensic tool for biological profiling

Sankaranarayanan Govindarajan¹, Jagan Arokiaraj², Rajasekhar SSSN^{3*}, Aravindhan Karuppusamy⁴

¹⁻⁴ Department of Anatomy, J.I.P.M.E.R., Puducherry, India

*Corresponding Author: Rajasekhar SSSN

Abstract

Purpose: The purpose of the present study is to estimate the biological profile of an individual of the south Indian population from talus.

Material and methods: This study was carried out in 92 tali. (Right-48 & Left-44). Parameters such as talar Width, talar length, head neck length of the talus, trochlear length, trochlear breadth, height of the talar head, talus height. length of the posterior articular surface of the talus, breadth of the posterior articular surface of the talus were measured using digital vernier calipers.

Results: The morphometric parameters were expressed as mean \pm 2SD. The mean talar width, mean length of the posterior articular surface of the talus and mean trochlear length were relatively more on the left side. The mean talar length, mean talar height and mean trochlear breadth were relatively more on the right side. However, the mean head neck length, talar head height and mean breadth of the posterior articular surface of the talus were almost similar on right and left side. The mean talar height was measured as 28.19 ± 2.18 mm and 26.33 ± 2.64 mm on right and left side respectively, the difference being statistically different ($p < 0.05$).

Conclusions: Talus is the relatively better preserved bone making it one of the ideal candidates for use in developing the biological profile of an individual. Of multiple parameters of talus used during biological profiling, we found that the talar height was significantly different on right side from that of the left. Biometric parameters of talus will aid in objective categorization and determination of race for forensic purposes.

Keywords: biometry, forensic anthropology, subtalar joint, talus

Introduction

Talus is a centrally placed and a well-protected tarsal bone. Owing to its thick cortical shell and strong subcortical bony lamellae, it is one of the well preserved bone during skeletonization of the buried human remains [1, 2].

Various methods are employed by forensic anthropologist for the identification of age, sex, race and stature of an unidentified individual using the skeletal remains. The talus bone is one of the preferred bones for this purpose [3, 4].

The determination of age, sex, race and stature during biological profiling is done by metric and non-metric evaluation of skeletal remains. The non-metric assessment of bones and the interpretation of the results is highly subjective and is often error prone. However, the metric evaluation of skeletal remains is relatively error free with a greater degree of reproducibility of results [1].

The biometric categorization of bones for individual race in a population is the first step towards establishing the identity of an unknown individual. We aim to observe the measurements of talus which aid in establishing the racial affinity in bones of an unidentified individual.

Materials and Methods

A descriptive observational study was done that included the total number of 92 adult talus bones of unknown gender (48 right and 44 left) collected from the department of Anatomy, JIPMER, Puducherry, India during the period of 2017-2018. Bones with structural damage or deformity were excluded from the study. The following parameters were measured in the talus:

1. Talar width (TW).
2. Talar length (TL).

3. Head neck length of the talus (HNL).
4. Trochlear length (TrL).
5. Trochlear breadth (TrB).
6. Height of the talar head (HH).
7. Talus height (TH).
8. Length of the posterior articular surface of the talus (LPAS).
9. Breadth of the posterior articular surface of the talus (BPAS).

A digital vernier calipers was used for the measurements with the correction of 0.01mm. The measurements were taken thrice, non-consecutively, and the mean of three measurements of each parameter in a bone was taken for analysis.

Figure 1, 2, 3, 4, 5, 6, 7, 8, 9, 10 shows the talus bones used and its measurements were taken in this study.



Fig 1: Total talus used in this study

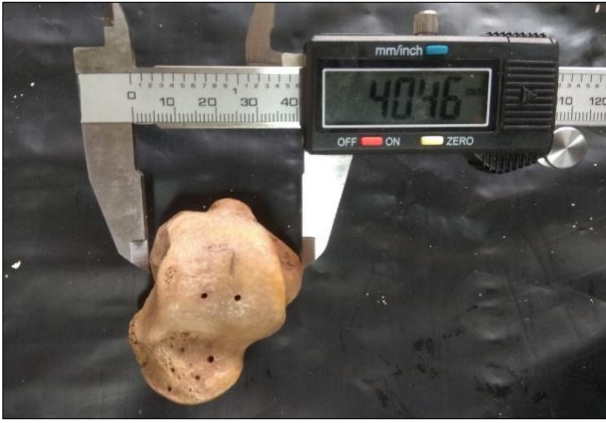

Fig 2: Talar width



Fig 6: Trochlear breadth



Fig 3: Talar length



Fig 7: Height of the talar head



Fig 4: Head neck length of the talus

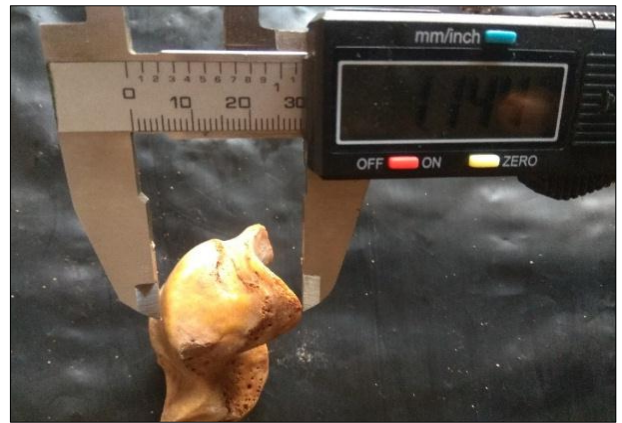


Fig 8: Talar height



Fig 5: Trochlear length



Fig 9: Length of the posterior articular surface of the talus



Fig 10: Breadth of the posterior articular surface of the talus

Statistical analysis

The Range, Mean, Standard deviation and *p* value of the above parameters were calculated using the IBM SPSS statistics for Windows, Version 25.0. The level of significance considered for this study is 5%, $\alpha = 0.05$.

Result

The mean talar width was 35.46 ± 2.82 mm on right side and 36.41 ± 2.58 mm on left side with the difference being statistically insignificant. The mean talar length was 49.94 ± 5.22 mm on right side and 41.22 ± 3.94 mm on left side with the difference being statistically insignificant. The mean head neck length was 20.13 ± 2.17 mm on right side and 20.61 ± 1.98 mm on left side with the difference being statistically insignificant. The mean trochlear length was 26.49 ± 4.22 mm on right side and 29.52 ± 3.22 mm on left side with the difference being statistically insignificant. The mean trochlear breadth was 27.38 ± 2.36 mm on the right and 26.93 ± 2.04 mm on left side with the difference being statistically insignificant. The mean height of the talar head was 22.64 ± 2.20 mm on right side and 22.36 ± 2.32 mm on left side with the difference being statistically insignificant. The mean talar height was 28.19 ± 2.18 mm on right side and 26.33 ± 2.64 mm on left side with the difference being statistically significant. The mean length of the posterior articular surface was 27.46 ± 4.87 mm on right side and 28.30 ± 2.29 mm on left side with the difference being statistically insignificant. The mean breadth of the posterior articular surface was 18.91 ± 1.78 mm on right side and 18.96 ± 1.46 mm on left side with the difference being statistically insignificant (Table 1-9).

Table 1: Statistical analysis between the right and left talus width

S. No.	No.	Side	Range (mm)	Mean Talar Width	Standard deviation	<i>p</i> value
1	48	Right	28.72 – 40.9	35.4692	2.8211	0.115
2	44	Left	31.2 – 43.24	36.4186	2.58914	

Table 2: Statistical analysis between the right and left talus length

S. No.	No.	Side	Range (mm)	Mean Talar Length	Standard deviation	<i>p</i> value
1	48	Right	23.64 – 58.14	49.941	5.22875	0.152
2	44	Left	43.82 – 60.54	41.2273	3.94317	

Table 3: Statistical analysis between the right and left head neck length of talus

S. No.	No.	side	Range (mm)	Mean head neck length	Standard Deviation	<i>p</i> value
1	48	Right	15.1 – 24.12	20.1398	2.17846	0.408
2	44	Left	17.08 – 25.9	20.6182	1.98459	

Table 4: Statistical analysis between the right and left trochlear length

S. No.	No.	Side	Range (mm)	Mean trochlear Length	Standard Deviation	<i>p</i> Value
1	48	Right	2.28 – 32.5	26.4931	4.22546	0
2	44	Left	22.7 – 37.4	29.5252	3.22206	

Table 5: Statistical analysis between the right and left trochlear breadth

S. No.	No.	Side	Range (mm)	Mean Trochlear Breadth	Standard Deviation	<i>p</i> Value
1	48	Right	23.37 – 32.8	27.3846	2.36322	0.521
2	44	Left	22.9 – 30.83	26.9348	2.04357	

Table 6: Statistical analysis between the right and left height of talar head

S. No.	No.	Side	Range (mm)	Mean height of the talar head	Standard Deviation	<i>p</i> Value
1	48	Right	18.68 – 31.31	22.6421	2.2071	0.72
2	44	Left	18.4 – 29.8	22.3695	2.3238	

Table 7: Statistical analysis between the right and left height of talus

S. No.	No.	Side	Range (mm)	Mean Height of the Talus	Standard Deviation	<i>p</i> value
1	48	Right	24.16 – 33.37	28.19	2.18177	0.003
2	44	Left	21 – 33.31	26.3391	2.6491	

Table 8: Statistical analysis between the right and left length of posterior articular surface

S. No.	No.	Side	Range (mm)	Mean length of posterior articular surface	Standard Deviation	<i>P</i> Value
1	48	Right	0.73 – 34.9	27.4694	4.87667	0.289
2	44	Left	23.4 – 35	28.3066	2.29478	

Table 9: Statistical analysis between the right and left Breadth of Posterior articular surface

S. No.	No.	Side	Range (mm)	Mean breadth of posterior articular surface	Standard deviation	<i>p</i> value
1	48	Right	15.08 – 23.46	18.9148	1.78091	0.973
2	44	Left	15.62 – 21.7	18.9605	1.46706	

Figures 11, 12, 13, 14, 15, 16, 17, 18, 19 shows the plotted distribution of biometric parameters of talus in the scattered diagrams.

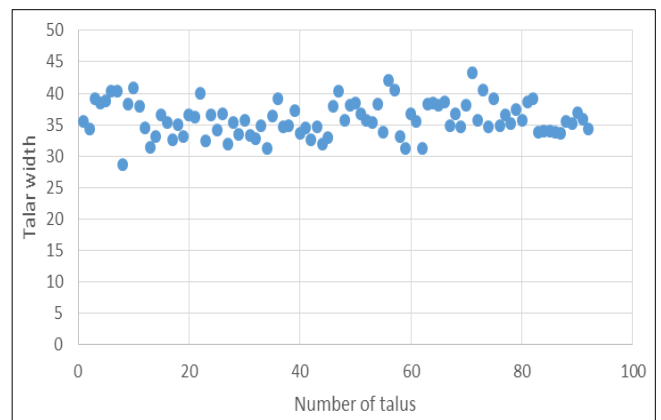


Fig 11: Distribution of biometry of talar width (in mm)

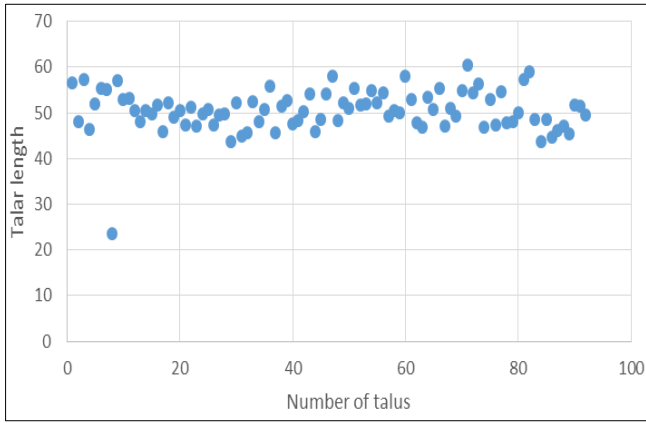


Fig 12: Distribution of biometry of talar length (in mm)

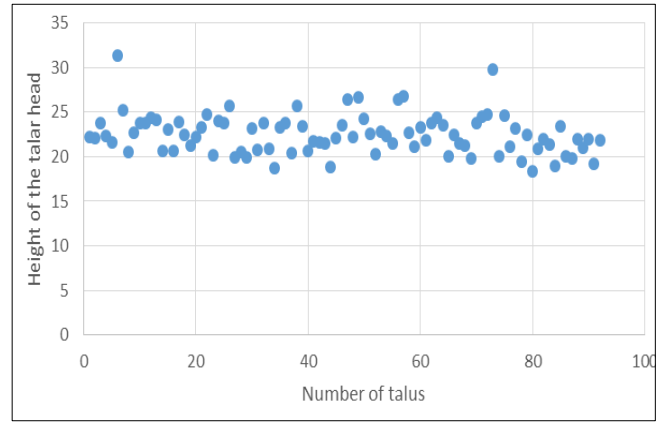


Fig 16: Distribution of biometry of talar head height (in mm)

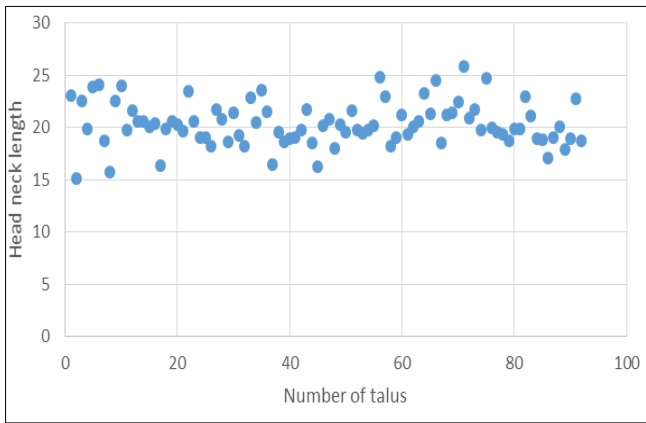


Fig 13: Distribution of biometry of head neck length of talus (in mm)

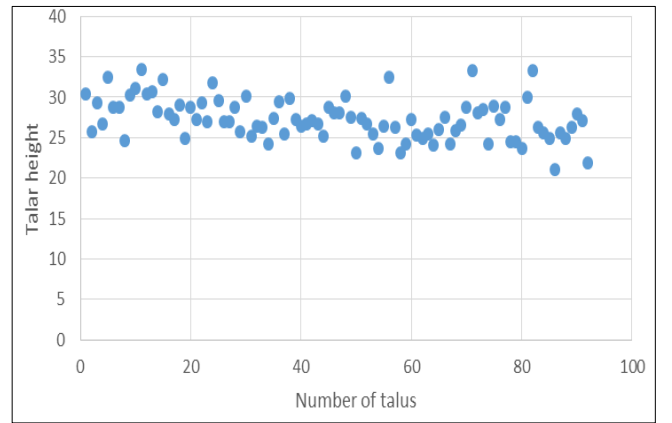


Fig 17: Distribution of biometry of talus height (in mm)

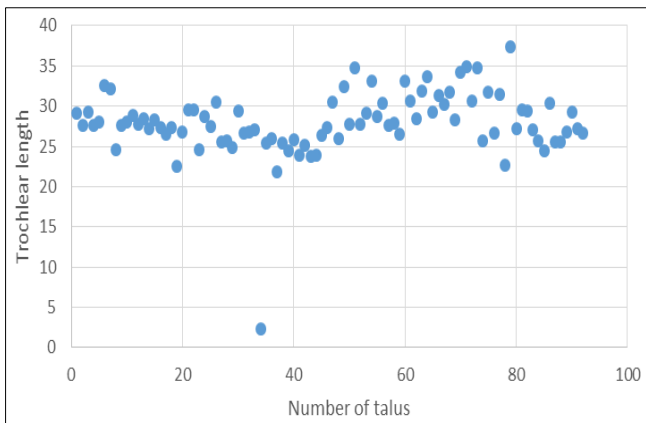


Fig 14: Distribution of biometry of trochlear length (in mm)

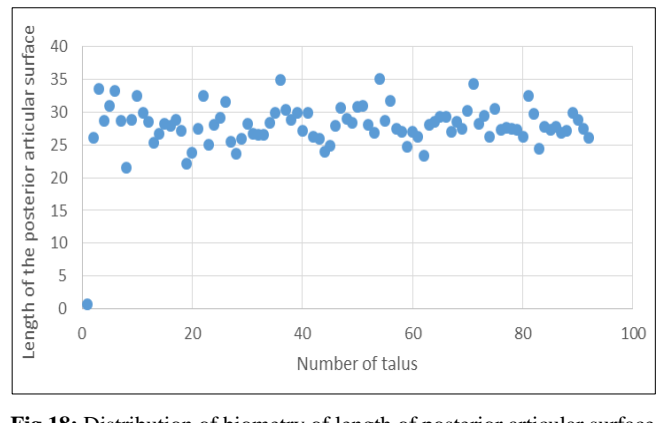


Fig 18: Distribution of biometry of length of posterior articular surface of talus (in mm)

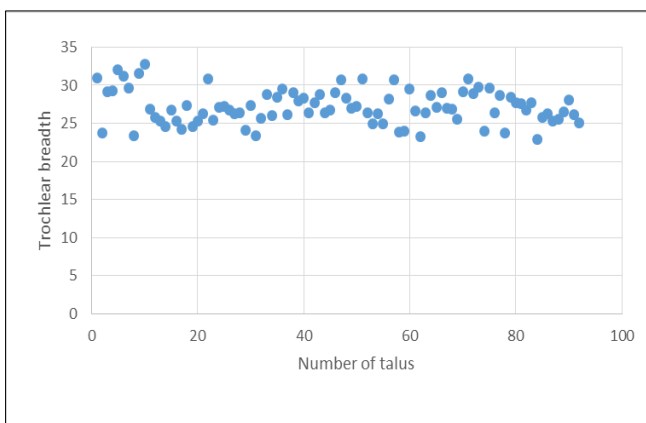


Fig 15: Distribution of biometry of trochlear breadth (in mm)

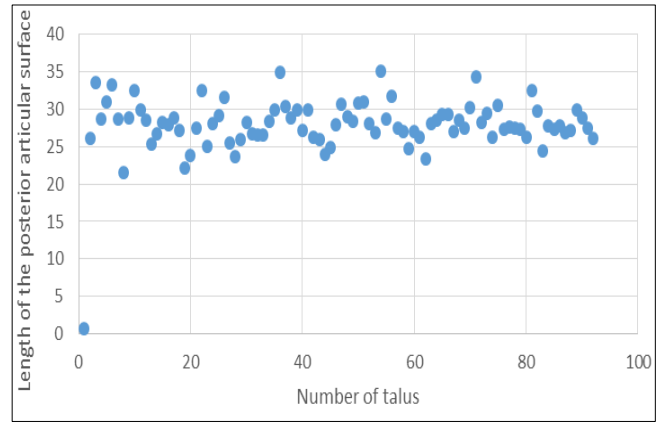


Fig 19: Distribution of biometry of breadth of the posterior articular surface of the talus (in mm)

Discussion

The articular surfaces on talus may vary according to the life style and diseases of the individual [6]. Hence, geometric measurements such as length, height, width, breadth of body, neck and trochlea of talus are more objective parameters for the racial identification.

i) Talar width

Talar width helps to identify the age, sexual dimorphism and racial differences [3,4]. The mean talar width was measured as 35.46 ± 2.82 mm on right side and 36.41 ± 2.58 mm on left side in the present study. In a study done by Mahakkanukrauh *et al.* [6], the mean talar width was reported as 39.21 ± 2.01 mm on right side and 39.20 ± 2.10 mm on left side. In a study done by Gualdi-Russo *et al.* [7], the mean talar width was reported as 40.8 ± 2.2 mm on right side and 40.95 ± 2.1 mm on left side. However, the mean talar width in the present study is comparatively less than the previous studies. But, there is no significant difference between right and left mean talar width in the present study and earlier studies.

The overall mean talar width including both the sides was measured as 35.93 ± 2.7 mm in the present study. The mean talar width was reported as 41.82 ± 2.42 mm by Bidmos *et al.* [2], 39.94 ± 2.32 mm by Peckmann *et al.* [1], 39.91 ± 2.82 mm by Abd-elaleem *et al.* [8], 40.63 ± 2.41 mm by Bidmos *et al.* [9], 39.20 ± 2.05 mm by Mahakkanukrauh *et al.* [6], 40.87 ± 2.15 mm by Gualdi-Russo *et al.* [7] and 37.9 ± 3.5 mm by Koshy *et al.* [10]. The mean talar width measured in the present study was significantly less than that reported by earlier studies.

ii) Talar Length

Talar length is the single best parameter helps to identify the age, sexual dimorphism and racial differences [3,4]. The mean talar length was measured as 49.94 ± 5.22 mm on right and 41.22 ± 3.94 mm on left side in the present study. In a study done by Mahakkanukrauh *et al.* [6], the mean talar length was reported as 53.7 ± 3.09 mm on right side and 53.4 ± 3.15 mm on left side. In a study done by Gualdi-Russo *et al.* [7], the mean talar length was reported as 52.65 ± 2.6 mm on right side and 52.7 ± 2.5 mm on left side. However, the mean talar length in the present study is comparatively less than the previous studies. There was significant difference between right and left mean Talar length in the present study, but there was no such significant difference reported in earlier studies. The overall mean talar length was measured as 45.58 ± 4.58 mm in the present study. The mean talar length was reported as 53.58 ± 2.87 mm by Bidmos *et al.* [2], 57.43 ± 3.41 mm by Peckmann *et al.* [1], 57.26 ± 4.48 mm by Abd-elaleem *et al.* [8], 53.36 ± 2.77 mm by Bidmos *et al.* [9], 53.55 ± 3.12 mm by Mahakkanukrauh *et al.* [6], 52.65 ± 2.55 mm by Gualdi-Russo *et al.* [7], and 52.8 ± 5.8 mm by Koshy *et al.* [10]. The mean talar length measured in the present study was significantly less than that reported in earlier studies.

iii) Head Neck Length

Fracture talus is the rare condition. Fracture neck of talus accounts for 50% of all fracture in the talus and also incidence of dislocated fracture neck leads to avascular necrosis. This is due to increased head neck length of the talus, narrow cross sectional area and presence of weak cortex at the neck of the talus [11]. The mean head neck length of the talus was measured as 20.37 ± 2.07 mm in the present study. The mean head neck length of the talus was reported as 22.53 ± 2.38

mm by Bidmos *et al.* [2], 19.2 ± 2.1 mm by Peckmann *et al.* [1], 27.84 ± 2.47 mm by Abd-elaleem *et al.* [8], and 22.66 ± 2.15 mm by Bidmos *et al.* [9]. However, the mean head neck length of the talus measured in the present study is almost equal to the study done previously except, Abd-elaleem *et al.* [8].

iv) Trochlear length

Trochlear length helps to identify the age, sexual dimorphism and racial differences [3,4]. The mean trochlear length was measured as 26.49 ± 4.22 mm on right side and 29.52 ± 3.22 mm on left side in the present study. In a study done by Mahakkanukrauh *et al.* [6], the mean trochlear length was reported as 32.35 ± 2.09 mm on right side and 32.31 ± 2.0 mm on left side. However, the mean trochlear length in the present study is comparatively less than the study done by Mahakkanukrauh *et al.* [6]. There is a significant difference between right and left mean trochlear length in the present study whereas no difference between right and left trochlear length of the talus was seen in the study done by Mahakkanurkrauh *et al.* [6].

The mean trochlear length of the talus was measured as 28 ± 3.72 mm in the present study. The mean trochlear length of the talus was reported as 33.94 ± 2.54 mm by Bidmos *et al.* [2] 32.77 ± 2.41 mm by Peckmann *et al.* [1] 37.61 ± 3.15 mm by Abd-elaleem *et al.* [8] 33.94 ± 2.57 mm by Bidmos *et al.* [9], and 32.33 ± 2.04 mm by Mahakkanukrauh *et al.* [6]. The mean trochlear length of the talus in the present study was significantly less than that reported in the earlier studies.

v) Trochlear breadth

Trochlear breadth helps to identify the age, sexual dimorphism and racial differences [3,4,12]. The mean trochlear breadth was measured as 27.34 ± 2.6 mm on right side and 26.93 ± 2.04 mm on left side in the present study. In a study done by Mahakkanukrauh *et al.* [6], the mean trochlear breadth was reported as 27.7 ± 1.62 mm on right side and 27.58 ± 1.73 mm on left side. However, the mean trochlear breadth in the present study is almost equal to observation made by Mahakkanukrauh *et al.* [6]. However, there was no significant difference between mean trochlear breadth of right and left sides in the present study and in a study done by Mahakkanurkrauh *et al.* [6].

The mean trochlear breadth of the talus was measured as 27.15 ± 2.2 mm in the present study. The mean trochlear breadth of the talus was reported as 31.55 ± 1.71 mm by Bidmos *et al.* [2], 30.42 ± 1.74 mm by Peckmann *et al.* [1], 33.15 ± 4.35 mm by Abd-elaleem *et al.* [8], 31.24 ± 1.71 mm by Bidmos *et al.* [9], and 27.64 ± 1.67 mm by Mahakkanukrauh *et al.* [6]. The mean trochlear breadth of the talus in the present study was almost similar to the measurements observed by Mahakkanukrauh *et al.* and less than the studies reported previously.

vi) Height of the talar head

Decrease in the talar head height with increase in concavity of navicular articular surface leads to collapse of medial longitudinal arch (Flat foot deformity) [5]. The mean height of the talar head was measured as 22.5 ± 2.26 mm in the present study. The mean height of the talar head was reported as 26.85 ± 2.19 mm by Bidmos *et al.* [2] 27.08 ± 2.61 mm by Peckmann *et al.* [1], 27.91 ± 2.41 mm by Bidmos *et al.* [9] and 20.1 ± 3.2 mm by Koshy *et al.* [10]. The mean talar head height observed in the present study was significantly less than that

reported by the other authors except for Koshy *et al.* [10].

vii) Talar height

Talar height foot length ratio will help in classifying the degree of cavus foot (High arched foot) in medial longitudinal arch [13]. Increase in talar height above normal limits may be associated with pes planus, which in turn results in increased affinity to stress fractures of metatarsals including femoral and tibial stress injuries [13]. The mean talar height was measured as 28.19 ± 2.18 mm on right side and 26.33 ± 2.64 mm on left side in the present study. In a study done by Mahakkanukrauh *et al.* [6], the mean talar height was reported as 30.22 ± 1.66 mm on right side and 30.19 ± 1.79 mm on left side. In a study done by Gualdi-Russo *et al.* [7], the mean talar height was reported as 30.65 ± 1.6 mm on right side and 30.9 ± 1.45 mm on left side. However, the mean talar height in the present study was comparatively less than the previous studies. But, there is no significant difference between right and left mean talar height in the present study and in earlier studies.

The mean talar height was measured as 27.26 ± 2.41 mm in the present study. The mean talar height was reported as 32.2 ± 2.01 mm by Bidmos *et al.* [2], 31.05 ± 2.13 mm by Peckmann *et al.* [1], 35.38 ± 3.47 mm by Abd-elaleem *et al.* [8], 32.08 ± 2.1 mm by Bidmos *et al.* [9], 30.77 ± 1.52 mm by Gualdi-Russo *et al.* [7], and 30.22 ± 1.72 mm by Mahakkanukrauh *et al.* [6]. The mean talar height in the present study is significantly less than the earlier reported studies.

viii) Length of the posterior articular surface

The length and breadth of the posterior articular surface is important to understand the dimensions of the subtalar joint and subtalar joint instability, which in turn leads to the ankle joint osteoarthritis and other hind foot disorders [7]. The mean length of the posterior articular surface of the talus was measured as 27.88 ± 3.58 mm in the present study. The mean length of the posterior articular surface was reported as 34.33 ± 2.17 mm by Bidmos *et al.* [2], 31.84 ± 1.91 mm by Peckmann *et al.* [1], 24.88 ± 3.4 mm by Abd-elaleem *et al.* [8], and 33.13 ± 2.21 mm by Bidmos *et al.* [9]. The mean length of the posterior articular surface of the talus in the present study was significantly less than the observations made in the previous studies except, Abd-elaleem *et al.* [8].

ix) Breadth of the posterior articular surface

The mean breadth of the posterior articular surface of the talus was measured as 18.93 ± 1.62 mm in the present study. The mean breadth of the posterior articular surface was reported as 22.50 ± 1.85 mm by Bidmos *et al.* [2], 21.62 ± 1.73 mm by Peckmann *et al.* [1], 37.97 ± 4.75 mm by Abd-elaleem *et al.* [8], and 21.7 ± 1.93 mm by Bidmos *et al.* [9]. The mean breadth of the posterior articular surface of the talus in the present study was significantly less than the studies done previously.

In all previous studies, most of the variables measured in males were greater than females with few exceptions. However, the following variables have a significant difference between males and females and can be used for determination of sex.

Significant difference between male and female was found in 1. Talar length and head height as reported by Bidmos *et al.* [2].

2. Talar length and talar width as reported by Peckmann *et al.* [1].
3. Talar length, talar width and neck width of the talus as reported by Abd-elaleem *et al.* [8].
4. Talar length, talar width and breadth of the posterior articular surface of the talus as reported by Bidmos *et al.* [9].
5. Trochlear length and trochlear breadth as reported by mahakkanukrauh *et al.* [6].
6. But, no significant difference found in all variables as reported by Koshy *et al.* [10].

In majority of the previous studies, among all the variables measured, it was observed that the talar length is the best single variable to differentiate males and females.

Embryology

During the 8th week of development, the primordial subtalar joint appears between the cartilaginous precursors of talus and calcaneum. During the 9th week of development, the subtalar joint further cavitates, with posterior part developing rapidly than the anterior part. During the 10th week of development, the development of posterior part of talus nears completion. Sinus tarsi and tarsal canal are fully developed by the 11th week of development. The subtalar joint along with articulating surface of the talus and calcaneum and other capsule-ligamentous structure are completely formed by 14th week of development [16, 17, 18].

Clinical application

Talus is only tarsal bone that has no muscle, fascial and tendinous attachments. It acts as bony meniscus between tarsal bones by transmitting the weight from the crural region to the plantar regions. Talus is one of the common bones used by forensic anthropologists for estimation of age, sexual dimorphism, racial differences, and stature identification [3, 4]. Race specific knowledge of biometric parameters of talus will be useful during total ankle replacement (ankle brace designing) [19], implant designing [6], testing the mechanical strength of artificial prosthesis of talus in avascular necrosis [20, 21]. Normal measurements of talus are useful during surgical approach for fracture neck of talus, alignment of talus in congenital talipes equino varus, to identify the degrees of pes cavus and pes planus [15, 22, 23].

Conclusions

Talus is the relatively better preserved bone making it one of the ideal candidates for use in developing the biological profile of an individual. Out of nine metric parameters measured in talus bones belonging to south Indian population, the mean of each parameter was similar in case of right side as well as the left side, except for one parameter. There is a statistically significant difference between right and left side tali with respect to talar height. The findings of the present study especially the talar height of the right and left sides will be useful during racial profiling of bones of unidentified individuals, assessment of traumatic talus, during surgery of talus and for designing talar prosthesis for the south Indian population. Biometric parameters of talus as a whole will aid in objective categorization and determination of race for forensic purposes.

Conflict of interest

The authors declares that they have no conflict of interest.

References

1. Peckmann TR, Orr K, Meek S, Manolis SK. Sex determination from the talus in a contemporary Greek population using discriminant function analysis. *J. Forensic Leg. Med.* 2015; 33:14-9.
2. Bidmos MA, Dayal MR, Adegbeye OA. Measurements of the talus in the assessment of population affinity. *Forensic Sci. Int.* 2018; 287: 221:e1-221.e7.
3. Holland TD. Estimation of adult stature from the calcaneus and talus. *Am. J. Phys. Anthropol.* 1995; 96(3):315-20.
4. Dixit SG, Kaur J, Kakar S. Racial variation on articular surface of talus (astragalus) in North Indian population. *J. Forensic Leg. Med.* 2012; 19(3):152-7.
5. Riccio I, Gimigliano F, Gimigliano R, Porpora G, Iolascon G. Rehabilitative treatment in flexible flatfoot: a perspective cohort study. *musculoskeletal surgery. Chir Organi Mov.* 2009; 93(3):101-7.
6. Mahakkanukrauh P, Praneatpolgrang S, Ruengdit S, Singsuwan P, Duangto P, Case DT. Sex estimation from the talus in a Thai population. *Forensic Sci. Int.* 2014; 240: 152.e1-152.e8.
7. Gualdi-Russo E. Sex determination from the talus and calcaneus measurements. *Forensic Sci. Int.* 2007; 171(2-3):151-6.
8. Abd-elaleem SA, Abd-elhameed M, Ewis AA. Talus measurements as a diagnostic tool for sexual dimorphism in Egyptian population. *J. Forensic Leg. Med.* 2012; 19(2):70-6.
9. Bidmos MA, Dayal MR. Sex Determination from the Talus of South African Whites by Discriminant Function Analysis: *Am. J. Forensic Med. Pathol.* 2003; 24(4):322-8.
10. Koshy S, Vettivel S, Selvaraj K. Estimation of length of calcaneum and talus from their bony markers. *Forensic Sci. Int.* 2002; 129(3):200-4.
11. Azeez DA, NDS, Reddy DVN. Management of Fracture Neck of Talus and Clinical Evaluation. *Int. J. Orthop. Sci.* 2018; 4(3.1):16-21.
12. Javia M, Patel M. Morphometric analysis of various measurements of trochlear articular surface of talus of Gujarati population on the basis of sexual dimorphism and racial differences. *Int J Ant Res.* 2017; 5(3.1):4100-5.
13. Saltzman CL, Nawoczinski DA, Talbot KD. Measurement of the medial longitudinal arch. *Arch Phys Med Rehabil.* 1995; 76(1):45-9.
14. Krähenbühl N, Horn-Lang T, Hintermann B, Knupp M. The subtalar joint: A complex mechanism. *EFORT Open Reviews.* 2017; 2(7):309-16.
15. Ughade HM, Bhele AV, Shaikh S. Morphometric study of human talus - a cross sectional study. *Int J Ant Res.* 2017; 5(3.2):4265-8.
16. Fazal-ur-Rehman, Faruqi NA. Morphometric Changes in Talus of Club Foot a Gross Observation in Human Foetuses. *Int J Morphol.* 2012; 30(1):217-21.
17. Irani RN, Sherman MS. The Pathological Anatomy of Club Foot. *Clin. Orthop. Relat. Res.* 1972; 84:14-20.
18. Canavese F, Dimeglio A, Bonnel F. Postoperative CT-scan reconstruction of the calcaneus following lateral calcaneal lengthening osteotomy for flatfoot deformity in children. Is the surgical procedure potentially associated with subtalar damage? *Foot Ankle Surg.* 2017, <https://doi.org/10.1016/j.fas.2017.05.005>.
19. Janaki DV. Morphometry of Articular Facets of the Body of Talus. *IOSR-JDMS.* 2017; 16(05):19-21.
20. Islam K, Dobbe A, Komeili A, Duke K, El-Rich M, Dhillon S, *et al.* Symmetry analysis of talus bone: A Geometric morphometric approach. *Bone Joint Res.* 2014; 3(5):139-45.
21. Shetty Y. A study of morphometry of articular surface of talus. *GJRA.* 2018; 7(9):18.
22. Peeters K, Schreuer J, Burg F, Behets C, Van Bouwel S, Dereymaeker G, *et al.* Altered talar and navicular bone morphology is associated with pes planus deformity: A CT-scan study. *J. Orthop. Res.* 2013; 31(2):282-7.
23. Yu-Chi Huang. The relationship between the flexible flatfoot and plantar fasciitis: Ultrasonographic evaluation. *Chang Gung Med J.* 2004; 27:443-447.