

Study of fatty liver disease

Dr. Gaurav Pandey¹, Dr. Supriya Sharma^{2*}

^{1,2}Career Institute of Medical Sciences and Hospital, Lucknow, Uttar Pradesh, India

*Corresponding Author: Dr. Supriya Sharma

Abstract

There are hardly any studies to assess the prevalence in the rural regions of India. This study aims at assessing the prevalence of disease in rural areas of north India by targeting a small rural sector from north India. It also aims at identifying the potential risk factors associated with the disease in such a population.

The ages of the patients are from 20-50 years. The data of the 320 patients undergone ultrasound scan for abdominal problems were collected. From these 50 patients were identified as having fatty liver diseases.

The observation of fatty liver diseases in the selected patients is high. The prevalence of fatty liver diseases is more in females compared to males. It confirms the presence of risk factors such as: increased BMI, fasting blood glucose, and serum triglycerides, and the presence of metabolic syndrome in these patients. There is a compelling need for a reliable biomarker to differentiate hepatic steatosis from steatohepatitis. Ultrasonography remains the diagnostic tool of choice for detecting NAFLD in the rural setting even today.

Keywords: fatty liver, north Indian patients, ALT, AST

Introduction

Fatty liver, or hepatic steatosis, is a term that describes the build up of fat in the liver. It's normal to have small amounts of fat in your liver, but too much can become a health problem.

The liver is the second largest organ in the body. It's responsible for a wide variety of functions, including processing everything we eat and drink, and filtering harmful substances from the blood. Too much fat in the liver can lead to long-term liver damage. View a body map of the liver and learn more about its function. Build-up of fat in the liver leads to a fatty liver. Having small amounts of fat in your liver is normal. A fatty liver is categorized by an abnormal accumulation of fat in the liver. Too much fat in the liver can lead to the development of a series of diseases including liver cancer, cirrhosis, liver scarring and end-stage liver disease [1]. Nonalcoholic steatohepatitis or NASH is a common, often "silent" liver disease. It resembles alcoholic liver disease, but occurs in people who drink little or no alcohol. The major feature in NASH is fat in the liver, along with inflammation and damage. Most people with NASH feel well and are not aware that they have a liver problem. Nevertheless, NASH can be severe and can lead to cirrhosis, in which the liver is permanently damaged and scarred and no longer able to work properly.

NASH affects 2 to 5 percent of Americans. An additional 10 to 20 percent of Americans have fat in their liver, but no inflammation or liver damage, a condition called "fatty liver." Although having fat in the liver is not normal, by itself it probably causes little harm or permanent damage. If fat is suspected based on blood test results or scans of the liver, this problem is called nonalcoholic fatty liver disease (NAFLD). If a liver biopsy is performed in this case, it will show that some people have NASH while others have simple fatty liver. Both NASH and NAFLD are becoming more common, possibly because of the greater number of Americans with

obesity. In the past 10 years, the rate of obesity has doubled in adults and tripled in children. Obesity also contributes to diabetes and high blood cholesterol, which can further complicate the health of someone with NASH. Diabetes and high blood cholesterol are also becoming more common.

NASH is usually first suspected in a person who is found to have elevations in liver tests that are included in routine blood test panels, such as alanine aminotransferase (ALT) or aspartate aminotransferase (AST). When further evaluation shows no apparent reason for liver disease (such as medications, viral hepatitis, or excessive use of alcohol) and when x rays or imaging studies of the liver show fat, NASH is suspected. The only means of proving a diagnosis of NASH and separating it from simple fatty liver is a liver biopsy. For a liver biopsy, a needle is inserted through the skin to remove a small piece of the liver. NASH is diagnosed when examination of the tissue with a microscope shows fat along with inflammation and damage to liver cells. If the tissue shows fat without inflammation and damage, simple fatty liver or NAFLD is diagnosed. An important piece of information learned from the biopsy is whether scar tissue has developed in the liver. Currently, no blood tests or scans can reliably provide this information [2].

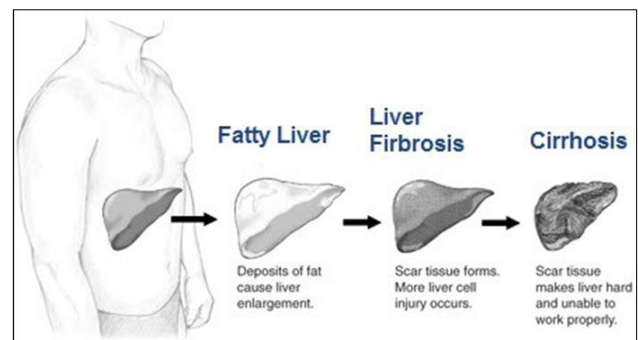


Fig 1

Liver disease with extensive inflammation and a high degree of steatosis often progresses to more severe forms of the disease [3]. Hepatocyte ballooning and necrosis of varying degrees are often present at this stage. Liver cell death and inflammatory responses lead to the activation of stellate cells, which play a pivotal role in hepatic fibrosis. The extent of fibrosis varies widely. Perisinusoidal fibrosis is most common, especially in adults, and predominates in zone 3 around the terminal hepatic veins [4].

Based on the literature findings the current study was planned. There are hardly any studies to assess the prevalence in the rural regions of India. This study aims at assessing the prevalence of disease in rural areas of north India by targeting a small rural sector from north India. It also aims at identifying the potential risk factors associated with the disease in such a population.

Materials and methods

The present study was planned in Career Institute of Medical Sciences And Hospital, Lucknow. The total 50 patients referred to Out-Patient Department (OPD) and in-patient department (IPD). The aim and the objective of the study were conveyed to patients. Approval of the institutional committee was taken prior to conduct of study.

The ages of the patients are from 20-50 years. The data of the 320 patients undergone ultrasound scan for abdominal problems were collected. From these 50 patients were identified as having fatty liver diseases.

Results and Discussion

The 50 patients were identified as having fatty liver diseases out of the 320 patients undergone ultrasound scan for abdominal problems.

Table 1: Demographic Details

| | | Number of Cases |
|-----------------------------|---------|-----------------|
| Number of Cases | | 50 |
| Age of the Patients (years) | | 20 - 50 |
| Gender | Males | 31 |
| | Females | 19 |
| Waist (Cm) | | 65 – 78 |
| BMI (kg/cm2) | | 22.2 – 28.3 |

Table 2: Liver Enzyme & Elevated levels

| Parameters | Number of Cases |
|--------------|-----------------|
| Elevated ALT | 28 |
| Elevated AST | 22 |
| Total | 50 |

The age of the study group patients are 20 to 50 years. The increases level of the ALT was seen in 28 patients out of 50 patients. The Body mass index of all the patients was detected from 22.2 – 28.3 kg/m². The prevalence of the Non-alcoholic fatty liver diseases were 20% from all the patients undergone the study. Out of the 50 patients having fatty liver diseases 25 were females. The age group of the patients was observed is 20-50 years. The fatty liver diseases patients are also having the elevated sugar levels.

Several biomarkers have been used as tools to diagnose NAFLD, though none of them is specific. Alanine aminotransferase is the primary and inexpensive test for NAFLD. Mild elevation of serum aminotransferase levels is seen in patients with NAFLD, but liver enzymes may be normal in up to 78% of patients [5]. The ratio of AST/ALT is

usually less than 1 in patients who have normal liver or minimal fibrosis, although this ratio may be greater than 1 with the development of cirrhosis [6]. It is a known fact that the degree of ALT elevation does not correlate with the presence or severity of histological findings of NAFLD [7].

The Fatty liver is detected by CT scan or ultrasound sonography of the abdomen [8]. The uneven fat distribution in the liver results in lesser the sensitivity of these techniques to 60% [9-10]. The sensitivity of the detections may be increased to 80 to 90% when more than half are hepatocytes in the image region.

The overweight and obesity are the simultaneous occurring factors responsible for the fatty liver diseases. This is in-line with the finding of this study. Fatty liver diseases mainly represent the abdominal discomfort.

Conclusion

The observation of fatty liver diseases in the selected patients is high. The prevalence of fatty liver diseases is more in females compared to males. It confirms the presence of risk factors such as: increased BMI, fasting blood glucose, and serum triglycerides, and the presence of metabolic syndrome in these patients. There is a compelling need for a reliable biomarker to differentiate hepatic steatosis from steatohepatitis. Ultrasonography remains the diagnostic tool of choice for detecting NAFLD in the rural setting even today.

References

1. <https://www.practo.com/health-wiki/fatty-liver-symptoms-complications-and-treatment/232/article>
2. [https://surgery.ucsf.edu/conditions--procedures/fatty-liver-disease-\(nonalcoholic-steatohepatitis\).aspx](https://surgery.ucsf.edu/conditions--procedures/fatty-liver-disease-(nonalcoholic-steatohepatitis).aspx)
3. Gramlich T, Kleiner DE, McCullough AJ, Matteoni CA, Boparai N, Younossi ZM. Pathologic features associated with fibrosis in nonalcoholic fatty liver disease. *Hum. Pathol.* 2004; 35(2):196. Doi:10.1016/j.humpath.2003.09.018. PMID 14991537.
4. Zafrani ES. Non-alcoholic fatty liver disease: an emerging pathological spectrum. *Virchows Arch.* 2004; 444(1):3-12. Doi: 10.1007/s00428-003-0943-.PMID 14685853.
5. Browning JD, Szczepaniak LS, Dobbins R. Prevalence of hepatic steatosis in an urban population in the United States: impact of ethnicity. *Hepatology.* 2004; 40(6):1387-95.
6. Angulo P, Keach JC, Batts KP, Lindor KD, Independent predictors of liver fibrosis in patients with non-alcoholic steatohepatitis. *Hepatology.* 1999; 30(6):1356-62.
7. Nobili V, Reale A, Alisi A. Elevated serum ALT in children presenting to the emergency unit: relationship with NAFLD. *Dig Liver Dis.* 2009; 41:749-52.
8. Zwiebel WJ. Sonographic diagnosis of diffuses liver disease. *Br J radiol.* 1992; 65:774-778.
9. Foster KJ, Dewbury KC, Griffith AH *et al.* The accuracy of ultra sound in the detection of fatty infiltration of the liver. *BRJ Radiol.* 1980; 53:440-442.
10. Matsui O, Kadoya M, Takahashi, *et al.* Focal sparing of segment IV in fatty liver shown by sonography and CT. *AJR.* 1995; 164:1137-1140.