



Use of ultrasound diagnosis for assessment of focal hepatic lesions in PMCH

Dr. Rajiv Kumar¹, Dr. Kishan Kumar Thakur^{2*}

¹ Associate professor, Department of Radiology, Patna Medical College and Hospital, Patna, Bihar, India

² Junior Resident (2nd Year) MD Radiodiagnosis, Patna Medical College and Hospital, Patna, Bihar, India

Corresponding Author: Dr. Kishan Kumar Thakur*

Abstract

The study to assess the role of ultrasound in estimation of focal hepatic lesions was planned in Patna Medical College and Hospital. Total 50 patients in age group of 25-65 years were enrolled in to the study. Liver was scanned in various planes. Various ultrasonographic features of focal liver lesions were observed. The maximum ultrasound diagnoses were confirmed by the CT scan. The main aim of the present study is to assess the role of ultrasound in estimation of focal hepatic lesions.

The primary function of investigating a focal liver lesion is to characterise it with confidence as either needing no or only routine follow-up, or needing further, more rigorous exploration (including biopsy). The exclusion of malignancy is paramount, and most benign lesions can be characterised on non-invasive imaging grounds alone. Conventional ultrasonography is often used as the first line imaging investigation.

High degree of sensitivity and specificity of ultrasonographic diagnosis in the present study confirms the value of ultrasonographic evaluation of focal liver lesions and suggests that it can be effectively used in the routine diagnostic work.

Keywords: focal liver lesions, liver abscess, metastasis, ultrasound

1. Introduction

Focal liver lesions are common in the general population. Radiology (imaging) plays a pivotal role for the diagnosis, staging, treatment planning, and follow-up of focal liver lesions. To maximize lesion detection and characterization, imaging needs to be performed with appropriate equipment by using protocols carefully designed on the basis of the underlying clinical context. In addition, the decision of an imaging modality cannot be based on the diagnostic accuracy of an imaging test solely but must also consider patient safety and cost-effectiveness.

Because of a combination of high spatial resolution and inherent soft tissue contrast, lack of ionizing radiation, low cost, and wide availability, ultrasonography (US) is frequently the first-line imaging modality for the study of the liver. Operator dependency, substantial image degradation in obese patients, and limited field of view, however, represent major limitations of this modality compared with other cross-sectional imaging techniques. Common benign lesions, such as cysts and haemangiomas, usually have a characteristic appearance on US, often obviating other evaluation in non-oncology patients.

The liver presents with a variety of lesions for evaluation and appropriate triage with imaging. Ultrasound, MDCT and particularly MRI play a significant role in this objective. In patients without a known malignancy the vast majority of non-cystic lesions are benign (haemangioma, FNH, adenoma, focal fat, etc.), while a few are malignant. However, common benign hepatic lesions may pose a dilemma, if their imaging features are atypical. Although patients with a known malignancy are more likely to have a diagnosis of metastasis for a liver lesion, some studies have shown that small (<1cm) hepatic lesions are more likely to be benign even in patients with a cancer diagnosis [1, 2]. While metastases may be a common diagnosis in cancer, it is

important to recognise varied patterns of liver metastases after chemotherapy or after surgery. Chemotherapy-related focal or nodular fat deposition can also lead to variety of pseudolesions and one needs to be aware of these appearances and distinguish them from fat-containing hepatic tumors [3]. Uncommon occurrence of hepatic peliosis and sinusoidal obstruction syndrome also needs to be kept in mind in patients with cancer [1].

More recently, with the introduction of microbubble contrast agents, contrast-enhanced US (CEUS) offers the unique capability to perform continuous, real-time assessment of normal hepatic parenchyma, hepatic vessels, and liver lesions [2]. This extends the temporal window of a dynamic imaging study beyond the limits of standard contrast-enhanced computed tomography (CT) and magnetic resonance imaging (MRI) examinations, which are able to display static views only.

Although still under scrutiny, CEUS can be clinically useful in the investigation of rapidly enhancing hepatic tumors such as capillary haemangioma, focal nodular hyperplasia, hepatic adenoma, hepatocellular carcinoma, and metastases [3-5].

Focal liver lesions (FLLs) are a common reason for consultation to a hepatobiliary service, they often need further work up, and investigations. They are often discovered in patients with a cirrhotic liver or colorectal cancer but can be found incidentally during work up for abdominal pain and sometimes in the trauma setting [2].

Various imaging methods incidentally show focal liver lesions. The primary function of investigating a focal liver lesion is to characterise it with confidence as either needing no or only routine follow-up, or needing further, more rigorous exploration (including biopsy). The exclusion of malignancy is paramount, and most benign lesions can be characterised on non-invasive imaging grounds alone. Conventional ultrasonography is often used as the first line

imaging investigation.

Hence from the above literature findings the present study was planned. The main aim of the present study is to assess the role of ultrasound in estimation of focal hepatic lesions.

Methodology

The study to assess the role of ultrasound in estimation of focal hepatic lesions was planned in Patna Medical College and Hospital from the duration of Jan 2017 to July 2018. Informed consent was obtained from all the patients and the aim and the purpose of the present study were clearly mentioned to them. Total 50 patients having age group of 25-65 years were enrolled in to the study. Liver was scanned in various planes. Various ultrasonographic features of focal liver lesions were observed. The maximum ultrasound diagnoses were confirmed by the CT scan.

The inclusion criteria include the Cases of focal hepatic lesions detected by ultrasound during the study period. The Exclusion criteria include the diffuse fatty infiltration, Storage disorders, Cirrhosis of liver and Diffuse infiltrative malignancies, lymphoma and leukemia.

Results & Discussion

The present study planned to evaluate the role of ultrasound in estimation of focal hepatic lesions is planned in Patna

Medical College and Hospital. The maximum ultrasound diagnoses were confirmed by the CT scan. The study was planned to collect the data from the 50 patients. The focal liver lesions studied by ultrasound technique.

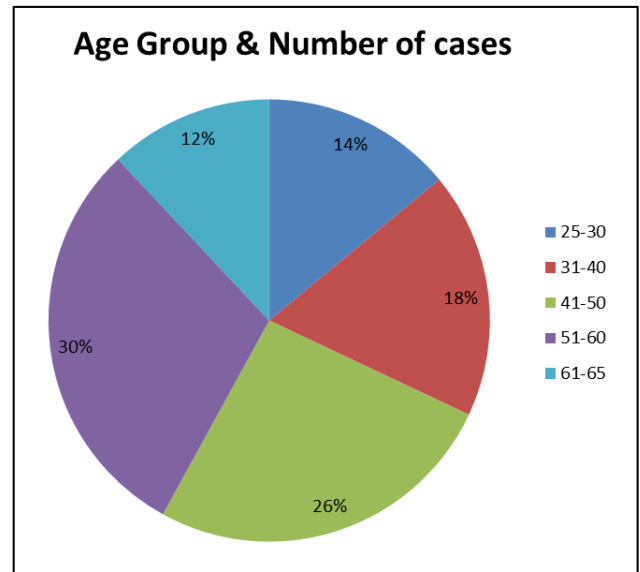


Fig 1: Age distribution of focal liver lesion




Fig 2: Distribution of Cases diagnosed by Ultrasound with CT scan

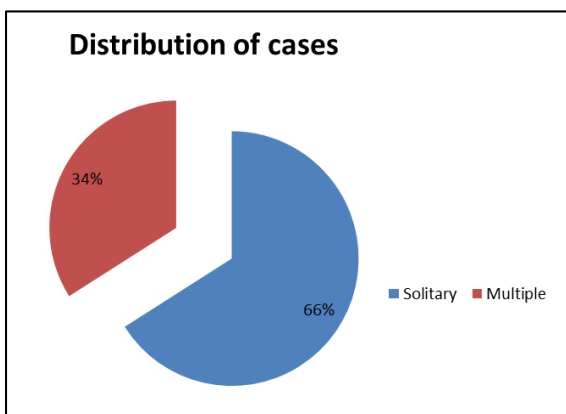


Fig 3: Distribution of cases based on number of focal lesions

There are total 33 solitary type and 17 multiple type of focal lesions were observed. According to distribution of the lobe there are 30 cases of right, 8 cases of left and 12 cases of both sides were reported.

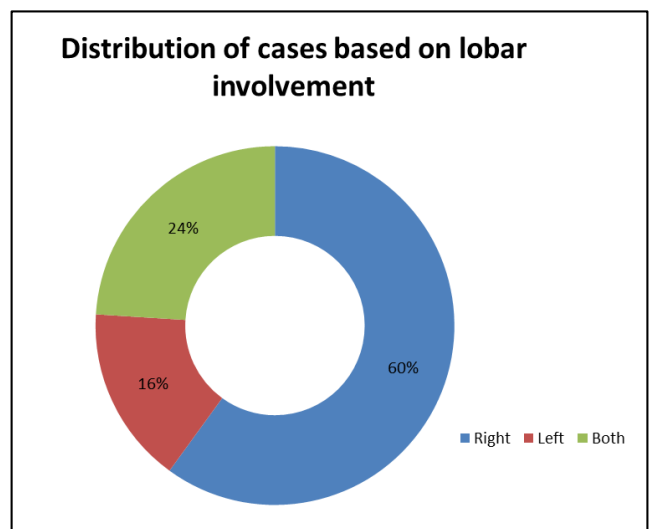


Fig 4: Distribution of cases based on lobar involvement

Ultrasonography has been an accepted method for the diagnosis of focal liver lesions because of its rapidity of diagnosis and its high sensitivity. Ultrasound features of focal liver lesions were studied and diagnosis was confirmed by fine needle aspiration cytology or CT scan. The various focal liver lesions encountered in the study were liver abscess, metastasis, primary malignant liver tumors, haemangiomas, cystic and hydatid lesions, Liver contusions and lacerations [6-8].

CT scan is one of the essential imaging studies of focal liver lesions. The protocol and ability to acquire a multiphase study is paramount in characterizing liver lesions. Triphasic images are the method of choice, which give a significant improvement in the result compared to single-phase studies [9]. The ability for three-dimensional reconstruction helps in assessing the vascular anatomy, the liver and tumor volumes. It also provides a good screening tool to the rest of the abdomen as well as to stage a malignant pathology. Differentiation between benign and malignant conditions is based on the degree of uptake of the contrast agent at different phases of the study. For example, hepatocellular cancer has an early uptake of contrast in the arterial phase with an early washout in the portal and delayed phases [10]. One of the limitations of CT is the large dose of radiation given to the patient and the nephrotoxic effect of the iodine contrast that limit its use in patients with renal impairment.

Conclusion

It is evident from this study that ultrasonography has a wide applicability in the diagnosis of focal liver lesion. Ultrasound is fast, feasible, safe, cost effective and if combined with contrast, has an increased sensitivity in reaching the diagnosis but CT has a greater accuracy in diagnosis, is more widely applicable (less influenced by body morphology) and is helpful to study liver anatomy. High degree of sensitivity and specificity of USG diagnosis in the present study confirms the value of ultrasonographic evaluation of focal liver lesions and suggests that it can be effectively used in the routine diagnostic work.

References

1. Iannaccone R, Federle MP, Brancatelli G, *et al.* Peliosis hepatis: spectrum of imaging findings. *AJR Am J Roentgenol.* 2006; 187:W43-52. 10.2214/AJR.05.0167.
2. Brannigan M, Burns PN, Wilson SR. Blood flow patterns in focal liver lesions at microbubble-enhanced US. *Radiographics.* 2004; 24:921-935
3. Kim TK, Jang HJ, Burns PN, *et al.* Focal nodular hyperplasia and hepatic adenoma: differentiation with low-mechanical-index contrast-enhanced sonography. *Am J Roentgenol.* 2008; 190:58-66
4. Jang HJ, Kim TK, Wilson SR. Small nodules (1-2cm) in liver cirrhosis: characterization with contrast-enhanced ultrasound. ([Epub ahead of print]) *Eur J Radiol.* 2008;
5. Murphy-Lavallee J, Jang HJ, Kim TK *et al.* Are metastases really hypovascular in the arterial phase? (The perspective based on contrast-enhanced ultrasonography). *J Ultrasound Med.* 2007; 11:1545-1556
6. Kuligowska E, Noble J. Sonographic features of hepatic abscess. *Semin Ultrasound.* 1983; 4:102-116.
7. Gossin KB. Intrahepatic focal liver lesions -Differential diagnosis. *Am J Roentgenol.* 1981; 137:763-767.
8. Edmonston HA, Peters RL. Tumors of the liver -

Pathological features. *Seminars in Roentgenology.* 1983; 18(2):75-83.

9. Chi Y, Zhou J, Venkatesh SK, Tian Q, Liu J. Content-based image retrieval of multiphase CT images for focal liver lesion characterization. *Med Phys.* 2013; 40:103502
10. Tan CH, Low SC, Thng CH. APASL and AASLD Consensus Guidelines on Imaging Diagnosis of Hepatocellular Carcinoma: A Review. *Int J Hepatol* 2011; 2011:519783