



Evaluation of Ilizarov technique in the treatment of open fractures of Tibia

Md Humayun Reza¹, MAA Shameem², Md Delower Hossain³, Md Rajib Mahmud⁴, Md Mahmudul Hasan⁵, Abdul Matin⁶

¹ Assistant Professor, Orthopaedic Department, Shaheed M. Monsur Ali Medical College, Sirajganj, Bangladesh

² Assistant Professor, Department of Orthopaedics, Border guard Hospital, Pilkhana, Dhaka, Bangladesh

³ Medical Officer, Orthopaedic Department, 250 Bedded Bangamata Sheikh Fazilatunnessa Mujib General Hospital, Sirajgonj, Bangladesh

⁴ Jounior Consultant, Orthopaedic Department, 250 Bedded Bangamata Sheikh Fazilatunnessa Mujib General Hospital, Sirajgonj, Bangladesh

⁵ Registrar, 250 Bedded Bangamata Sheikh Fazilatunnessa Mujib General Hospital, Sirajgonj, Bangladesh

⁶ Registrar, Centre for the Rehabilitation of the Paralyzed, Mirpur, Dhaka, Bangladesh

Abstract

Introduction: Open fracture of tibia is a common occurrence in the orthopedic treatment arena. Open fractures of tibia are classified into Type I, II, IIIA, IIIB and IIIC. Ilizarov method is a popular method of treating open tibial fractures after debridement and open reduction. It is comparatively a newer method and has many advantages.

Aim of the study: The aim of this study was to evaluate the Ilizarov Technique in the treatment of open fractures of tibia.

Methods: This was an observational prospective study. The study was conducted in the Department of Orthopedics of Shaheed M. Monsur Ali Medical College, Sirajganj, Bangladesh during the period from January 2017 to December 2018. In total 40 patients with tibial fractures were selected as the study population. Before starting the intervention the written consent of the participants was taken and this study was approved by the ethical committee of the respective medical college.

Results: Out of total 40 participants, 29 (72.50%) were males and 11 (27.50%) were female. In analyzing mode of injuries we found highest 87.5% participants were from road accidents followed by 3% from sports injury and rest only 5% from general falls. The duration of treatment with the fixator was 12-23 weeks (average 16 weeks). Nineteen patients wore a PTB cast for an additional period of 4 weeks. In our study total 40 cases were debrided on the same day and stabilized with Ilizarov ring fixator after a period of 5 to 12 days from the date of injury. The operation time ranged from 90 minutes to 120 minutes (Mean 102±4 minutes).

Conclusion: No case developed deep infection, non-union or unacceptable mal-union. The Ilizarov device is used worldwide for the treatment of several types of fractures. The construct is stable and enables the patient to bear weight on the affected limb a short time after the surgery, even in cases of comminuted fractures. We recommend for more use of Ilizarov technic.

Keywords: Ilizarov, tibial, fractures, proximal, distal, fixator.

1. Introduction

Tibial fractures are the most common long bone fractures in the body [1]. Open fractures are common in this bone especially in the middle third of its length [2]. Treatment of open tibial fractures is very common but the treatment of open tibial fractures has controversy among the orthopedic surgeons [3]. Currently, non-surgical procedures like using casts, brace or interventional attempts like inserting of plate, intramedullary nailing and external fixators are used for treatment of open tibial fractures [4]. Selection of any of all the methods are related with surgeon's decision and economic status of the patients. In North America, most of surgeons do reamed nailing for the treatment of open or closed tibial fractures [4]. In developing countries because of low facilities and lack of medical instruments, the selection of each method may differ [5]. Recently, external fixators like Ilizarov or AO external fixator are used extensively in developing countries but the rates of mal-union and infection are relatively high [6] With AO external fixator, the efficacy of treatment in two studies were reported to be 20-

31% [7] Open fractures are classified into three major categories, depending on the mechanism of injury, soft tissue damage, and degree of skeletal involvement [8] Type I open fracture is characterized by a puncture wound around 1cm or less in diameter and is relatively clean in condition. Type II open fracture has laceration more than 1 cm long and less than 10 cm, without extensive soft tissue, flaps, or avulsion, with a minimal to moderate crushing component. The fracture is usually with minimal comminution. Besides these, type III open fracture is one that involves extensive damage to the soft tissue, including muscles, skin and neurovascular structures. The type III open fractures are further divided into three subtypes. Type IIIA indicates open fracture with adequate soft tissue coverage of a fractured bone despite extensive soft tissue laceration or flaps, or high-energy trauma (gunshot and farm injuries) regardless of the size of the wound [9]. Type IIIB indicates open fracture with extensive soft-tissue loss and periosteal stripping and bone damage. Usually associated with massive contamination [10] which will often need further soft-tissue

coverage procedure. On the other hand, Type IIC indicates open fracture associated with an arterial injury requiring repair, irrespective of degree of soft-tissue injury. Different methods for the treatment of open fracture shaft tibia (after debridement & open reduction) include POP cast immobilization, external fixation, open reduction and plating, locked intramedullary nailing. According to Trafton^[11], complications include deep infection, acute or chronic osteitis or osteomyelitis, delayed union, non-union, mal-union, loss of alignment in cast or brace, fixation problems. Gavril A Ilizarov, a Russian physician, devised this method of treatment of open fractures of tibia. The Ilizarov ring supports transfixional K-wire or haft pins, which can be fixed at the many holes site on the 360-degree ring. It has two or more connected rings that form a frame of the apparatus. The rings bear supplementary part of the frame necessary for dynamic bone treatment^[12] They are basically elastic type of external fixator and allow axial micro-motion that is conducive to healing of fractures and regenerate. Forces acting in the circular fixator are in a plane. It is a multilevel and multi-planner fixator. The circumferential rings of ilizarov distribute stresses more evenly across the fracture or osteotomy sites. Therefore, three dimensional corrections become possible. Axial distraction or compression angular and translational corrections are all possible using gradual mechanical techniques. On the other hand, circular fixator is a stable and elastic fixator. These types of fixators allow immediate weight bearing and function. As the wires are thin, the holes are small. Circular fixators can have capacity for three dimensional corrections. The Ilizarov devices are able to control shear at the fracture site while allowing axial and bending flexibilities producing an ideal environment for bone healing. Wire stoppers add shear rigidity to the system. Circular fixators are better for patients with osteoporosis using wire. The aim of this study was to evaluate the Ilizarov Technique in the treatment of open fractures of tibia.

2. Objectives

2.1 General objective

- To evaluate the Ilizarov Technique in the treatment of open fractures of tibia.

2.2 Specific Objectives

- To assess the fracture patterns of tibial fractures.
- To assess the types and locations of tibial fractures.

3. Methodology & Materials

This was an observational prospective study. The study was conducted in the Department of Orthopedics of Shaheed M. Monsur Ali Medical College, Sirajganj, Bangladesh during the period from January 2017 to December 2018. In total 40 patients with tibial fractures were selected as the study population. Before starting the intervention the written consent of the participants was taken and this study was approved by the ethical committee of the respective medical college. According to the exclusion criteria patients with closed fracture, pathological fractures and type IIC fractures were rejected from this study. The fractures were assessed by AP and Lateral X-ray. Fractures were classified according to Gustilo's fracture classification of open fractures. Patients with compound tibial fractures were taken to the operating room for debridement as soon as possible. These fractures were managed provisionally in

long leg posterior slab or long leg posterior cast with a window for dressing changes. Necessary fluids and electrolytes replacement or whole blood transfusion were given as per requirement of each patient. Definitive treatment of fracture was done as routine case usually in a week. Patients were operated under general or spinal anaesthesia as per need. Pre-assembly of the frame was done one day prior to surgery. Distance between the rings was adjusted according to the fracture anatomy. Fracture with minimal comminution and length loss less than 1cm was usually managed with a four ring frame, more complex fracture needed more number of rings. Wires were fixed to the rings with ring fixator bolt after tensioning up to 90-110 kg using a dynamometer. The rings were kept 2 finger breadths from skin all around. Reduction was checked with C-arm image intensifier on the table and adjustments done according at the same setting. The pin tract wounds were dressed by povidone iodine solution (10%) and covered with pad. Pin site was cleaned everyday with spirit or povidone iodine (10% solution). When clot and crust was present, weak solution of hydrogen peroxide (H₂O₂) was applied to remove it. When pin tract wound was inflamed or discharge was present, oral antibiotics were given. Partial weight bearing with axillary crutch was allowed as soon as the patient could tolerate the pain. The frame and wire was checked whenever the patients complained of pain, stability. Tension of the wire was checked and retensioning was done as per need. Check X-ray was taken on first or second postoperative day and reduction was checked. Equinus deformity was prevented by active and passive movement of ankle. If ankle movement was painful, foot was supported with a slipper or boot cast tied to the last ring. The patients were followed up at an interval of 2 weeks for a minimum period of 8 weeks, thereafter every month for 3 months and subsequently 3 monthly till a period of 1 year. Check-radiographs were taken on the next day and then at 6th week, 12th week and 36th week. The patients were assessed clinically for the range of movement of the knee and ankle respectively, pain at the fracture site, anterior knee pain, ankle joint symptoms, infection, muscular atrophy, clinical union, difficulty in walking and performing daily routine. Frames were removed after clinico-radiological union. The fracture was regarded to be united (1) if the patient could walk without support after loosening the frame crossing the fracture site and not tender at fracture site (2) if there was no mobility at fracture site after loosening the frame and (3) radiologically, if there was enough callus across the fracture site and obliteration of the fracture line. The frame was removed at the outpatients department or in the operation theatre once the fracture was united. If the frame was removed before the union of fracture due to superficial infection or frame intolerance patellar tendon bearing POP cast was applied. At the end of follow-up period, the results were grouped into excellent, good, fair, and poor using modified criteria of Karlstrom and Olerud.

4. Results

In our study among total 40 participants 72% were male and 28% were female. So male was dominating in this study. In age distribution we found 42.5% form 18-30 years' age group which was the highest number. This ratio was followed by 37.5% from 31-40 years' age group, 10% from 41-50 years' age group, 7.5% from 51-60 years' age group and rest 2.5% from >60 years' age group. According to the

data highest 47.5% participants was with type II open fracture followed by 37.5% with type I open fracture and rest 15% with type III A open fracture. On the other hand, among total 40 participants highest 67.5% patients had middle location fractures followed by 20% had proximal location and rest 12.5 had distal location fracture. In analyzing the patterns of open fractures we found highest 57.5 patients had comminuted fracture followed by 17.5% had transverse, 12.5% had oblique, 7.5% had spiral and rest 5% had segmental open fractures. Among total study population highest 57% patients had right side open fracture whereas 43% had left side open fractures. In analyzing mode of injuries we found highest 87.5% participants were from road accidents followed by 3% from sports injury and rest only 5% from general falls. The duration of treatment with the fixator was 12-23 weeks (average 16 weeks). Nineteen patients wore a PTB cast for an additional period of 4 weeks. In our study total 40 cases were debrided on the same day and stabilized with Ilizarov ring fixator after a period of 5 to 12 days from the date of injury. The operation time ranged from 90 minutes to 120 minutes (Mean 102±4 minutes). The Ilizarov external fixator was withdrawn when there was clinico-radiological union. The duration of treatment with the fixator ranged from 12 to 22 weeks (Mean 16±3 weeks). The time to union varied from 21 to 28 weeks (average 24.5 weeks). The average time of union was 21 weeks for Type I open fractures, 22.5 weeks for Type II open fractures and 27 weeks for Type IIIA open fractures. The complications of compound fracture of tibia with Ilizarov ring fixator were broadly divided into intra-operative, post-operative and delayed complications. There was no intraoperative complication. As for the postoperative complications, local pain with motion and local oedema were seen in 5 cases (12.5%) and painful tenting of skin in 8 cases (20%). Delayed complications included pin tract infection in 10 (25%) patients, loss of 80 ankle dorisflexion in 4 (10%) cases, shortening of 1 cm was seen in 2 case (5%), 2 cases (5%) of united in 70 recurvatum as calculated radiologically, 2 cases (5%) of muscle wasting of the leg from 0.4 to 1.5 cm. No case developed deep infection, non-union or unacceptable malunion. Only one patient got 2 weeks more treatment than all the others patients. According to Karlstrom and Olerud score among total 40 study people the functional results was found excellent in 75%, good in 17.5%, fair in 5% and poor in 2.5%.

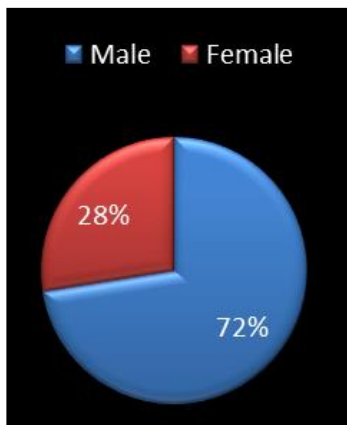


Fig 1: Gender distribution of participants (N=40)

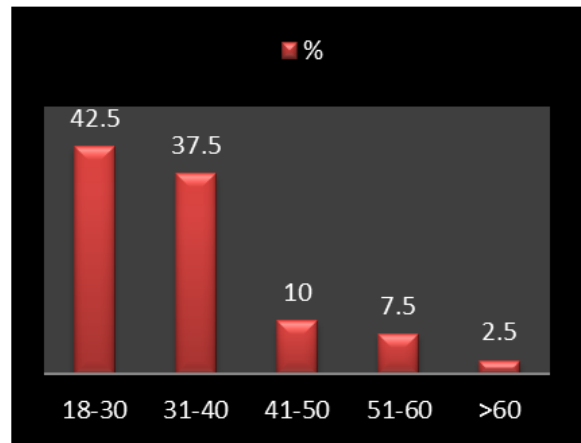


Fig 2: Age distribution of participants (N=40)

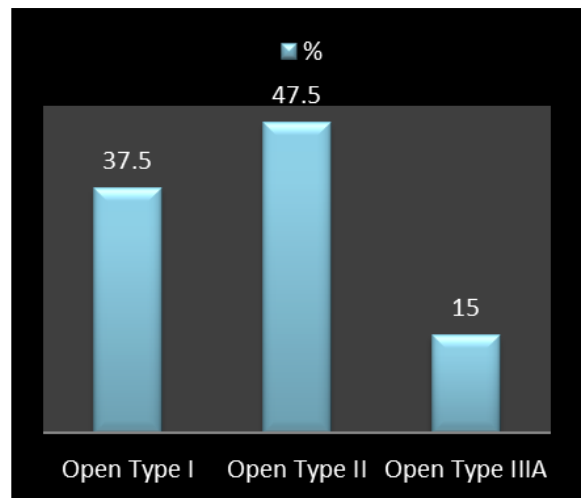


Fig 3: Distribution of types of open fractures (N=40)

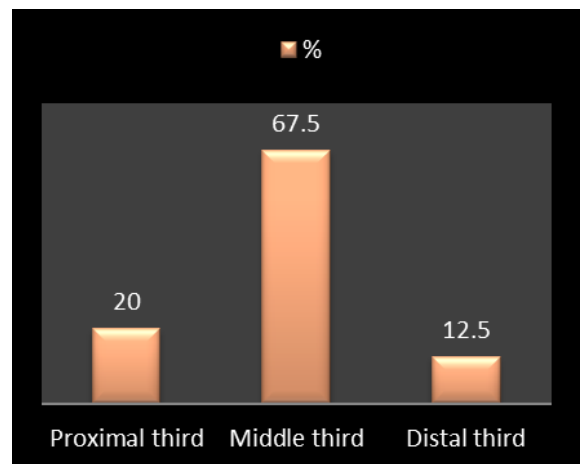


Fig 4: Distribution of locations of open fractures (N=40)

Table 1: Distribution of patterns of open fractures (N=40)

Patterns	n	%
Comminuted	23	57.5
Transverse	7	17.5
Oblique	5	12.5
Spiral	3	7.5
Segmental	2	5
Total	40	100

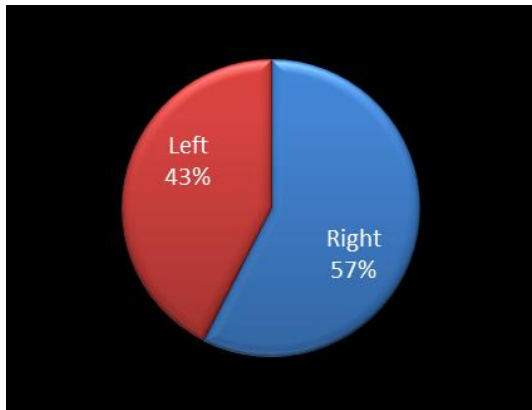


Fig 5: Distribution of sides of open fractures (N=40)

Table 2: Distribution of ‘mode of injuries’ of open fractures (N=40)

Mode of injury	n	%
Road traffic accident	35	87.5
Sports injury	3	7.5
Falls	2	5
Total	40	100

Table 3: Karlstrom and Olerud criteria level (N=40)

Satisfaction level	N	%
Excellent	30	75%
Good	7	18%
Fair	2	5%
Poor	1	3%

5. Discussion

There are many methods for stabilizing open tibial fractures. The problems are attributable mainly to the injury of skin, soft tissues and severity of the bone damage. In this study, the age of the patients ranged from 18 years to >65 years with mean age of 31±3 years. In our study, there were 72% males and 28% female. Shtarker H *et al.* [13] also reported male preponderance over female in their study. In our Study we found 67.5% had fractures in the middle third, 20% in the proximal third and 12.5% in the lower third. This finding is similar to that of Shtarker *et al.* [14], who reported 81.3% middle third, 15.7% proximal third and 3.1% lower third. In our study of 40 cases, there were 57.5% comminuted, 12.5% oblique, 7.5% spiral and 5% segmental. This finding is nearabout similar to the finding of Shtarker *et al.* [14] who found 20 cases (62.5%) in regard to comminuted fractures. In this study out of 40 participants, there were 11 (37.5%) open type I, 47.5% open type II and 15% open type III A which is comparable with that of Shtarker *et al.* [13]. The period between admission and Ilizarov ring fixation varied from 2 to 12 days with the average of 7 days in generally. It is generally agreed that ilizarov ring should be applied as soon as the general physical condition allowed. However, in this study Ilizarov ring fixation had to be delayed from 2 to 12 days from the date of injury because of insufficient operating days and facilities for emergency Ilizarov ring fixation. The average operating time varied from 90 minutes to 120 minutes. The finding was slightly lesser than that of Tucker [14] who reported that the operating time varied from 120 minutes to 210 minutes, though later it was reduced from 1 to 1.5 hours. The partial weight bearing on crutches was started on the very next day or on the 3rd day and full weight bearing after 2 to 3 weeks. This is comparable to that of Dagher and Ronkoz⁹ who reported that partial weight bearing was

begun within 1st week of operation and full weight bearing after 2 to 3 weeks. When using a uniplanar external fixator, postponed weight bearing until the fixator was removed. In our study, the patients were discharged from the hospital on an average on the 5th post-operative day. The average duration of hospital stay in this intervention was 12 days. Split thickness skin grafting was done in 6 cases in those who failed to heal spontaneously. In this study, the Ilizarov external fixator was removed after an average of 17 weeks (ranging from 12 to 22 weeks) which is in line with that of Shtarker *et al.* [13] removed on an average of 16 weeks (ranging from 11-21 weeks). In our series, the average time of clinic-radiological union was 24.5 weeks (ranging from 21 to 28 weeks). The average time of union was 21 weeks for type I open fractures, 25.5 weeks for type II open fractures and 25 weeks for type IIIA open fractures. Tucker [13] reported the range of time to union as 12 to 47 weeks, with an average of 24.5 weeks. Shtarker *et al.* [13] reported that the time to union was 21.5 weeks (ranging from 17.5 to 25.5 weeks). Keating [15] reported that the average time to union in reamed and unreamed locking intramedullary nailing in a series was 28 and 21 weeks for type I open fractures, respectively; 28 and 27 weeks for type II open fractures; 34 and 31 weeks for type IIIA open fractures. Weight bearing, to some degree, stimulates bone healing. Hulth [16] reported that the current concept of fracture healing was based on two variables namely blood supply and stability. In the present study, there were 11 cases (27.5%) of pin tract infection, manifested by pain, erythema and small purulent discharge around the pin sites which was controlled by oral antibiotic within 10 days. There was no case of deep infection in this study. Toker [14] reported approximately 10% of pin tract infection. Holbrook *et al.* [17] evaluated 28 open tibial fractures treated with external fixation and found a 14% rate of deep infection. Keating *et al.* [15] reported a rate of 3.3% in his series of open tibial fractures treated with locking intramedullary nailing. The aim of this study was to evaluate the Ilizarov Technique in the treatment of open fractures of tibia. We found some positive features of Ilizarov in treating open fractures through this study.

5.1 Limitations of the study

It was a single centered study with a small sized sample. So the findings of this study may not reflect the exact scenario of the whole country.

6. Conclusion and recommendations

To treat the cases of open fracture is a difficult task for the physicians. In our study we found some good features of using Ilizarov induced method in the treatment of open fractures. But to bring out more potential findings we would like to recommend for conducting more studies in several places in similar arena of the treatment procedure.

7. References

1. Cannada LK, Anglen JO, Archdea-con MT, Herscovici D Jr, Ostrum RF. Avoiding complications in the care of fractures of the tibia. *Instr Course Lect.* 2009; 58:27-36. [19385517]
2. Whittle AP, Wood II GW. Fractures of lower extremity. In: Canale ST. *Campbell’s operative orthopaedics.* 10th ed. Philadelphia, 2003, 2754-2773.
3. Webb LX, Bosse MJ, Castillo RC, MacKenzie EJ. LEAP Study Group. Analysis of surgeon-controlled variables in the treatment of limb threaten- ing type-

- III open tibial diaphyseal fractures. *J Bone Joint Surg.* 2007; 89:923-28. [17473126] [<http://dx.doi.org/10.2106/JBJS.F.00776>]
4. Petrisor BA, Bhandari M, Schmitsch E. Tibia and fibula fractures. In: Bucholz RW, Court-Brown CM, Heckman JD, Tornetta III P. *Rockwood and Green's fractures in adults.* 7th ed. Philadelphia; Lippincott Williams & Wilkins, 2010, 1867-1923.
 5. Wani N, Baba A, Kangoo K, Mir M. Role of early Ilizarov ring fixator in the definitive management of type II, IIIA and IIIB open tibial shaft fractures. *Int Orthop.* 2011; 35:915-23. [20445978] [<http://dx.doi.org/10.1007/s00264-010-1023-7>]
 6. Hasankhani E, Payvandi MT, Birjandinejad A. The Ilizarov ring external fixator in complex open fractures of the tibia. *Eur J Trauma.* 2006; 32:63-8. [<http://dx.doi.org/10.1007/s00068-005-0031-6>]
 7. Papaioannou N, Mastrokalos D, Papagelopoulos PJ, Tyllianaksi M, Athanassopoulos J, Nikiforidis PA. Nonunion after primary treatment of the tibia fractures with external fixator. *Eur J Orthop Surg Traumatol.* 2001; 11:231-35. [<http://dx.doi.org/10.1007/BF01686895>]
 8. Gustilo RB. Management of open fractures, in Gustilo RB (Ed.). *Orthopaedic Infection, diagnosis and treatment*, 1st edition (Philadelphia: WB Saunders Company, 1989, 87-89.
 9. Paul H Kim, Seth S Leopold. Gustilo-Anderson Classification. *Clinical Orthopaedics and Related Research.* 2012; 470(11):3270-3274. doi:10.1007/s11999-012-2376-6. PMC 3462875. PMID 22569719.
 10. Ovid: Externet Link. Ovidsp.tx.ovid.com. Retrieved 2017-11-10.
 11. Trafton PG. Tibial shaft fractures, in Browner BD, Jupiter JB, Levine AM, Krettek C (Eds.). *Skeletal trauma: basic science, management and reconstruction.* 1998; 4(2):2319-2451.
 12. Golyakhovsky V, Frankel VH. *Operative manual of Ilizarov techniques*, (New Delhi: Jaypee Brothers), 1986.
 13. Shtarker H, David R, Stolero J, Grimberg B, Soundry M. Treatment of open tibial fractures with primary suture and Ilizarov fixation, *Clinical Orthopaedics and Related Research.* 1997; 335:268-274.
 14. Tucker HL, Kendra JC, Kinnebrew TE. Management of unstable open and closed tibial fractures using Ilizarov method, *Clinical Orthopaedics and Related Research.* 1992; 280:125-135.
 15. Keating JF, Obrier PF, Blachut PA, Meck RN, Broekhuse HM. Locking intramedullary nailing with and without reaming for open fracture of the tibial shaft, *The Journal of Bone and Joint Surgery.* 1992-1987; 79A:334-341.
 16. Hulth A. Basic science and pathology, current concept of fracture healing: *Clinical Orthopaedics and Related Research.* 1989; 249:265-285.
 17. Holbrook JL, Swiontkowski MF, Sanders Roy. Treatment of open fractures of tibial shaft: Enders nailing versus external fixation A randomized prospective comparison, *The Journal of Bone and Joint Surgery.* 1989; 71A:1231-1238.