

Study of the shape of foramen magnum done on dry bone specimen

Dr. Harsh Vardhan¹, Dr. SK Chauhan²

¹ Department of Anatomy MGM Medical College, Jamshedpur, Jharkhand, India

² Associate Professor, Department of Anatomy MGM Medical College Jamshedpur, Jharkhand, India

Abstract

Introduction: Foramen magnum is an important landmark at the junction of skull and spine. As it transmits structures like the lower end of the medulla oblongata, meninges, vertebral arteries and the spinal accessory nerve.

Aims and objectives: Our aim was to measure anteroposterior and transverse diameters of foramen magnum and to observe its different shapes.

Materials and methods: Thirty Four (34) adult human skulls of unknown sex were obtained from Department of Anatomy, MGM Medical College Jamshedpur. Diameters of Foramen magnum were calculated using sliding vernier calipers and shapes were assessed.

Observations and results: Maximum anteroposterior diameter of foramen magnum was found to be 42.5mm and minimum was 27.5mm with the mean of 33.04mm whereas Maximum transverse diameter was 34mm and minimum was 23mm with the mean of 26.74mm. Percentage of foramen magnum shapes were as follows: oval 60%, Tetragonal 19%, hexagonal 12%, circular 9% and irregular 2% cases.

Conclusion: Knowledge of dimensions of foramen magnum is important for radiologist, orthopaedicians and neurosurgeons, while planning and performing cranio-vertebral junction surgeries.

Keywords: foramen magnum, skull, morphometry, shape, variation

1. Introduction

Foramen magnum is the opening in the occipital bone and it transmits lower end of the medulla oblongata, meninges, vertebral arteries and the spinal accessory nerve¹. The foramen magnum is formed by the fusion of the four parts of the occipital bone pars squama, left and right pars lateralis, and pars basilaris². The position of the foramen magnum in humans as compared to other mammals has migrated forward in the occipital bone from the back of the skull beneath the center of the skull and brain⁴. It is of particular interest for anthropology, anatomy, forensic medicine and other medical fields. The knowledge of foramen magnum diameters is important as it is needed to determine malformations such as Arnold Chiari syndrome, which shows expansion of transverse diameter⁵. The diameters and area of the foramen magnum are greater in males than in females, hence its dimensions can be used to determine sex in the medicolegal conditions, such as explosions, aircraft accidents and war fare injuries⁵.

Aims and Objectives

Our aim was to provide data of anteroposterior and transverse diameters of foramen magnum and to observe its different shapes.

2. Materials and Methods

Twenty Four (24) adult human skulls of unknown age and sex were obtained from Department of Anatomy,. Deformed samples were excluded. The samples were visually assessed for shape of foramen magnum and were photographed. Foramen magnum was classified into five shapes – oval, round, irregular, tetragonal and hexagonal. Two bony landmarks were determined. Basion i.e. the median point of the

anterior margin of foramen magnum & Opisthion i.e. median point of posterior margin of foramen magnum. Anteroposterior diameter (APD) was calculated as distance between these two points. Transverse diameter (TD) was measured as a length of line drawn perpendicular to the previous line at the site of maximum curvature of the lateral margins. Measurements were taken using the Vernier caliper and measured to the nearest millimeter. The mean, Median, Mode & Standard Deviation (SD) for the anteroposterior diameter (APD) and transverse diameter (TD) of foramen magnum were calculated and tabulated. Foramen magnum index (FMI) was calculated using the formula: $FMI = APD / TD$.

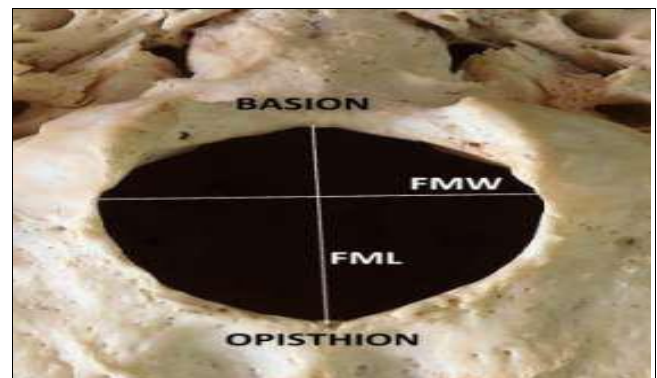


Fig 1: Showing Measurements of Foramen Magnum

3. Observations and results

The various parameters of foramen magnum recorded in dry skulls are represented in Table no.1. Range of APD - 27.4mm to 42.5mm. Range of TD-23mm to 34mm.

Mean of AP Diameter-33.04mm. Mean of TD- 26.74mm. Range of FMI-1.02 to 1.54. The percentage of

different shapes of Foramen magnum is tabulated in Table.

Table 1

| Shape of foramen magnum | Percentage |
|-------------------------|------------|
| Oval | 14 (60%) |
| Tetragonal | 5(19%) |
| Hexagonal | 3 (12%) |
| Circular | 2(9%) |
| Irregular | 1 (2%) |

Discussion

The shape of foramen magnum is considered oval, when FMI ≥ 1.2. In the present study, the oval shape was most commonly found, as in many other studies. Some authors found round shape as most common.. Anteroposterior and transverse diameter of foramen magnum in the present study

is compared with those of various authors. Abnormal foramen magnum diameter is associated with various clinical problems. Cerebellar tonsillar herniation is associated with larger anteroposterior diameter. Arnold-Chiari malformation is a condition where transverse diameter is increased.

Table 2

| Shape of foramen magnum | Radha Krishnan <i>et al</i> | Radhika PM | Present study |
|-------------------------|-----------------------------|------------|---------------|
| Oval | 39% | 40% | 60% |
| Tetragonal | 28% | 20% | 19% |
| Hexagonal | 19% | 6% | 12% |
| Circular | ---- | 6% | 9% |
| Irregular | ----- | 16% | 2% |

Comparison of morphological types of foramen magnum and frequency of occurrence with previous studies.

Table 3

| Study with year | AP Diameter | Transverse Diameter |
|------------------------------------|-------------|---------------------|
| Radha Krishnan <i>et al</i> (2006) | 33.3 | 27.9 |
| Radhika PM(2014) | 35.3 | 29.4 |
| Present study(2019) | 33.04 | 26.74 |

Comparison of Antero-posterior Diameter & Transverse Diameter of various studies.

Conclusion

The present study gives the variations in morphology and morphometry of foramen magnum & may be used as a database. Knowledge of its dimensions and variations in its shape are important for radiologist, orthopaedicians and neurosurgeons, while planning and performing cranio-vertebral junction (CVJ) surgeries, to avoid damage to important structures passing through it & to prevent atlanto-occipital instability and hemorrhage.

References

- Graw Hill Concise Dictionary of Modern Medicine: Mc Graw Hill Companies Inc, 2002.
- Avci E, Kara E, Ozturk NC, Uluc K. Anatomical variation of the foramen magnum, occipital condyle and jugular tubercle. Turkish Neurosurgery. 2011; 2(2):181-90.
- Luboga SA, Wood BA. Position and orientation of foramen magnum in higher primates. American Journal of Physical Anthropology. 1990; 81:67-76.
- Kimbel WH, Rak Y. The cranial base of Australopithecus afarensis: new insights from the female skull. Phil. Trans. R. Soc. B. 2010; 365:3365-76.
- Sgouros S, Goldin HJ, Hockely AD, Wake MJ, *et al*. Intracranial volume change in childhood. JNeurosurg. 1999; 91:610-616.
- Murshed KA, Cicekeibasi AE, Tuncer I. Morphometric evaluation of the foramen magnum and variations in its

- shape. A study of computerized tomographic images of normal adults. Tur J Med Sci. 2003; 33:301-306.
- Gunay Y, Altinkok M. The value of the size of foramen magnum in sex determination. J Clin forensic Med. 2000; 7(3):147-149
- Radhika PM, Shailaja Shetty, Pratap KJ, Sheshgiri C, Jyoti KC. Asian J Med Clin Sci, Ma. 2014; 3(2):68-72.
- Standring S, Gray's Anatomy: The Anatomical Basis of Clinical Practice Fortieth Edition, Elsevier Churchill Livingstone, 2008; 415, 433, 770.
- Muthukumar N, Swaminathan R, Venkatesh G, Bhanumathy SP: A morphometric analysis of the foramen magnum region as it relates to the transcondylar approach. Acta Neurochir (Wien). 2005; 147:889-895.