

Role of high resolution ultrasonography in the diagnosis of early scaphoid fracture in comparison of x-rays

Kirtigiri G Goswami¹, Amritanshu Agarwal², Sunil Kumar Agrawal³, Arun Prasad², Ankush Malik²

¹ Professor, M.D, MBBS, Department of Radiodiagnosis, Muzaffarnagar Medical College, Muzaffarnagar, Uttar Pradesh, India

² MBBS, PG-J.R, Department of Radiodiagnosis, Muzaffarnagar Medical College, Muzaffarnagar, Uttar Pradesh, India

³ Professor and Hod, MBBS, Department of Radiodiagnosis, Muzaffarnagar Medical College, Muzaffarnagar, Uttar Pradesh, India

Abstract

Aims and Objectives: The aim of this study was to establish the role of high resolution ultrasonography in the diagnosis of early scaphoid fracture in comparison of x-rays.

Materials and Method: High Resolution Ultrasonography of Wrist joint was performed on 44 cases and E- CUBE ALPINION L3-12 MHz Probe USG Machine was used and the result was analysed.

Results: A total of 44 participants with mean age of 31.73 years were studied. Out of 44 participants, five showed fracture, seven showed hematoma alone and eight patients showed hemarthrosis alone.

Discussion: All 44 participants were clinically presumed scaphoid fractures but was not affirmed over starting roentgenograms, due to this prompting either by deferred analysis and management. However on HRUSG out of 44 participants only five were diagnosed with scaphoid fracture. So it prevented overtreatment of patients without fractures.

Conclusion: There are few studies done in Indian population to diagnose early scaphoid fracture by using high resolution ultrasonography in comparison of X-rays. So this study can be used to make an early and accurate diagnosis and management of clinically suspected scaphoid fractures.

Keywords: resolution ultrasonography, scaphoid fracture, comparison of x-rays

Introduction

The Scaphoid, is boat shaped carpal bone. It is the biggest of the proximal column of carpal bones. It is available on the spiral part of lunate and verbalizes with range proximally, trapezium and trapezoid distally, with capitate and lunate medially. Blood vessel gracefully of the scaphoid is abnormal, as corridors entering from distal end and afterward passing proximally to supply rest of the scaphoid. More often fracture happens through the waist of the scaphoid, and it is the commonest site (80% of cases), the blood flexibly to the proximal post is intruded. Because of this there is a critical danger of proximal shaft osteonecrosis or non-association of the fracture [1]. Among all the carpal bone fractures, Scaphoid fracture are the most well-known and speak to 60% of all [2]. Relative occurrence of carpal bone fracture, for scaphoid is 68.2% [2].

Conclusion of scaphoid fracture is trying due to vague clinical introduction [3] and comparable or negative imaging discoveries. In fact, on introductory traditional roentgenograms there is high odds of negative discoveries, going from 20% to 25% [4]. As a result of this deferral, and relying upon the clinical doubt, affected wrist joint can be immobilized [5]. The significant constraint of this methodology is that even without fracture, wrists of numerous patients might be immobilized, because of which helpless outcomes as far as medical care expenses and personal satisfaction [6]. Most ordinarily scaphoid fracture present in youthful grown-ups [7] and they have high paces of complexities (for example AVN, nonunion, postponed association, osteoarthritis), normally these entanglements happened because of deferred analysis. In fact, odds of negative discoveries on early plain roentgenograms hushes

up high. [8] Other imaging methodology like MRI and CT have just high affectability and explicitness, but have certain impediments in regard of their accessibility and imaging cost. In our awareness and information, there are very little investigations in which they have analyzed the function of high resolution sonography in instances of wrist injury and very little have explicitly centered around occult fractures and examination of the scaphoid bone. High resolution ultrasonography is effectively open, modest, harmless, simple to perform and calm exact. Radiation exposure is absent. As it is a financially savvy technique, it very well may be handily managed by the low financial individuals also to analyze early scaphoid fractures. So reason for my examination is to evaluate the part of HRUSG in the early identification of clinically speculated scaphoid fracture and its symptomatic precision with ordinary discoveries on introductory roentgenogram.

Materials and Methods

- Ultrasonography of Wrist joint was performed on 44 cases referred from Department of Orthopaedics. E-CUBE ALPINION L3-12 MHz Probe USG Machine was used.
- The patients who were presented with chief complaints of swelling or felt difficulty in movements at wrist joint, pain or tenderness in anatomical snuffbox were included and digital roentgenograms of traumatic wrist joint were taken and which were concluded normal. Patients were then guided to HRUSG for the traumatic wrist.
- To avoid intra observer variability all HRUSGs were interpreted by same radiologist. Non-traumatic wrist

was taken as control.

- HRUSG was used along with extended field of view (EFOV) and colour Doppler was used whenever required. A linear array transducer of frequency 3 to 12 MHz was used in the study.
- Patients were made to sit on examination table confronting the radiologist and mentioned to uncover reciprocal wrist joints up to the mid forearm at the same time. Sonography were performed of both traumatic and non-traumatic wrist joints within first week of trauma.
- Scaphoid bone was examined in multiple planes i.e. from dorsal aspect and lateral aspect, both longitudinal and transverse planes, and in both normal and ulnar deviation positions so that we can see the scaphoid in elongated view. (Fig. 1). We saw sincerely the anterior hyperechoic margin of the scaphoid which is actually the cortex and the soft tissues surrounding the traumatic area.

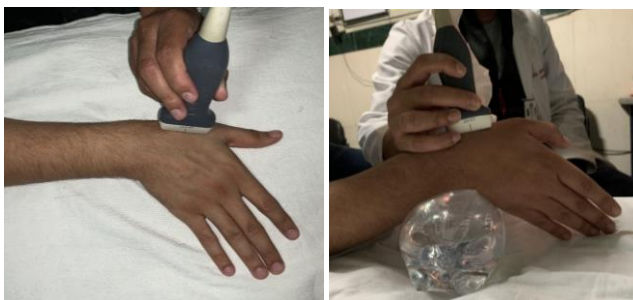

Fig 1: Position for sonography of scaphoid bone in photograph (A) frontal view with ulnar deviation and in (B) it shows lateral view to elongate scaphoid. It allowed us for proper visualization of cortex.

- Discontinuity in the cortex was considered as Scaphoid fracture.
- Soft-tissue abnormalities: Two types were reported: Hematoma and Hemarthrosis, were track down at the level of the scaphoid (Fig. 2 and 3).

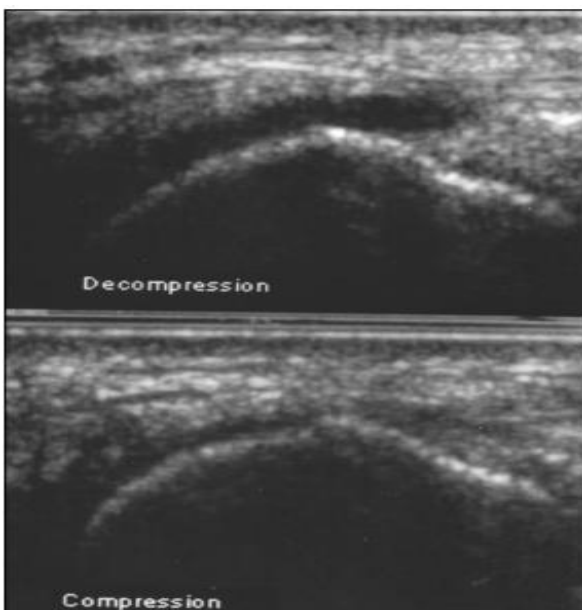

Fig 2: Young female with acute trauma of wrist and showed suspicion of scaphoid breach with wrist in ulnar deviation. A compressible and diffuse collection noted at the level of scaphoid. i. e. Hemarthrosis.

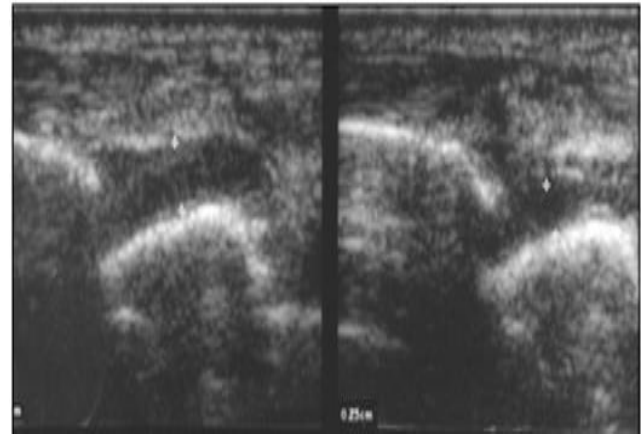


Fig 3: A male patient presented with acute wrist trauma. On Longitudinal HRUSG-- There was no or less compressible collection i.e. hematoma at same level as in image (2). Pointer showed upper and lower limits of hematoma i.e. its width with and without compression.

- Sonographic examinations were interpreted immediately.
- Longitudinal, transverse, and EFOV images were obtained and scaphoid cortical continuity was assessed along with radiocarpal effusion assessment.

Observation and Results

Data is summarized in Tables.

Total 44 patients were included in the study and they all showed initial normal roentgenogram, out of these patients, six (13%) patients presented with cortical breach of the scaphoid on HRUSG (these all six patients showed hematoma or hemarthrosis or both), seven (16%) presented with hematoma alone, eight (18%) presented with hemarthrosis alone, and 23 patients (52%) did not present with any kind of deformity.

Out of six patients which presented cortical breach, five patients (83%) had affirmed scaphoid fracture over MRI, and one patient (17%) had ordinary discoveries on both roentgenogram and MRI. In this false positive case, MRI indicated a degenerative wrist with cortical abnormality of the scaphoid tubercle. No false negative outcome was observed. Among the seven patients with proof of hematoma alone, none had demonstrated scaphoid breach. In these patients, MR imaging were acted in withstanding roentgenogram in light of the determination of a clinical doubt of breach. Rehashed sonographic assessments acted in three of these patients demonstrated goal of the hematoma. Altogether, none of the 15 patients with delicate tissue anomalies alone (i.e., without breach of cortex) had an affirmed scaphoid fracture on development. Among the 23 patients without cortical disturbance and delicate tissue irregularity on starting assessment, subsequent radiographic discoveries were viewed as typical in all patients. Utilizing cortical disturbance for the standard of fracture, we found the specificity, sensitivity and PPV and NPV of HRUSG for early recognition of mysterious scaphoid fractures to be 98%, 100%, 83%, and 100%, individually. In the event that delicate tissue irregularities separately (i.e., hematoma or hemarthrosis) were utilized as the measure of fracture, the specificity, sensitivity, PPV and NPV of HRUSG for early identification of mysterious fractures were 65%, 100%, 23%, and 100%, individually. General commonness for mysterious fracture was 11.4% (5/44).

Table 1: Age Distribution of Cases

Age in Years	
Mean	31.73
SD	16.62
Min.	8
Max.	73

Total 44 cases were included in the study. The mean age of study cases was 31.73±16.62 years with minimum age 8 years while maximum 73 years. So the cases included contained a broad range of ages.

Table 2: Sex Distribution of Cases

SEX	No.	%
Male	31	70.5
Female	13	29.5
Total	44	100.0

Out of 44 cases, majority 31 (70.5%) cases were males while rest 13 (29.5%) cases were females. So the male – female ratio of the study was 31: 13.

Table 3: Distribution of Cases according to Tenderness at Anatomical Snuffbox

Tenderness at Anatomical Snuffbox	No.	%
P	44	100.0

Out of 44 cases, tenderness at anatomical snuffbox was present in all the 100% cases.

Table 4: Distribution of Cases according to x-ray finding of wrist joint.

X-Ray Finding of Wrist	No.	%
No Fracture Seen	44	100.0

Out of 44 cases, no fracture was seen in any case by X- ray of wrist joint.

Table 5: Distribution of Cases according to cortical disruption on HRUSG.

Cortical Disruption	No.	%
Not present	39	88.6
Present	5	11.4
Total	44	100.0

Out of 44 cases, cortical disruption was present in 5 (11.4%) cases while in remaining 39 (88.6%).

Cases no cortical disruption was found or visible as per HRUSG report. So the prevalence of cortical disruption is expected to be 11.4%

Among the patients presented with complaints of pain, swelling or restricted movements of wrist joint or tenderness in anatomical snuffbox.

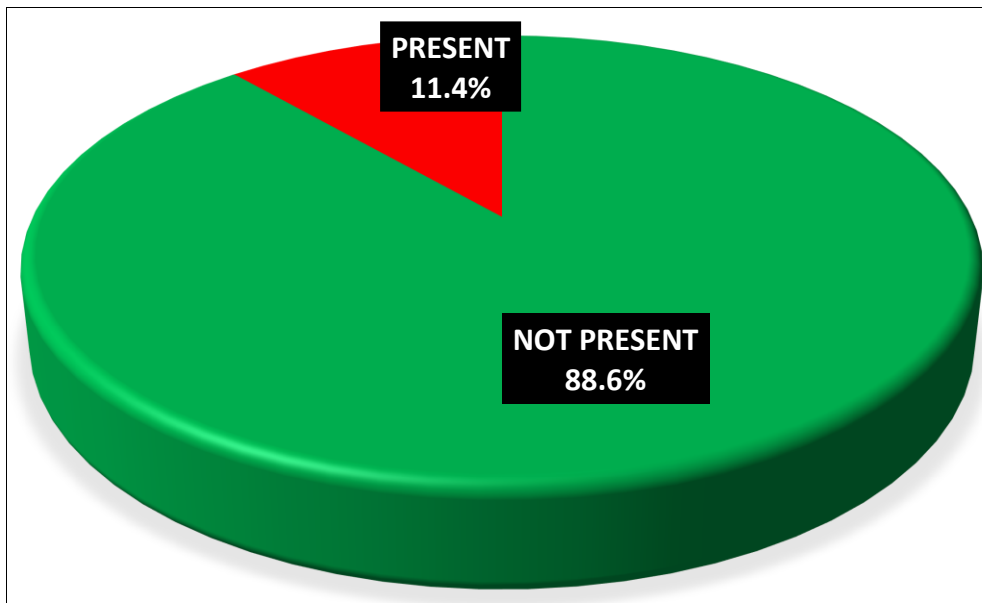


Fig 4

Table 6: Distribution of Cases according to HEMARTHROSIS

Hemarthrosis	No.	%
Not present	32	72.7
Present	12	27.3
Total	44	100.0

Out of 44 cases, Hemarthrosis was present in 12 (27.3%) cases while in remaining 32 (72.7%) cases no Hemarthrosis was found or visible as per HRUSG report. So the prevalence of Hemarthrosis is expected to be 27.3% among the patients presented with complaints of pain.

Swelling or restricted.

Movements of wrist joint or tenderness in anatomical snuffbox

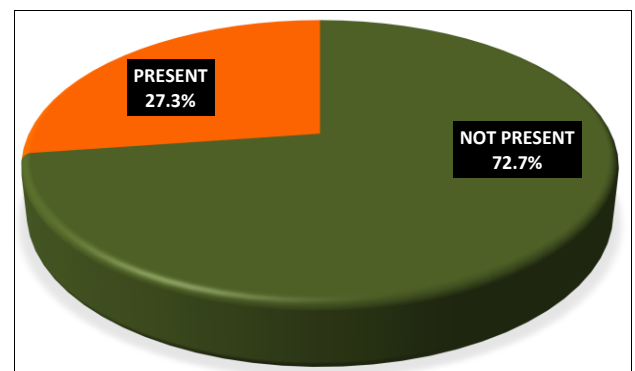


Fig 5

Table 7: Distribution of Cases according to Hematoma

Hematoma	No.	%
Not present	31	70.5
Present	13	29.5
Total	44	100.0

Out of 44 cases, Hematoma was present in 13 (29.5%) cases while in remaining 31 (70.5%) cases no Hematoma was found or visible as per HRUSG report. So the prevalence of Hematoma is expected to be 29.5% among the patients presented with complaints of pain, swelling or restricted movements of wrist joint or tenderness in anatomical snuffbox.

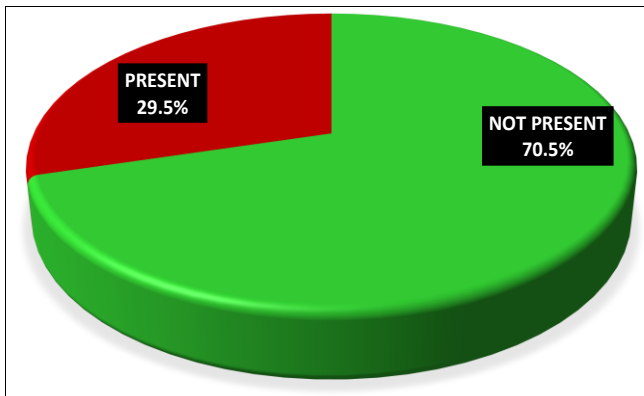


Fig 6

Table 8: Agreement between Cortical Disruption and Hemarthrosis in HRUSG Findings

Hrusg findings		Cortical disruption				Kappa value	P-value
		Not present		Present			
Hemarthrosis	Not present	32	72.7%	0	0.0%	0.510	<0.001
	Present	7	15.9%	5	11.4%		

As per HRUSG findings, there were 5 (11.4%) cases in which Cortical Disruption and Hemarthrosis both were present while in 32 (72.7%) cases both were absent. Further in 7 (15.9%) cases Hemarthrosis was present but Cortical disruption was absent, on the other hand no case was found in which Hemarthrosis was absent but Cortical disruption was present. A strong agreement (k=0.510, p<0.001) was seen between Cortical Disruption and Hemarthrosis findings.

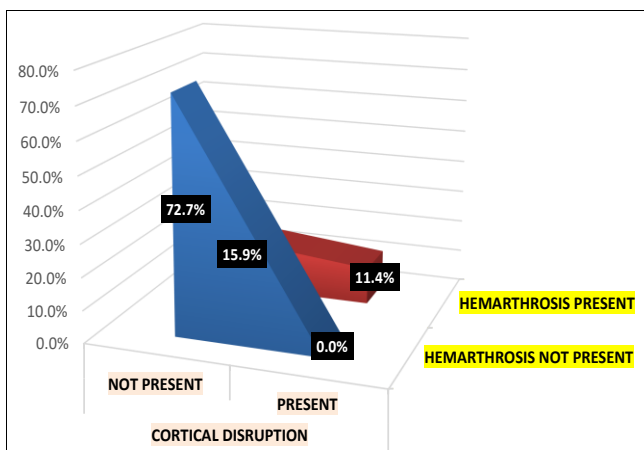


Fig 7

Table 9: Agreement between Cortical Disruption and Hematoma in Hrusg Findings

Hrusg findings		Cortical disruption				Kappa value	P-value
		Not present		Present			
Hematoma	Not present	31	70.5%	0	0.0%	0.468	<0.001
	Present	8	18.2%	5	11.4%		

As per HRUSG findings, there were 5 (11.4%) cases in which Cortical Disruption and Hematoma both were present while in 31 (70.5%) cases both were absent. Further in 8 (18.2%) cases Hematoma was present but Cortical disruption was absent, on the other hand no case was found in which Hematoma was absent but Cortical disruption was present. A strong agreement (k=0.468, p<0.001) was seen between Cortical Disruption and Hematoma findings.

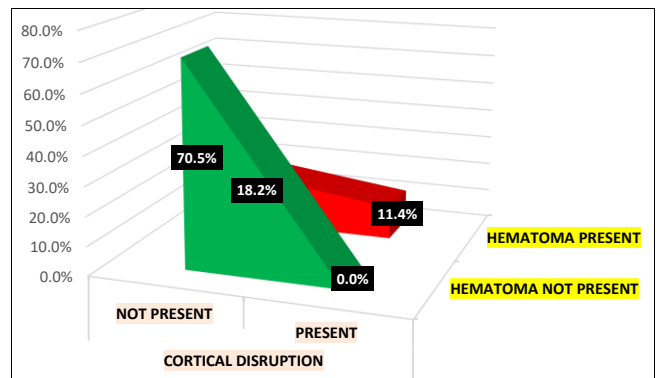


Fig 8

Table 10: Agreement between Hemarthrosis and Hematoma in HRUSG Findings

Hrusg findings		Hemarthrosis				Kappa value	P-value
		Not present		Present			
Hematoma	Not present	29	65.9%	2	4.5%	0.721	<0.001
	Present	3	6.8%	10	22.7%		

As per HRUSG findings, there were 10 (22.7%) cases in which Hemarthrosis and Hematoma both were present while in 29 (65.9%) cases both were absent. Further in 3 (6.8%) cases Hematoma was present but Hemarthrosis was absent, on the other hand in 2 (4.5%) cases Hematoma was absent but Hemarthrosis was present. A strong agreement (k=0.721, p<0.001) was seen between Hemarthrosis and Hematoma findings.

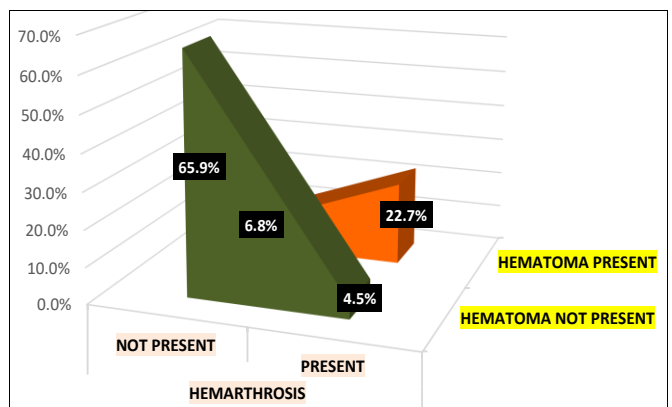


Fig 9

Table 11: Comparison of Data Obtained By Hrusg in Suspected Scaphoid Fracture with Normal Initial Radiographs

Examinations	HRUSG				Total
	Cortical Disruption	Soft Tissue Abnormalities Alone		No Abnormalities	
		Hematoma	Hemarthrosis		
Fracture	5(83%)	0(0%)	0(0%)	0(0%)	5
No Fracture	1(17%)	7(16%)	8(18%)	23(52%)	39
Total	6	7	8	23	44

Table 12: Sensitivity, Specificity and Ppv & Npv in the Diagnosis of Occult Fracture of Scaphoid

Characteristics	Cortical Disruption	Soft- Tissue Abnormalities
Sensitivity	100%(5/5)	100%(5/5)
Specificity	97%(38/39)	59%(23/39)
Positive PV	83%(5/6)	24%(5/21)
Negative PV	100%(38/38)	100%(23/23)

(Note: PV = Predictive Value)

clarified by three primary reasons: first, specialized upgrades in HRUSG prompting higher spatial resolution, particularly by 12-MHz transducer utilized in examination permitting portrayal of inconspicuous posttraumatic changes; second, the utilization of rigid models (i.e., disturbance of cortex) to affirm the analysis of fracture. Most past examinations utilized less severe standards, for example, delicate tissue changes, which may likewise happen after a wrist sprain. Third, the five mysterious fractures portrayed in this investigation included the midsection of the scaphoid, which is the most widely recognized site of fracture yet additionally the most straightforward territory to examine on HRUSG.

CT and MRI provides affectability and explicitness more noteworthy than 95% and a pace of identification going from 18% to 27% [10-11, 12-13], figures equivalent to the outcomes acquired in our concentrate with HRUSG. In our examination, the 9.3% pervasiveness of OSF recognized on HRUSG is comparable to the pace of recognition in some bone sweep contemplates [5, 14] yet lower than that on MRI. Finding of OSF is of central significance as a result of its remedial suggestions. On account of a high pace of difficulties (i.e., postponed association, nonunion, AVN, and auxiliary osteoarthritis), management of patients with uprooted fractures, as a rule with medical procedure, is very much systematized, [15]. In actuality, management of patients with an undisplaced fracture, which is by definition a OSF, may change. It typically comprises of cast immobilization of the wrist for a four to eight-weeks time frame. In any case, an elective careful management by percutaneous obsession can be proposed [16, 17]. The bit of leeway of the last technique is a huge decrease in the immobilization time with a speedy getting back to ordinary exercises (four days for inactive laborers and five weeks for manual specialists). Another advantage of the early conclusion of a OSF is that overt management of patients without huge sores is stayed away from. Contrasted with other analytic apparatuses, HRUSG ought to turn into a demonstrative strategy of decision in instances of clinical scaphoid. It is a dependable, nonionizing, accessible, and financially savvy procedure. In addition, it isn't tedious on the grounds that the interim of the techniques went from 10 to 15 min in our investigation. In any case, sonography has deficiencies. To begin with, on the grounds that almost all OSF in our investigation happened at the waist, as far as anyone is concerned, that's obscure whether HRUSG will be proficient for the discovery of fractures of the distal and particularly proximal end of the scaphoid.

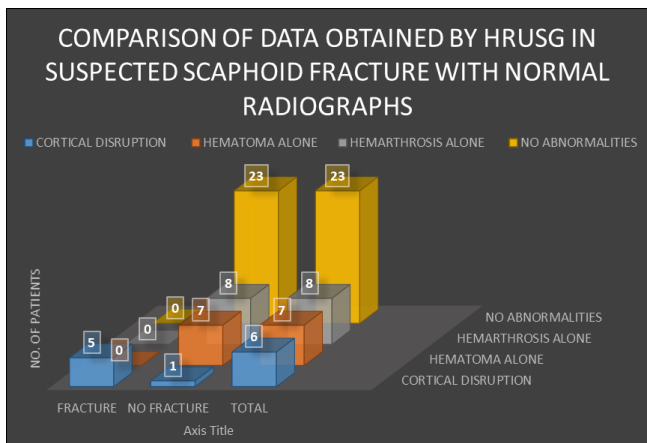


Fig 10

Discussion

Scaphoid bone breach speak to 2% of all breach however seventy five percentage of carpal breeches. Clinical indications in scaphoid breach are delicate yet have a low explicitness (22%) [4]. Prompt management of patients with clinical doubt of scaphoid breach without strange discoveries on beginning roentgenogram is testing. Altogether, 20% to 25% of clinically presumed scaphoid breeches [5, 8] are not affirmed over starting roentgenograms, prompting either by deferred analysis and management, with an expanded pace of entanglements, or to overtreatment of patients without fractures. In the two cases, results regarding personal satisfaction along with cost-viability are critical [6] Outcomes showed that HRUSG can portray OSF in a beginning phase. At the point when we thought about cortical breach as the demonstrative key, each of the five mysterious fractures gathering were portrayed on HRUSG without false negative outcomes. False positive results watched and compared to an unpredictable tubercle in a old man with checked thumb's degenerative changes and a background marked by wrist injury. On roentgenogram the tubercle zone seems, by all accounts, to be a basic zone and has to be dissect on HRUSG [9]. In the entirety of our subjects, cortical breach was related either with hemarthrosis or hematoma. Sonography has just been proposed as an option indicative apparatus in patients with scaphoid fractures, yet none of the past investigations were explicitly centered around occult fractures. Our outcomes seem unrivaled with specificity, sensitivity, and exactness of 98%, 100%, and 98%, individually, which might be

Conclusion

High-resolution sonography seems, by all accounts, to be a calm dependable, precise, promptly accessible, and savvy strategy for assessing occult fracture of the scaphoid. Conclusion was in view of cortical disturbance related with delicate tissue anomalies, which alone were not a explicit indication of fracture. Early assessment of the scaphoid

bone after wrist injury is critical to start brief management in instances of OSF, on the grounds that early treatment considerably diminishes the pace of difficulty and evades the overtreatment of patients without fracture.

References

1. Grainger and Allison's Diagnostic Radiology sixth edition volume two 2017; 52:1218-20.
2. Trybus M, Lorkowski J, Brongel L, Hladki W. Causes and consequences of hand injuries. *Am J Surg.* 2006; 192:52-7.
3. Senall JA, Failla JM, Bouffard JA, Van Holsbeeck M. Ultrasound for the early diagnosis of clinically suspected scaphoid fracture. *J Hand Surg Am.* 2004; 29:400-05.
4. Fusetti C, Poletti PA, Pradel PH, Garavaglia G, Platon A, Della Santa DR, *et al.* Diagnosis of occult scaphoid fracture with high-spatial-resolution sonography: a prospective blind study. *J Trauma.* 2005; 59:677-81.
5. Waizenegger M, Wastie ML, Barton NJ, Davis TR. Scintigraphy in the evaluation of the clinical scaphoid fractures. *J Hand Surg Br.* 1994; 19:750-753.
6. Munk B, Frokjaer J, Larsen CF, *et al.* Diagnosis of scaphoid fractures: a prospective multicenter study of 1,052 patients with 160 fractures. *Acta Orthop Scand.* 1995; 66:359-360.
7. Larsen CF, Brondum V, Skov O. Epidemiology of scaphoid fractures in Odense, Denmark. *Acta Orthop Scand.* 1992; 63:216-18.
8. Waizenegger M, Wastie ML, Barton NJ, Davis TR. Scintigraphy in the evaluation of the clinical scaphoid fractures. *J Hand Surg Br.* 1994; 66:359-60.
9. Tiel-van Buul MM, Broekhuizen TH, Van Beek EJ, Bossuyt PM. Choosing a strategy for the diagnostic management of suspected scaphoid fracture: a costeffectiveness analysis. *J Nucl Med.* 1995; 36:45-48.
10. Angermann P, Lohmann M. Injuries to the hand and wrist, a study of 50, 272 injuries. *J Hand Surg Br.* 1993; 18:642-44.
11. Esberger DA. What value the scaphoid compression test? *J Hand Surg Br.* 1994; 19:748-49.
12. Herneth AM, Siegmeth A, Bader TR, *et al.* Scaphoid fractures: evaluation with high-spatial resolution U Seinitial results. *Radiology.* 2001; 220:231-5.
13. Fusetti C, Poletti PA, Pradel PH, *et al.* Diagnosis of occult scaphoid fracture with high-spatial resolution sonography: a prospective blind study. *J Trauma.* 2005; 59:677-81.
14. Paul J, Jenkins Kate Slade James S Huntley C Michael Robinson. *J Hand Surg Eur.* 2008; 33(6):791-6.
15. Alexander Blankstein. Ultrasound in the diagnosis of clinical orthopedics: The orthopedic stethoscope. *World J Orthop.* 2011; 2(2):13-24.
16. Robert M Kwee, Thomas C Kwee. Ultrasound for diagnosing radio graphically occult scaphoid fracture. *Epub.* 2018; 47(9):1205-1212.
17. Viscomi GN, Gonzalez R, Taylor KJ. Ultrasonic evaluation of hepatic and splenic trauma. *Arch Surg.* 1980; 115:320-21.