

Histological changes in the cerebellum of Rohypnol treated Wistar rats

Okwuonu Uche Christina¹, Uwagbor Victor Sola², Clement Timi Diepreye³, Iyemene P Tracy⁴

¹⁻⁴Department of Human Anatomy, School of Basic Medical Sciences, Igbinedion University, Okada, Edo, Nigeria

Abstract

Over the years, Orthodox medications are accessible for the treatment of chronic and acute medical conditions, a large portion of which are accessible over the counter (OTC) and are affordable. Some medications are named prescribed medications on the grounds that their use requires strict supervision by medical personnel. Both over the counter and doctor-prescribed medications are effectively abused among people in the general public. Rohypnol is a prescription drug that is otherwise called the "Date Rape Drug"; and is regularly utilized by Rapists to quell their victims as the medication has a high power and capacity to cause strong amnesia in victims. This study was designed to elucidate the effects that exposure to Rohypnol can cause in the cerebellar tissues of Wistar rats. The histological differences between the selected organ of control and treatment groups were evaluated. The results obtained showed notable changes within the layers of the cerebellum. The granular layer and white mater showed severe disruptions and vacuolations and vascular congestions. There was also reduction in number of purkinje cells within the purkinje layers. The results obtained from this current study indicate that Rohypnol was injurious to the cerebellum, and thus could lead to possible impairment of cognitive functions. It is therefore recommended that its arbitrary use should be discouraged and should only be used for therapeutic purposes under a Physician.

Keywords: rohypnol, cerebellum, cerebellar cortex, molecular layer, purkinje layer, granular layer

1. Introduction

Flunitrazepam (Rohypnol) is an N-fluorinated highly lipophilic benzodiazepine derivative that is medically used primarily as a sedative and hypnotic [1]. Rohypnol is a psychotropic fluorinated drug that causes simulative effects and depresses the central nervous system. Benzodiazepines are generally hypnotics that are used in short term treatment of insomnia, anxiolytic purposes, seizure disorders, and as pre-medication in anesthesia as well as skeletal muscle relaxant. The enormity of Benzodiazepines cannot be emphasized. Other examples include; alprazolam (Xanax), bromazepam chlordiazepoxide (Librium), Lorazepam (Atavan) and diazepam (Valium). Reports have shown an increase in the number of young women who are been sexually assaulted after unknowingly ingesting Rohypnol [2]. These reports however led to the media dubbing it as the date rape drug [2, 3, 4]. Flunitrazepam has also been reported to accelerate and enhance the effects of alcohol, marijuana and heroin or at times to moderate the stimulant or impulsive effects of cocaine, its use is reported to be one of the fastest growing drug problems in the world [5, 6, 7]. According to the national drug intelligence Centre, U.S Department of Justice, Rohypnol is an illegal drug and a schedule IV substance under the Controlled substance Act. People who abuse rohypnol usually experience one if not more of the following, confusion, tremor, drowsiness, dizziness, memory loss, headaches and nightmares. The abuse of these drugs have caused more harm than good as the people who consume them become highly disorientated; losing interest in schooling and eventually drop out and others have out rightly lost their lives [8]. The use of flunitrazepam following oral administration of a 2mg dose shows significant sedation within 20-30 minutes after ingestion. Peak sedation effects occur in 1-2 hours; but however, sedation may last up to 8-12 hours. The

cerebellum contributes to the body coordination, precision, and accurate timing. It lies in the posterior cranial fossa behind the pons and medulla. The cerebellum can become damaged through [5, 9]. Previous researches have been carried out to show the effect of rohypnol on memory, learning and coordination of activities. Rohypnol has also being studied in combination with alcohol showing its effect on sleep and memory [10]. Reports from these previous studies suggested impairment of memory from varied doses of rohypnol. This present study is aimed at elucidating the histological changes in the cerebellum of rohypnol treated wistar rats in a bid to determine whether or not it is injurious to the organ.

2. Materials and Methods

2.1 Drug collection

Rohypnol (Flunitrazepam, 90mg) was purchased at Don Joe Pharmacy, Okada, Edo State, Nigeria. The pills were manually grinded into powdery crystals using a laboratory mortar and pistol. The powdery crystals of Rohypnol were mixed with distilled water obtained from the Igbinedion University Teaching Hospital (IUTH), Okada, Edo State to form a homogenous mixture. The drug was administered twice daily at 8am and 5pm for 14 days.

2.2 Grouping of experimental animals

The rats were obtained from the animal holding of the School of Basic Medical Sciences, Igbinedion University. A total of twenty female Wistar albino rats weighing between 180g – 200g were used in this study, the animals were weighed and randomly divided into five groups of four rats each (Group A – Group E). Group A served as control and were given distilled water and feed only. Group B – E was administered with the homogenized mixture of Rohypnol and distilled water in the following doses: Group B received

0.5mg/kg body weight, Group C was given 1mg/kg body weight, Group D was given 1.5mg/kg body weight, and Group E received 2mg/kg body weight.

2.3 Tissue collection

The experimental animals were sacrificed 24 hours after the last administration by cervical dislocation. The skull was also cut open and the brains of the rats were also dissected out. The cerebellum was carefully dissected out and fixed in Bouin’s fluid for histological procedures.

2.4 Histological Studies

The cerebellum tissues were fixed in Bouin’s fluid and dehydrated using graded concentrations of absolute alcohol. The tissues were cleared by passing through xylene baths, followed by impregnation in paraffin wax. Sections were cut using a microtome and stained with Erlich's Haematoxylin (H) and Eosin (E). The slides were examined microscopically, using a light microscope with digital camera and micrographs were taken.

3. Results

3.1 Histological changes in the cerebellum

Histological studies on the cerebellum of wistar rats in the control group (Plate 1) showed normal histology of cerebellum with molecular layer, purkinje cell layer and granule layer. It also revealed large shaped piriform shaped purkinje cells and numerous thickly populated cells in the granular layer as well as a well-oriented cerebellar island housing the glomeruli. The results of the group of rats administered 0.5mg/kg of Rohypnol showed fairly normal cerebellar architecture with few vacuolations (Plate 2) while the group administered 1mg/kg of Rohypnol showed disruptions across the granular layer (Plate 3). The group treated with 1.5mg/kg of Rohypnol (Plate 4) showed severe disruptions and formations of vacuoles along the granular layer, focal area edema and disintegration of granule cells. The cerebellum of the group of rats treated with 2.0mg/kg of Rohypnol (Plate 5) showed cortical disruptions and vascular congestions within granular layer relative to control.

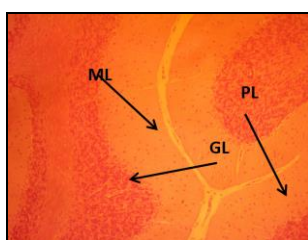


Plate 1: Micrograph of the cerebellum of a control rat showing normal histology of cerebellum with molecular layer (ML), purkinje cell layer (PL) and granule layer (GL) H and E stains. Mag. X100

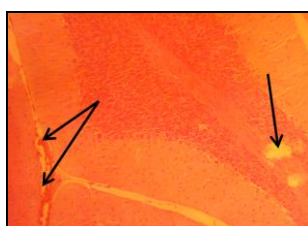

Plate 2: Photomicrograph of the cerebellum of a rat administered 0.5mg/kg of Rohypnol showing fairly normal cerebellar architecture with few vacuolations H and E stain. Mag. X100

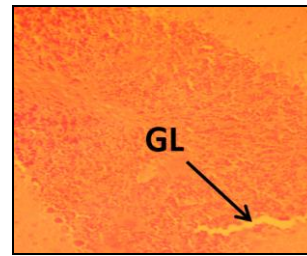


Plate 3: Photomicrograph of the cerebellum of a rat administered 1mg/kg of Rohypnol showing disruptions across granular layer. H and E stain. Mag. X100

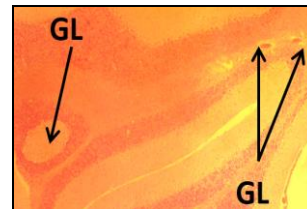


Plate 4: Photomicrograph of the cerebellum of a rat administered 1.5mg/kg of Rohypnol showing severe disruptions and formations of vacuoles along the granular layer, focal area edema and disintegration of granule cells H and E stain. Mag. X100



Plate 5: Photomicrograph of the cerebellum of a rat administered 2.0mg/kg of Rohypnol showing cortical disruptions and vascular congestions within granular layer. H and E stain. Mag. X100

4. Discussion

Rohypnol is presently one of most abused drugs amongst university undergraduates. While some take it exclusively and arbitrarily others combine it with alcohol and/or tramadol as reported in a previous study [11]. A previous study has reported that the development of different parts of the brain, including the cerebellum, is affected by rohypnol exposure during prenatal and postnatal periods in rats [12]. In this present study, varied doses of Rohypnol caused dose dependent disruptions in the histoarchitecture of the treated groups relative to the control group and this is in agreement with the findings of Tewari, who reported that adult cerebellum is also susceptible to the damaging effects of rohypnol treatment by causing a significant depletion of the white core of cerebellum [13]. These disruptions were significantly seen mostly in the granular layer of the cerebellar cortex. FocalOtnbamike areas of vascular congestions were also seen along the white mater. The result of this study is in line with Opanashuk and colleagues [14] who stated in their work that increasing dosage of rohypnol causes a progressive loss of white matter, which also correlates with the work of Tewari [13] which, revealed that long-term rohypnol exposure during adulthood resulted in loss of white matter of the cerebellum in rat model. Earlier studies with rohypnol have also shown that administration of rohypnol specifically inhibits cerebellar Purkinje cells [15], which could result in the reduction of Purkinje cells, and consequently, reduction in the middle Purkinje cell layer of the cerebellum. In this study, focal disruptions and

degeneration of the granular layer was recorded which may have affected the purkinje cells resulting from the close relations between the granular and Purkinje cell layer. Again, vacuolations which arises from loss of cellular materials or components degeneration was recorded and this may have caused adverse reductions in the population of purkinje cells in the treatments. These degenerative changes may be a pointer to neurotoxicity elicited by the drug.

Conclusion

The increased exposure to rohypnol causes progressive disruptions on cerebellar cytoarchitecture, which could serve as basis for some cerebellar lesions that could result in clinical conditions such as meningitis, headache, stroke, cerebella edema, vasculitis, and dementia, ataxia, tremors, gait disorders and speech disorders. We therefore conclude that these degenerative changes may hamper cerebellar functionality.

Acknowledgement

The Authors wish to acknowledge the technical support received from the entire technical team of the Department of Anatomy, Igbinedion University, Okada.

References

- Owolabi JO, Olatunji SY, Olanrewaju JA, Okeya O. Modelling Rohypnol [Flunitrazepam] and Alcohol Abuse and Resultant Effects on Hippocampal Histoarchitecture and Biochemicals in Wistar Rats. *American Journal of Laboratory Medicine*. 2017; 2(6):112-118.
- Saum Christine A, James A Inciardi. Rohypnol Misuse in the United States. *Substance Use and Misuse*. 1997; 32:723-731.
- Schwartz RH, Weaver AB. Rohypnol, the date rape drug. *Clinical pediatrics*, 1998; 37:321.
- Anglin D, Spears KL, Huston HR. Flunitrazepam and its involvement in date or acquaintance rape. *Academic emergency medicine*. 1997; 4:323-326.
- San L, Tato J, Torrens M, Castillo C, Farre M, Cami J. Flunitrazepam consumption among heroin addicts admitted for in-patient detoxification. *Drug Alcohol Dependence*. 1993; 32:281-286.
- Calhoun Sarah R, Wesson DR, Galloway GP, Smith DE. Abuse of flunitrazepam (Rohypnol) and other benzodiazepines in Austine and Texas. *Journal of Psychoactive Drugs*. 1996; 28:183-189.
- Heyndrickx B. Fatal intoxication due to flunitrazepam. *Journal of Analytical Toxicology*. 1987; 11(6):278.
- Hausmann R, Seidl S, Betz P. Hypoxic changes in Purkinje cells of the human cerebellum. *International journal of legal medicine*. 2007; 175:83-121
- Druid H, Holmgren P, Ahlner J. Flunitrazepam: an evaluation of use, abuse and toxicity. *Forensic science international*. 2001; 122(2-3):136-41.
- Dåderman AM, Lidberg, L. Flunitrazepam (Rohypnol) abuse in combination with alcohol causes premeditated, grievous violence in male juvenile offenders. *Journal of American Academic Psychiatry Law*. 1999; 27(1):83-99.
- De Almeida RM, Saft DM, Rosa MM, Miczek KA. Flunitrazepam in combination with alcohol engenders high levels of aggression in mice and rats. *Pharmacological and Biochemical Behaviour*. 2010; 95(3):292-297.
- Dwyer JB, McQuown SC, Leslie FM. The dynamic effects of rohypnol on the developing brain. *Pharmacological Therapy*. 2009; 122(2):125-39.
- Tewari A, Hasan M, Sahai A, Sharma PK, Rani A, Agarwal AK, *et al*. White core cerebellum in rohypnol treated rats: a histological study. *Journal of Anatomical Society of India*. 2010; 59(2):150-153.
- Opanashuk LA, Pauly JR, Hauser KF. Effect of nicotine on cerebellar granule neuron development. *European Journal of Neuroscience*. 2001; 13(1):48-56.
- De la Garza R, Freedman R, Hoffer J. Rohypnol-induced inhibition of cerebellar Purkinje neurons: specific actions of rohypnol and selective blockade by mecamlamine. *Neuropharmacology*. 1989; 28(5):495-501.