



Efficacy of 2mm locking mini plates in the management of mandibular fractures without IMF: A prospective study

Balaji R Shenoi¹, Nikhil O Govindan²

¹ Associate Professor, Department of Oral and Maxillofacial Surgery, Mount Zion Medical College and Hospital, Adoor, Kerala, India

² Clinical Head, Department of Maxillofacial, Cleft and Esthetic Surgery, Sun Research Hospital, Trichur, Kerala, India

Abstract

Aim: The management of trauma has evolved greatly over the past many years. Various bone plating systems have been developed to provide stable fixation of mandibular fractures. The introduction of the locking plate/screw system has offered certain advantages over the conventional plating systems. This system does not require intimate adaptation of the miniplates to the underlying bone and has greater stability. This study evaluates the efficacy of locking miniplate/screw system in the treatment of mandibular fractures without maxillomandibular fixation.

Materials and Methods: This was a prospective study analyzing 20 patients with undisplaced or minimally displaced mandibular fractures, who reported to Department of Maxillofacial, cleft and esthetic surgery, Sun research hospital, trichur, kerala. The selected cases were treated by open reduction and internal fixation using the 2.0 mm locking plate/screw system.

Results: Open reduction and internal fixation with the 2.0 mm locking plate/screw system were achieved in all the 20 cases with satisfactory stability of the fracture fragments. The system was found to be reliable and effective intraoperatively. Only two complications were noted in the study.

Conclusion: The locking miniplate system was found to be reliable and effective in management of mandibular fractures without postoperative intermaxillary fixation, however further studies with more sample size is required.

Keywords: locking plate/screw system, locking miniplates, mandibular fractures

Introduction

The management of trauma has evolved greatly over the past many years from supportive bandages, splints, circummandibular wiring, extraoral pins, and semi-rigid fixation with transosseous wiring to rigid fixation with compression plates and more lately back to semi-rigid fixation with miniplates^[1, 2]. Mandibular fractures are the most common facial injuries treated by the oral and maxillofacial surgeon. Fractures of the mandible occur more frequently than any other fracture of the facial skeleton^[1, 2]. Rigid internal fixation of mandibular fractures eliminates the need for intermaxillary fixation and facilitates stable anatomic reduction while reducing the risk of postoperative displacement of the fractured fragments, allowing immediate return to function^[3, 5]. In the 21st century, the near total abolition of maxillomandibular fixation in the treatment of mandibular fractures is a major step in the evolution of maxillofacial trauma management due to advent of various plating systems^[3, 5]. Transoral placement of noncompressive miniplate fixation has gained popularity using the principles of Champy and colleagues. Various types of bone-plating systems have been developed to provide stable fixation for mandibular fractures and osteotomies^[6, 7]. Currently, modifications in miniplates, like locking plate/screw system, have been developed^[7]. The introduction of locking plate/screw miniplate and reconstruction plating systems for the treatment of mandibular fractures and continuity defects has offered certain advantages over other plating systems. A major

disadvantage of the conventional bone plate is that it must be perfectly adapted to the underlying bone to prevent alterations in the alignment of the segments and changes in the occlusal relationship^[8, 9].

Research continues to focus on the size, shape, number, and biomechanics of plate/screw systems to improve surgical outcomes. In locking plate/screw system, the hole in the plate is engineered to accept screws that lock to it by a second thread under the head of the screw. These plates function as internal fixators achieving stability by locking the screw to the plate^[7, 9]. A unique advantage of the locking plate/screw system is that it becomes unnecessary for the plate to have intimate contact with the underlying bone, making plate adaptation easier leading to lesser alterations in the alignment of the segments and changes in the occlusal relationship upon screw tightening^[10, 11].

Another theoretical advantage in the locking plate/screw system is that these plates do not disrupt the underlying cortical bone perfusion as much as the conventional plates, which compress the undersurface of the bone plate to the cortical bone^[10, 11]. A third advantage of the locking plate/screw system is that the screws are unlikely to loosen from the bone plate. This means that even if the screw is inserted into the fracture line, loosening of the screw will not occur. The possible advantage to this property of a locking plate/screw system is decreased incidence of inflammatory complications from loosening of hardware^[10, 12]. The purpose of this study was to review the efficacy of this new locking bone plate or screw system without post-

surgical maxillomandibular fixation in mandibular fractures.

Materials and Methods

This was a prospective study analyzing 20 patients with undisplaced or minimally displaced mandibular fractures, having insignificant medical history. The data were randomly collected from the patients visiting the department of maxillofacial, cleft and esthetic surgery, sun research hospital, trichur. The selected cases were treated by open reduction and internal fixation with 2.0 mm titanium locking miniplates. Inclusion criteria were undisplaced or minimally displaced fractures of the mandible requiring open reduction and internal fixation in any one of the following regions: symphysis, parasymphysis and body or angle region. Exclusion criteria were fractures infected prior to treatment, comminuted fractures or mandibular fractures with associated condylar and coronoid fractures and patients with compromised medical conditions.

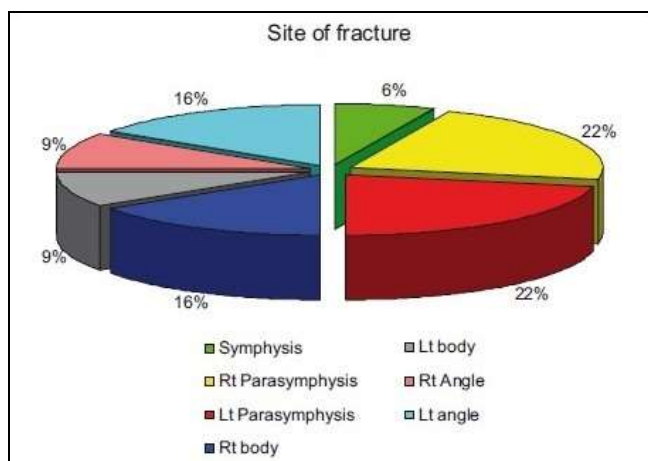
Results

Among the study population, the majority of cases were in the age group of 21-30 years (65%) with a mean age of 28.8 years. There were 19 (95%) male and 1 (5%) female patient of Asian origin, with road traffic accident (RTA) being the most common etiological cause 11 (55%), followed by assault 5 (25%), and work-related or self-fall 4 (20%) [Table 1].

Table 1: Cause of injury

Cause of injury	n	%
Road traffic accident	11	55.00
Work-related/self-fall	4	20.00
Assault	5	25.00
Sports injury	0	0.00
Miscellaneous	0	0.00
Total	20	100

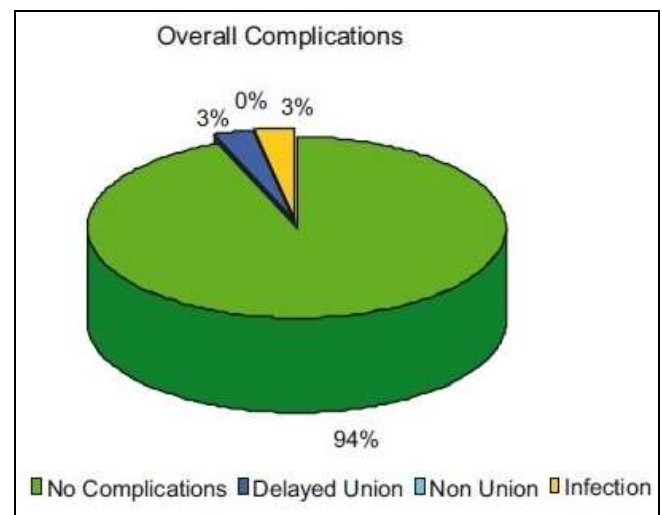
Fracture distribution consisted of 14 parasymphysis (43.75%), 2 symphysis (6.25%), 8 body (25%) and 8 angle (25%) fractures, with a total of 32 fracture sites in the 20 cases selected, with 15 fractures distributed on both left and right sides of the mandible [Graph 1]. There were 13 undisplaced and 7 minimally displaced fractures observed. Teeth in fracture line were retained in 15 (75%) cases and extracted in 5 (25%) cases. Teeth were extracted only when there was an absolute indication, with the most common reason being fractured teeth.



Graph 1

Distribution of site of fracture

The fractures were treated ranging from 1 to 5 days with a mean of 1.8 days from the time of injury. The fractures were approached intraorally in 15 (75%) cases, a combination of both intraoral and extraoral approach was used when extraoral lacerations were present in 4 (20%) of the cases and 1 (5%) fracture was approached through an external laceration. All the patients were followed up for postoperative complications initially on a weekly basis for 6 weeks and later monthly till 6 months. A minor complication (3.125%) of wound dehiscence was noted which was treated with wound irrigation and local measures. There was one major complication with infection (3.125%) at fracture site, requiring incision and drainage and subsequent miniplate removal after 5 weeks of fracture treatment. This patient was placed on an 8-day period of Maxillomandibular fixation. The infection resolved after hardware removal and the fracture showed delayed healing during the follow-up period. The other fracture sites healed without any complications. Primary bone healing was noted in the 93.75% of fracture sites with overall postoperative complications of 6.25% in the study [Graph 2].



Graph 2

Overall complications

Discussion

The objective in the treatment of mandibular fracture is to re-establish normal occlusion and masticatory function. Conservative treatment to achieve this is performed by immobilizing the mandible for the healing period by intermaxillary fixation which is achieved by dental wiring, arch bars, cap splints, and gunning splints [11, 12]. Operative treatment of mandibular fractures involves intraoral or extraoral opening of the fracture site and direct osteosynthesis with transosseous wires (Schwenzes 1982), lag screws (Niederdelmann 1982), or bone plates (Schilli 1975, Spiessel 1976) [13, 15].

A number of fixation methods have been advocated for the treatment of mandibular fractures. A new type of plating system is “the locking plate/screw system”, which was initially developed by Raveh *et al.* [16] In the mid-1980s, the principles of external fixation device were incorporated into a bone plate. These plates achieve stability by locking the screw into the plate and have been shown to enhance fixation stability. A unique advantage to the locking

plate/screw system is that it becomes unnecessary for the plate to have intimate contact with the underlying bone, making plate adaptation easier leading to lesser alterations in the alignment of the segments and changes in the occlusal relationship upon screw tightening^[17, 18].

Another theoretical advantage in the locking plate/screw system is that these plates do not disrupt the underlying cortical bone perfusion as much as the conventional plates which compress the undersurface of the bone plate to the cortical bone (Edward Ellis III and John Graham 2002)^[19, 20]. A third advantage of the locking plate/screw system is that the screws are unlikely to loosen from the plate. This means that even if the screw is inserted into the fracture line, loosening of the screw will not occur. The possible advantage to this property of the locking plate/screw system is decreased incidence of inflammatory complications from loosening of hardware (Reza Bolourian 2002)^[21]. It is also proposed that this system provides greater stability that provided by the standard conventional miniplate (Edward Ellis III and John Graham 2002)^[22].

It is observed that the degree of plate adaptation affected the mechanical behavior of nonlocking plates but did not affect the locking plate/screw system. The only exception is that one should use a drill guide to "center" the drill hole within the center of bone plate to facilitate proper screw locking to the plate (Brain Alpert, Rolf Gutwald, and Rainer Schmelzeisen 2003)^[23, 24].

The screws, plate and bone form a solid framework with higher stability than the traditional miniplate system. The locking plate/screw system has demonstrated higher stability across a fracture/osteotomy gap compared with the conventional nonlocking 2.0 mm miniplate in *in vitro* studies^[25].

Our study reviews the efficacy of 2.0-mm locking plate/screw system in 20 patients requiring open reduction and internal fixation without maxillomandibular fixation. The patients were evaluated for the location, type and number of fractures; presence of tooth in line, time elapsed between the presentation of the patient after trauma, pre and post-surgical occlusal relationship, adequacy of reduction on postoperative radiograph, and any post-surgical complications requiring a secondary surgical intervention.

In this study, 32 fractures were observed in the 20 patients selected. Open reduction and internal fixation was carried out in standard operating protocol using either an intraoral or an extraoral approach. The system was found to be reliable and effective treatment modality of mandibular fractures. Our observations do correlate with those of the study conducted by Ayman Chritah, Stewart K Lazow, and Julius R Berger (2005)^[26, 27].

Postoperative complications were noted in two patients. One developed an intraoral wound dehiscence which was treated with antibiotics and local measures. There was one major complication (3.125%) with infection at fracture site requiring incision and drainage and subsequent miniplate removal after 5 weeks of fracture treatment. Primary bone healing was noted in 93.75% of fracture sites with an overall postoperative complication of 6.25% in the study. Our study observations do correlate with those of the study conducted by Edward Ellis III and John Graham (2002)^[28].

In this study, a sincere attempt was made to clinically evaluate the efficacy of 2.0 mm locking plate/screw system in treatment of mandibular fractures without maxillomandibular fixation and the results of this study are

in accordance with the study conducted by different authors.

Conclusion

The locking miniplate system was found to be reliable and effective in management of mandibular fractures without postoperative intermaxillary fixation, however further studies with more sample size is required.

References

1. Lindqvist C, Kontio R, Pihakari A, Santavirta S. Rigid internal fixation of mandibular fractures - an analysis of 45 patients treated according to the ASIF method. *Int J Oral Max Fac Surg*, 1986; 15:657-64. [PubMed] [Google Scholar]
2. Ellis E. 3rd Rigid skeletal fixation of fractures. *J Oral Maxillofacial Surg*, 1993; 51:163-73. [PubMed] [Google Scholar]
3. Iizuka T, Lindqvist C, Hallikainen D, Pauku P. Infection after rigid internal fixation of mandibular fractures: A clinical and radiologic study. *J Oral Max Fac Surg*, 1991; 49:585-93. [PubMed] [Google Scholar]
4. Ellis E, 3rd, Walker L. Treatment of mandibular angle fractures using two noncompression miniplates. *J Oral Maxillofac Surg*, 1994; 52:1032-6. [PubMed] [Google Scholar]
5. Ellis E, 3rd, Graham J. Use of 2.0 mm locking plate/screw system for mandibular fracture surgery. *J Oral Max Fac Surg*, 2002; 60:642-5. [PubMed] [Google Scholar]
6. Herford AS, Ellis E. 3rd Use of locking reconstruction bone plate/screw system for mandibular surgery. *J Oral Max Fac Surg*, 1998; 56:1261-5. [PubMed] [Google Scholar]
7. Frigg R. Development of the locking compression plate. *Injury*, 2003; 34:B6-10. [PubMed] [Google Scholar]
8. Alpert B, Gutwald R, Schmelzeisen R. New innovations in craniomaxillofacial fixation: The 2.0 lock system. *Keio J Med*, 2003; 52:120-7. [PubMed] [Google Scholar]
9. Gutwald R, Alpert B, Schmelzeisen R. Principle and stability of locking plates. *Keio J Med*, 2003; 52:21-4. [PubMed] [Google Scholar]
10. Collins CP, Pirinjian-Leonard G, Tolas A, Alcalde R. A prospective randomized clinical trial comparing 2.0-mm locking plates to 2.0-mm standard plates in treatment of mandible fractures. *J Oral Maxillofac Surg*, 2004; 62:1392-5. [PubMed] [Google Scholar]
11. Mukerji R, Mukerji G, McGurk M. Mandibular fractures: Historical perspective. *Br J Oral Maxillofac Surg*, 2006; 44:222-8. [PubMed] [Google Scholar]
12. Chuong R, Donoff RB, Guralnick WC. A Retrospective analysis of 327 mandibular fractures. *J Oral Max Fac Surg*, 1983; 41:305-9. [PubMed] [Google Scholar]
13. Dodson TB, Perrott DH, Kaban LB, Gordon NC. Fixation of mandibular fractures: A comparative analysis of rigid internal fixation and standard fixation techniques. *J Oral Max Fac Surg*, 1990; 48:362-6. [PubMed] [Google Scholar]
14. Valentino J, Marentere LJ. Supplemental maxillomandibular fixation with miniplate osteosynthesis. *Otolaryngol Head Neck Surg*, 1995; 112:215-20. [PubMed] [Google Scholar]

15. Herford AS, Ellis E. 3rd Use of a locking reconstruction bone plate/screw system for mandibular surgery. *J Oral Maxillofac Surg*, 1998; 56:1261-5. [PubMed] [Google Scholar]
16. Potter J, Ellis E. 3rd Treatment of mandibular angle fractures with a malleable noncompression miniplate. *J Oral Maxillofac Surg*, 1999; 57:288-92. [PubMed] [Google Scholar]
17. Feller KU, Schneider M, Hlawitschka M, Pfeifer G, Lauer G, Eckelt U, *et al.* Analysis of complications in fractures of the mandibular angle – a study with finite element computation and evaluation of data of 277 patients. *J Craniomaxillofac Surg*, 2003; 31:290-5. [PubMed] [Google Scholar]
18. Ardekian L, Rosen D, Klein Y, Peled M, Michaelson M, Laufer D, *et al.* Life-threatening complications and irreversible damage following maxillofacial trauma. *Injury*, 1998; 29:253-6. [PubMed] [Google Scholar]
19. Sikes JW, Jr, Smith BR, Mukherjee DP, Coward KA. Comparison of fixation strengths of locking head and conventional screws, in fracture and reconstruction models. *J Oral Maxillofac Surg*, 1998; 56:468-73. [PubMed] [Google Scholar]
20. Villarreal PM, Junquera LM, Martínez A, García-Consuegra L. Study of mandibular fracture repair using quantitative radiodensitometry: A comparison between maxillomandibular and rigid internal fixation. *J Oral Maxillofac Surg*, 2000; 58:776-81. [PubMed] [Google Scholar]
21. Schmidt BL, Kearns G, Gordon N, Kaban LB. A financial analysis of maxillomandibular fixation versus rigid internal fixation for treatment of mandibular fractures. *J Oral Maxillofac Surg*, 2000; 58:1206-10. [PubMed] [Google Scholar]
22. Hirai H, Okumura A, Goto M, Katsuki T. Histologic study of the bone adjacent to titanium bone screws used for mandibular fracture treatment. *J Oral Maxillofac Surg*, 2001; 59:531-7. [PubMed] [Google Scholar]
23. Aframian-Farnad F, Savadkoobi F, Soleimani M, Shahrokhnia B. Effect of maxillomandibular fixation on the incidence of postoperative pulmonary atelectasis. *J Oral Maxillofac Surg*, 2002; 60:988-90. [PubMed] [Google Scholar]
24. Haug RH, Street CC, Goltz M. Does plate adaptation affect stability? a biomechanical comparison of locking and nonlocking plates' *J Oral Maxillofac Surg*, 2002; 60:1319-26. [PubMed] [Google Scholar]
25. Cabrini Gabrielli MA, Real Gabrielli MF, Marcantonio E, Hochuli-Vieira E. Fixation of mandibular fractures with 2.0-mm miniplates: Review of 191 cases. *J Oral Maxillofac Surg*, 2003; 61:430-6. [PubMed] [Google Scholar]
26. Kirkpatrick D, Gandhi R, Van Sickels JE. Infections associated with locking reconstruction plates: A retrospective review' *J Oral Maxillofac Surg*, 2003; 61:462-6. [PubMed] [Google Scholar]
27. Bolourian R, Lazow S, Berger J. Transoral 2.0-mm miniplate fixation of mandibular fractures plus 2 weeks' maxillomandibular fixation: A prospective study. *J Oral Maxillofac Surg*, 2002; 60:167-70. [PubMed] [Google Scholar]
28. Chritah A, Lazow SK, Berger JR. Transoral 2.0-mm locking miniplate fixation of mandibular fractures plus 1 week of maxillomandibular fixation: A prospective study. *J Oral Maxillofac Surg*, 2005; 63:1737-41. [PubMed] [Google Scholar]