



Outcome of different types of osteotomy in primary and revision rhinoplasty

*¹ Dr. Mohammed Saad EIDin Ali, ² Waed S Jameel, ³ Noran AM Sultan, ⁴ Ahmad A Mirza, ⁵ Lamees IH Filimban, ⁶ Moath MS Alshanjity, ⁷ Ziad A Alahmadi, ⁸ Alhareth A Baarimah, ⁹ Amjad A Saifaldien

¹ Consultant of Otorhinology, King Abdullah Medical City, Makkah, Saudi Arabia

^{2,3,6,7} Medical Intern, Umm Al-Qura University, Makkah, Saudi Arabia

⁵ Internal Medicine Resident, AlNoor Specialist Hospital, Makkah, Saudi Arabia

⁴ Collage of Medicine, Taif University, Taif Saudi Arabia

⁸ Urology Resident, International Medical Center, Jeddah, Saudi Arabia

⁹ Ophthalmology unit, King Feisal medical complex, Taif, Saudi Arabia

Abstract

Objective: Rhinoplasty enhances facial harmony and the proportions of the nose. The ultimate goal of our research was to observe variations between two techniques of lateral osteotomies, low-to-low and low-to-high, to weigh the advantages and disadvantages of each and to measure overall patient fulfilment.

Methods: This is a retrospective cohort study contained 104 patients, all above 18 years of age, who had undergone rhinoplasty surgery via one of two different techniques used for lateral osteotomy. Seventy patients underwent the low-to-low technique, and 34 patients underwent the low-to-high technique. All 104 patients had some sort of nasal deformity. Our research compared the ventral width, patient satisfaction in breathing and aesthetic considerations both pre and postoperatively.

Results: The statistical analysis, through aesthetic calculations, showed a significant variation in the results for patient satisfaction and a ventral width measurement of $P < .0001$. Of the low-to-low group, 95.7% reached an ideal ventral width, according to the Arabic nose values; in contrast, in the low-to-high group, only 52.9% reached that result. The breathing result was unremarkable postoperatively at $P < .78$.

Conclusion: The aesthetic view of the low-to-low group results showed a statistically significant number of patients who had almost reached the ideal measurements of $P < .0001$. However, patient satisfaction in breathing and quality of life improved in both groups equally.

Keywords: rhinoplasty, lateral osteotomies, low-to-low osteotomies and low-to-high osteotomies

Introduction

Abnormality in the appearance of the nose called nasal deformity, which is due to either a congenital defect or trauma. In traumatic cases, patients often present with combined functional and cosmetic complaints, and the anatomical alterations are mostly complex. Patients who undergo surgery for a functional problem frequently appreciate the aesthetic point of the operation, even though it is mainly for functionality. While surgeons in modern nasal surgery must consider the cosmetic appearance of the nose, the main goal is to reach optimal nose function while maintaining a natural shape [1, 4]. It is a complicated procedure with many steps, and different techniques vary according to the school of rhinoplasty. Each technique has its pros and cons; hence, there is no certain technique that is recommended for all cases. The chosen procedure depends upon the patient's preoperative evaluation, which is done through an examination and review of radiological imaging and digital photographs [2, 5].

Nasal osteotomy is a blind manipulation of the nasal bony parts, which is done to improve the appearance of the nose. Lateral osteotomy is the most common procedure used to

narrow the nose and create symmetry through either the low-to-low or low-to-high technique [1, 4, 6, 7].

Objectives: In the current study, a comparison of the widths of the nasal bases (ventral), pre and postoperatively, following two types of lateral nasal osteotomy: low-to-high and low-to-low, as well as the patients' breathing and aesthetic satisfaction was taken, using a 5-point Likert scale, during pre and postoperative evaluations of both groups.

Patients and Methods

A) Study Design and Population

A retrospective study was approved by an institutional review board (IRB) and took place from January 2013 to January 2015 at King Abdullah Medical City (KAMC), Makkah, Saudi Arabia. Authors declare that they have obtained written informed consent from the patient for publication of this research and accompanying images. All subjects underwent primary or revision rhinoplasty, with either lateral high-to-low or lateral low-to-high osteotomies. All participants in our study were Saudis, aged 18 years and above, had a nasal deformity or had nasal obstructive symptoms due to direct

nasal trauma or birth trauma. All target individuals were otherwise healthy. On the other hand Non-Saudi patients, those aged below 18 years or had a complaint of aesthetic issues with no clinical symptoms of obstruction were excluded from the study. Subsequently, all individuals were categorized into two different groups: group I included those who had undergone lateral low-to-low osteotomy (70 patients), and group II constituted of those who had undergone a lateral low-to-high osteotomy (34 patients). A written consent was obtained from each individual who participated in the study.

B) Preoperative Evaluation

All subjects were examined preoperatively after a lateral osteotomy had been indicated. All study groups had symptoms of nasal obstruction, a total of 66 patients complained of hyposmia and 11 were suffering from sinusitis during the preoperative evaluation. A digital camera (model D3200 Nikon) was used to capture Frontal photographs of the patients, with an 18–55mm lens in a standardized setting by a single photographer. The ventral (VW) widths were measured on the frontal view using the photograph analysing software “Screen Ruler”, version 2.5. By convention, the inter-pupillary distance (IP) was equally fixed at 30 mm on all photographs to standardize the comparisons of VW Figure1. Therefore, VW/IP was calculated as objective measures to assist in comparing the two surgical techniques (low-to-low osteotomy vs. low-to-high osteotomy). The ventral width was defined as the distance between the points at which the flattened surface of the maxilla meets the ascending nasal process of the maxilla. In addition, the functional breathing and subjective aesthetic satisfaction scores from each patient was obtained based on a five-point Likert scale (1 = highly dissatisfied to 5 = highly satisfied).

C) Surgical Procedure

The main author Mohammed. S performed all surgical procedures; each patient underwent general anaesthesia. Individuals of group I were planned to have an open technique using three different approaches: 59 patients were operated on with an external approach (continuous percutaneous), 10 patients had an internal approach (trans-nasal continuous) and one patient underwent a trans-oral approach. On the contrary patients in-group II had a closed technique, which was approached by an external percutaneous perforated lateral osteotomy.

Multiple procedures were conducted during the rhinoplasties including septoplasty, nasal tip correction, radix surgery, dorsal smoothing and hump reduction or dorsal augmentation. Ultimately, lateral nasal osteotomy was used in all the targeted patients to correct the defect (e.g. open roof) and narrow the basal breadth.

During the lateral osteotomy, in the two groups, 20 ml of 2% lidocaine with 1:100,000 epinephrine was injected along the lateral nasal sidewall and intra-nasally bilaterally, allowing seven minutes for the haemostatic effect of epinephrine to take place. The surgeon used a flat 2 mm osteotome after it was

Sharpened by a surgical stone, rinsed with saline solution, wiped with a clean towel and rinsed again to remove all dust. In the trans-nasal approach, a guarded osteotome was used instead. During the open technique, a trans-columellar incision was made, while a transfixing (trans-oral) incision was made in the closed technique.

In the perforated percutaneous lateral osteotomy, which was used in the low-to-low group, the sharpened osteotome was introduced percutaneously at the midportion of the bony nasal pyramid at the level of the inferior orbital rim and naso-facial junction parallel to the horizontal surface of the maxilla. After that, the osteotome was swept down the mucoperiosteum to avoid injury to the angular artery. The osteotome was kept at an angle so that only one corner of the edge was in contact with bone. The surgeon then struck the area with a mallet until there was a change in both the feeling and sound heard. Multiple interrupted osteotomies were performed, spaced 2 mm apart, in the configuration of the low-to-low, which began above the Webster triangle and low along the piriform aperture it remained low along the base of the bony vault, ending at a location near the inter-canthal line. Then, a medial oblique osteotomy was done for all cases in the low-to-low group trans-nasally using a notched osteotome. Finally, a green stick fracture was used to correct the nasal bones via gentle pressure between the thumb and forefinger, which followed the predictable fracture patterns, based on the nasal bone thickness and perforated osteotomy.

Conversely, the continuous percutaneous lateral osteotomy used in the low-to-high osteotomy started above the Webster triangle and moved towards the nasal dorsum and away from the intercanthal line using the same 2 mm osteotome that was used in the previous technique. Then, a Para-median osteotomy was performed in all low-to-high patients.

After bilateral osteotomies were completed in both groups, gentle sustained pressure was applied to prevent bleeding and ecchymosis, the skin was cleaned with alcohol, adhesive Steri-strips were applied and an external thermoplasty was placed for three weeks. The thermoplasty for each patient was changed every seven days to minimize postoperative oedema. After the surgery, we prescribed antibiotic therapy as well as painkillers. In addition, surgical sutures were removed on postoperative day seven for all cases.

D) Postoperative Evaluation

In both categories the subjects had a minimum of a one-year follow up postoperatively. Few major and minor postoperative complications were reported including septal perforation (1), saddle nose (4), dorsal irregularity (10) and nasal valve opening (1). Other complications, such as bleeding or infection, were not found among the study patients. A postoperative picture was captured using the same digital camera to evaluate the comparable widths (VW) for each patient at least one year after the surgery. In addition, the postoperative satisfaction scores of the breathing and aesthetic aspects were recorded for both groups at the same time.

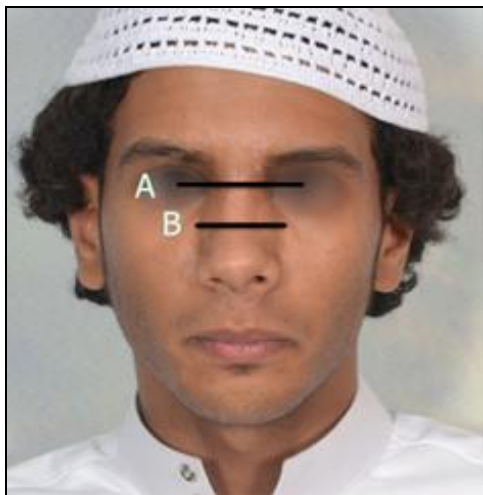


Fig 1: A) Intra-pupillary line measurement, B) Ventral width measurement.

Results

Description of the studied population

Data were collected from 104 patients, of whom 72 were men and 32 were women. The low-to-low group consisted of 70 patients, and 34 patients underwent the low-to-high procedure. Multiple deformities were present in both groups including radix depression, deviated nose, saddle nose, dorsal irregularity and nasal hump deformities, which were found in 14, 26, 22, 90 and 50 patients, respectively. They collectively required lateral nasal osteotomy as a part of their rhinoplasty.

The ventral width ratios (objective measures)

Using the crosstab and chi-square tests, the ventral width measurement preoperatively in group I, with 69 patients, and in group II, with 34 patients, was at >30% of their inter-pupillary distance. Only one patient in group I and none in group II were at ≤30% of their inter-pupillary distance. Postoperative measurement of the ventral width in group I was 67(95.7%) patients, and in group II, it was 18(52.9%) patients at ≤30% of their inter-pupillary distance. In group I, three (4.3%) patients and in group II, 16(47.1%) patients were at >30% of their inter-pupillary distance, with a P-value<.0001, table1.

Breathing and aesthetic satisfaction scores (subjective measures)

Regarding the breathing satisfaction level in both categories, there was no remarkable difference in breathing satisfaction postoperatively (p = 0.78) using the chi-square test. However, among the low-to-high group, none of the individuals reported a score of 4 or 5 preoperatively, while in the other group, 27.2% had a satisfaction level of 4 or 5.

Postoperatively, our results showed that the aesthetic aspect of the low-to-low procedure was significantly superior (p < 0.001). In fact, none of the low-to-low individuals had a score lower than 3, and a bigger proportion of low-to-low candidates were included within the scores of 4 and 5, indicating their favourable satisfaction (97.2%).

Discussion

The majority of the patients included in the study had undergone a primary rhinoplasty; however, 23 individuals had undergone previous surgery to the nose, i.e. revision rhinoplasty (5.8%). Lateral nasal osteotomy involved in reduction rhinoplasty was suggested for all participants in the present study. However, other procedures were indicated among a proportion of patients in both categories, according to their situations, to ensure that all deformities were corrected during the proposed rhinoplasty. For instance, nasal tip correction was performed in 68 patients, and nasal augmentation encompassing the nasal dorsum and radix was executed in 22 and 26 patients, respectively. Sixty patients had a spreader graft placed on the septum during the rhinoplasty procedure to prevent an inverted V deformity. Moreover, other intraoperative procedures involved in nasal endoscopy and laser-assisted turbinoplasty, in addition to rhinoplasty, were performed among 64 patients and five patients, respectively.

The need for a lateral osteotomy became mandatory Because our cases all had some sort of nasal deformity and their ventral widths became wider, Lateral osteotomies are known to result in complications such as nasal obstruction due to excessive narrowing, open roof deformity and Westernization of a Middle Eastern nose.^[1, 8]

When comparing between lateral nasal osteotomy techniques, the low-to-low created a narrower.

Table 1: The analysis of pre and postoperative Ventral Width for Low-to-low and Low-to-high lateral osteotomies.

IP	Preoperative VW		Postoperative VW	
	≤30% of IP DC	>30% of IP DC	≤30% of IP DC	>30% of IP DC
Low-to-low (Group I)	1 (100%)	69 (67%)	67 (95.7%)	3 (4.3%)
Low-to-high (Group II)	0 (0%)	34 (100%)	18 (52.9%)	16 (47.1%)
P-value	< 1		< .0001	

Abbreviation: VW, ventral width; IP, interpupillary; DC, Distance.

Postoperative measurement of the ventral width in group I 95.7% become ≤30% of there interpupillary distance, where

in group II only 52.9%, with a statistically significant (P<.0001).



Fig 2: A) Preoperative, B) postoperative

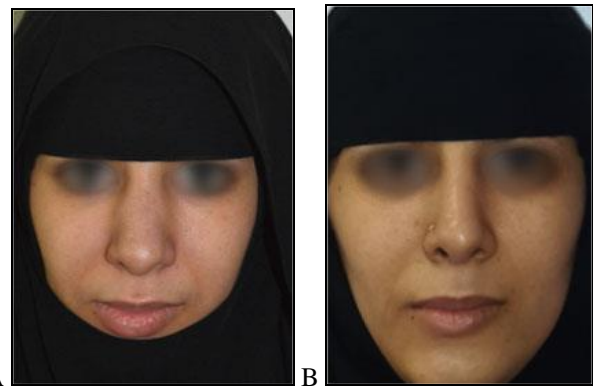

Fig 3: A) Preoperative, B) postoperative

Low-to-high osteotomy. Low-to-Low osteotomy.

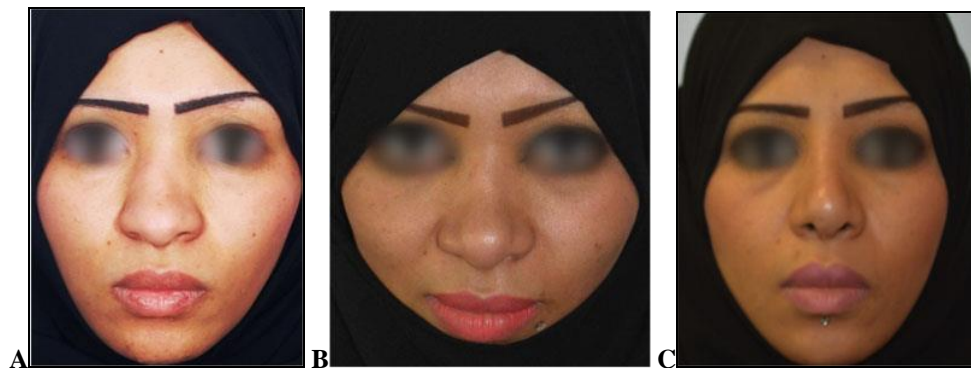


Fig 4: A) Preoperative. B) After primary surgery Low-to-high osteotomy. C) After revision surgery, Low-to-low osteotomy.

Ventral width than the low-to-high postoperatively. Additionally, the patient's satisfaction for functionality was the same, which indicated that both techniques were effective in meeting the functional requirements.

In the last few years, surgeons who perform rhinoplasty have observed that patients are showing more interest in the aesthetic aspects of the surgery, and many are asking for a narrower nose [9]. Our results found that patient satisfaction of aesthetics was higher in low-to-low cases, which resulted in a narrower nose.

Pre and postoperative photographs were taken of our patients who underwent lateral nasal osteotomy via one of the two techniques. Figures 2 show the low-to-high lateral osteotomy and figures 3 shows the low-to-low lateral nasal osteotomy. As shown in the figures, there is obvious narrowing in the ventral width on the low-to-low versus the low-to-high technique. Figures 4 show a patient who underwent primary rhinoplasty with a low-to-high lateral osteotomy, followed by a revision rhinoplasty with the low-to-low technique.

Conclusion

When comparing the two techniques of lateral osteotomy, the ventral width narrowed and patient satisfaction with the aesthetic increased after the low-to-low technique. Nevertheless, there was no difference in satisfaction with the resulting function. The low-to-low lateral osteotomy prevailed over the low-to-high, especially for nasal deformities that had a wide ventral width.

References

1. Ghassemi Alireza, Ayoub Ashraf, Modabber Ali, Bohluhi Behnam, Prescher Andreas *et al.* Lateral nasal osteotomy: a comparative study between the use of osteotome and a diamond surgical burr-a cadaver study. *Head & face medicine.* 2013; 9(1):41.
2. Tasman Abel-Jan. Rhinoplasty-indications and techniques. *GMS current topics in otorhinolaryngology, head and neck surgery,* 2007, 6.
3. Pousti Seyed Behzad, Touisserkani Sam, Jalessi Maryam, Kamrava, Seyed Kamran, Sadigh, Nader *et al.* Does cosmetic rhinoplasty affect nose function? *ISRN otolaryngology,* 2011.
4. Sinha Vikas, Gupta Devang, More Yogesh, Prajapati Bela, Kedia BK, Singh *et al.* External vs. internal osteotomy in rhinoplasty. *Indian Journal of Otolaryngology and Head & Neck Surgery.* 2007; 59(1):9-12.
5. Palma P, Khodaei I, Bertossi D, Vasilenko I, Alqahtani A, Shawkat S. Hybrid rhinoplasty: beyond the dichotomy of rhinoplasty techniques. *Acta Otorhinolaryngologica Italica.* 2013; 33(3):154.
6. Zoumalan Richard A, Shah Anil R, Constantinides Minas. Quantitative comparison between microperforating osteotomies and continuous lateral osteotomies in rhinoplasty. *Archives of facial plastic surgery.* 2010; 12(2):92-96.
7. Byrne Patrick J, Walsh William E, Hilger Peter A. The use of inside-out lateral osteotomies to improve outcome

- in rhinoplasty. Archives of facial plastic surgery. 2003; 5(3):251-255.
8. Azizzadeh Babak, Mashkevich Grigoriy. Middle Eastern rhinoplasty. Facial plastic surgery clinics of North America. 2010; 18(1):201-206.
 9. Pizzamiglio Diego Sherlon, Berger Cezar Augusto Sarraf. Comparative study of continuous lateral osteotomy and microperforating osteotomy in patients undergoing primary rhinoplasty. International archives of otorhinolaryngology. 2012; 16(3):382-386.