



Large hepatic hydatid cyst as a cause of pyloric and duodenal obstruction: Case report

Hamad Abdullah Almadi¹, Saeed Hofan Algarni², Tariq Abdulrahman Al thobaiti³, Abdullah Mohammed Kamel⁴, Mishal Mohsen Alhazmi⁵, Hasna Wafi Algarni⁶

^{1,2} MD, pediatric emergency consultant, Department of Pediatric Emergency, King Saud Medical City, Riyadh, KSA, Saudi Arabia

³ MD, pediatric emergency consultant, Department of Pediatric Emergency, King Khaled University Hospital, Riyadh, KSA, Saudi Arabia

⁴ MD, pediatric emergency fellow, Department of Pediatric Emergency, King Khaled University Hospital, Riyadh, KSA, Saudi Arabia

⁵ MD, pediatric emergency fellow, Department of Pediatric Emergency, National Guard Hospital, Riyadh, KSA, Saudi Arabia

⁶ MD, pediatric emergency fellow, Department of Pediatric Emergency, King Faisal Specialist Hospital, Riyadh, KSA, Saudi Arabia

Abstract

Six years old Saudi girl known case of leukodystrophy and seizure disorder she was presented to pediatric emergency department complaining of: Frequent vomiting started one day before presentation Associated with abdominal distention started suddenly as mentioned by the mother. Abdomen Ultrasound was done in Emergency Room by Pediatric Emergency Medicine fellow, upon examination huge hepatic cyst was found, with small bowel obstruction, According to the clinical history and the image findings, a hydatid cyst was suspected after that she was referred to pediatric surgery and pediatric infectious disease for further treatment. Hydatid cyst is uncommon in Saudi Arabia; it might be asymptomatic or may lead to fatal complications. The optimal treatment is considered to be surgery with the potential of removing the cyst and leading to complete cure. Making preoperative diagnosis based on the typical image findings is most important, so surgeons can take particular precaution not to rupture the lesion.

Keywords: hydatid cyst, pyloric obstruction, duodenal obstruction

Introduction

Hydatid disease (Echinococcosis) is a zoonotic infection of humans caused by *Echinococcus granulosus*, it may be asymptomatic or may lead to fatal complications. The disease has a worldwide distribution; particularly among populations accustomed with sheep husbandry ^[1]. In Middle Eastern countries including Kingdom of Saudi Arabia (KSA) the disease has a higher occurrence than in the west, which could be attributed to the presence of sheep living in close contact with humans, especially among the Bedouins ^[2]. it is Extremely rare to find patients with symptomatic hydatid disease of the liver presenting with very large cysts that cause compression of the adjacent organs such as in our case with bowel obstruction, Reports of the disease in KSA are limited and have shown multi-organ involvement ^[3], most of these published reports address clinical or management experiences, most of which are comparable in many instances. In a 5-year experience case report examining 117 patients with hydatid cyst only 6 had a bowel obstruction complication ^[1].

Case report

Six years old Saudi girl known case of leukodystrophy and seizure disorder was brought to Emergency room. History was taken from the mother and she is reliable. She was presented to pediatric emergency department complaining of: Frequent

vomiting started one day before presentation, which was greenish in color, moderate in amount, with each feed. Associated with abdominal distention started suddenly as mentioned by the mother. There is history of watery diarrhea small in amount 3 times per day with no blood, weight loss and abdominal pain. There's no history of fever, No jaundice. No change of appetite. Systemic review was unremarkable Upon Clinical Examination patient Looks in pain, not jaundiced, moderately dehydrated. Vital signs show: Temperature=37.8, Pulse=137, Respiratory Rate=24, Blood pressure=102/92. The data of routine CBC and serum biochemistry profile were unremarkable, with slight elevation in WBC=17/L and Neutro=13/L and slight decline in HGB=9/L. AST an ALT levels were both high. Abdominal examination shows distended, soft abdomen, hepatomegaly 4CM below costal margin.

Abdominal Ultrasound was performed in Emergency Room by Pediatric Emergency Medicine fellow, which showed a huge well-defined stated cystic lesion with internal debris (Figure 1), dilated small bowel loop (diameter 4 cm) and decreased bowel peristalsis, while the liver was seen partially (Figure 2). Other oval shaped fluid level thick competent containing well-defined lesions seen in the mid and left abdomen. Spleen and pancreas were not visualized while both kidneys were normal in size with no hydronephrosis.

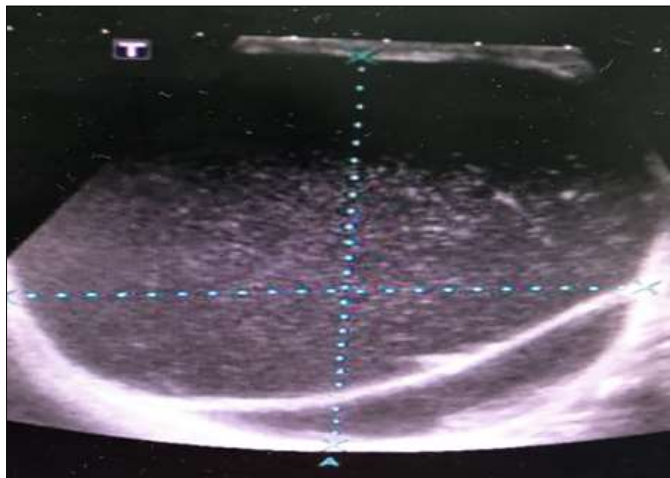


Fig 1

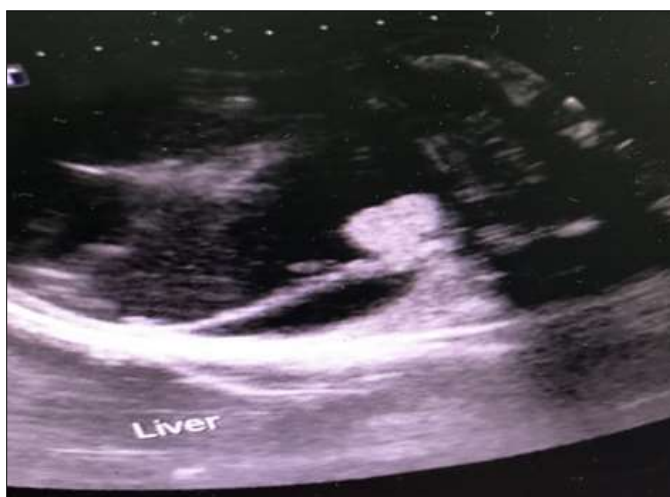

Fig 2

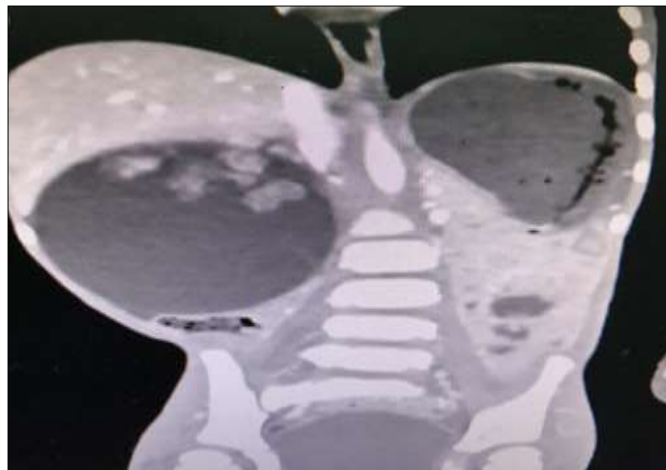

Fig 3

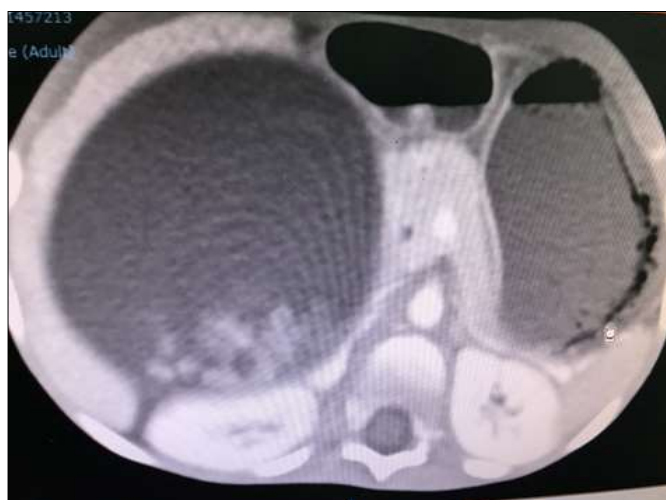

Fig 4

According to the clinical history and the image findings, a hydatid cyst was suspected and Further investigation with CT was demonstrated to confirm the result findings showed In comparison with abdominal ultrasound once again there is large hepatic (Hydatid) cyst lesion mainly low attenuation fluid components with internal septation and small marginal cysts and detached, laminated membrane inside it, which appears to float within the contents of the cyst (Figure 3 and 4). The cyst measures 10.0 X 10.1 X 9.0 cm in the right lobe of the liver (segment 5). Distended abdomen noted could be due to compression over the pyloric and duodenal causing like partial gastric obstruction. Displacement and compression of the stomach superior anteriorly and the celiac trunk, gastric and splenic arteries to the left and pushed the right kidney posteromedial as well as the adjacent small and large bowel loops. There is thin rim wall enhancement of the cystic and internal detached cystic lesions. There is surrounding retroperitoneal fat stranding. There is free intra peritoneal fluid small amount in the upper abdomen and moderate in the pelvis. The pancreas, gallbladder, spleen, both kidneys and both adrenal glands are homogenously enhanced and unremarkable. No focal mass lesions seen, No pneumoperitoneum seen, no major vascular abnormality seen.

Management of the case was to keep patient NPO, Start on Intravenous fluid, Start albendazole 15 mg/ kg/ d divided twice daily, After that she was referred to pediatric surgery to be treated surgically and pediatric infectious disease for further treatment. Patient was given follow up in OPD every 6 months after surgery.

Discussion

Hydatid cyst could be asymptomatic for many years, and it might be detected when there is a feeling of abdominal distension a worldwide distribution; particularly among populations accustomed with sheep husbandry [1]. In Middle Eastern countries including Kingdom of Saudi Arabia (KSA) the disease has a higher occurrence than in the west, which could be attributed to the presence of sheep living in close contact with humans, especially among the Bedouins [2]. Echinococcus infections have two types, Echinococcus multicularis (*E. multicularis*) which is less common but more invasive imitating a malignancy and Echinococcus granulosus (*E. granulosus*) which is the most common cause of hydatid cyst in humans, Moreover, hydatid cyst can be solitary or multiple [4, 5].

Hydatid cyst could be asymptomatic for many years, and it

might be detected when there is a feeling of abdominal distension, hepatomegaly or upon liver imaging for any other medical condition. In other cases hydatid cyst could be painful or it can lead to complications such as rupture into the peritoneal cavity or into the biliary tract causing the patient to experience cholangitis or anaphylactic shock ^[6].

It is Extremely rare to find patients with symptomatic hydatid disease of the liver presenting with very large cysts that cause compression of the adjacent organs such as in our case with bowel obstruction, Reports of the disease in KSA are limited and have shown multi-organ involvement ^[3], most of these published reports address clinical or management experiences, most of which are comparable in many instances. In a 5-year experience case report examining 117 patients with hydatid cyst only 6 had a bowel obstruction complication.

Imaging findings depend on the stage of cyst growth. Most laboratory examinations results are usually normal and the diagnosis can be confirmed by imaging combined with serological tests, but serological test was not available in our case. As in our case, abdominal ultrasound showed huge well-defined stated cystic lesion with internal debris and dilated small bowel loop (diameter 4 cm) with decreased bowel peristalsis, other oval shaped fluid level thick competent containing well-defined lesions seen in the mid and left abdomen. The appearance of hydatid cyst in CT showed In comparison with abdominal ultrasound once again there is large hepatic (Hydatid) cyst lesion mainly low attenuation fluid components with internal septation and small marginal cysts and detached, laminated membrane inside it, which appears to float within the contents of the cyst. The cyst measures 10.0 X 10.1 X 9.0 cm in the right lobe of the liver (segment 5). Distended abdomen noted could be due to compression over the pyloric and duodenal causing like partial gastric obstruction. Management of the case was to keep patient NPO, Start on Intravenous fluid, Start albendazole 15 mg/ kg/ d divided twice daily, After that she was referred to pediatric surgery to be treated surgically and pediatric infectious disease for further treatment. Patient was given follow up in OPD every 6 months after surgery. Hydatid cyst treatment present a therapeutic challenge and medical treatment with mebendazole or albendazole has been reported, but the results of medical therapy alone remain controversial.⁷ It has been used in the prevention of postoperative local recurrence and sterilization before surgery ^[8].

The optimal treatment of hydatid cyst is surgery with the potential of removing the cyst with complete cure ^[9], primarily focusing on eradicating the parasite, preventing intraoperative spillage of contents and obliterate the residual cavity. Possible reoccurrence of cyst may occur either from spillage of hydatid fluid during the operation or from further reinfestation of the patient ^[10].

Funding: None

Conflict of interest: None declared

References

1. WHO/FAO/UNEP. Guidelines for surveillance, prevention and control of echinococcosis / hydatidosis. Document No. VPH/81.28. Geneva: World Health Organization, 1981.

2. Malaika SS, Attayeb A, Sulaimani S, Reddy JJ. Human echinococcosis in Saudi Arabia. *Saudi Med J.* 1981; 2:77.
3. Noah MS, El Din Hawas N, Joharjy I, Abdel Hafez M. Primary cardiac echinococcosis: report of two cases with review of the literature. *Ann Trop Med Parasitol.* 1988; 82:67-72.
4. Kumar MJ, Toe K, Banerjee RD. Hydatid cyst of liver. *Postgrad Med J.* 2003; 79:113-114.
5. Polat P, Kantarci M, Alper F, Suma S, Koruyucu MB, Okur A. Hydatid disease from head to toe. *Radiographics* 2003; 23: 475-494
6. Lygidakis NJ. Diagnosis and treatment of intrabiliary rupture of hydatid cyst of the liver. *Arch Surg.* 1983; 118:1186-1189.
7. Todorov T, Vutova K, Mechkov G, Petkov D, Nedelkov G, Tonchev Z. Evaluation of response to chemotherapy of human cystic echinococcosis. *Br J Radiol.* 1990; 63:523-531.
8. Topcu S, Kurul IC, Tastepi I, Bozkurt D, Gulhan E, Cetin G. Surgical treatment of pulmonary hydatid cysts in children. *J Thorac Cardiovasc Surg.* 2000; 120:1097-1101.
9. WHO Guidelines for treatment of cystic and alveolar echinococcosis in humans. WHO Informal Working Group on Echinococcosis. *Bull World Health Organ.* 1996; 74:231-242.
10. Ustunsoz B, Akhan O, Kamiloglu MA, Somuncu I, Ugurel MS, Cetiner S. Percutaneous treatment of hydatid cysts of the liver: long-term results. *AJR Am J Roentgenol.* 1999; 172:91-96.